

Split tibialis posterior tendon transfer for correction of spastic equinovarus hindfoot deformity

Maria VLACHOU, Alex BERIS, Dimitris DIMITRIADIS.

From Pendeli Children's Hospital, Athens, Greece

Equinovarus hindfoot deformity is one of the most common deformities in children with spastic paralysis; it is usually secondary to cerebral palsy. Split tibialis posterior tendon transfer is performed to balance the flexible spastic varus foot and is preferable to tibialis posterior lengthening, as the muscle does not lose its power and therefore the possibility of a valgus or calcaneovalgus deformity is diminished. We retrospectively evaluated 33 consecutive ambulant patients (38 feet) with flexible spastic varus hindfoot deformity. Twenty-eight presented unilateral and five bilateral involvement. The mean age at operation was 10.8 yrs (range 6-17) and the mean follow-up was 10; yrs (4-14). There were 20 hemiplegic feet, 11 diplegic and 7 quadriplegic. Eighteen feet also presented an equinus position of the hindfoot, requiring Achilles tendon lengthening. The surgical technique applied was similar to the one described by Green *et al*, with four skin incisions, two on either side of the foot and ankle. The evaluation of the results was carried out using Kling and Kaufer's clinical criteria. Results were graded excellent or good for 34 out of 38 feet (89.5%). Twenty feet were graded excellent, indicating that the children managed to walk with a plantigrade foot without fixed or postural deformity and did not have callosities. Fourteen feet were graded good in children who walked with less than 5° varus, valgus or equinus of the hindfoot and had no callosities. Four were graded poor, with recurrent equinovarus deformity. The feet with poor results presented a residual varus deformity due to intraoperative technical errors.

Keywords : equinovarus foot deformity ; spastic paralysis ; split posterior tibialis transfer.

INTRODUCTION

Overactivity of the tibialis posterior causes varus deformity of the hindfoot, lateral instability in stance and foot strike on the lateral border of the foot, thereby creating painful callosities on the lateral border, which contribute to difficulty in walking. Many different surgical procedures with or without concomitant lengthening of the triceps surae have been advocated to correct the deformity. Lengthening of the Achilles tendon is the standard treatment for the equinus component of the deformity, but it does not correct the varus hindfoot deformity. Several authors proposed in the past a tenotomy of the posterior tibial tendon at its insertion onto the navicular bone, which led to late collapse of the navicular joint and valgus deformity of the hindfoot (2,5,7,10). Intramuscular lengthening of the posterior tibial tendon was proposed by Majestro *et al* (14), with good results when patients

-
- Maria Vlachou, MD, Paediatric Orthopaedic Surgeon.
 - Alex Beris, MD, Professor in Orthopaedics and Trauma Surgery.
 - Dimitris Dimitriadis, MD, Paediatric Orthopaedic Chief Surgeon of the Department.
Pendeli Children's Hospital, Department of Paediatric Orthopaedics, Athens, Greece.
- Correspondence : Maria Vlachou MD, 64 Kavatha street, Goudi 15773, Athen, Greece.
E-mail : vlahma@yahoo.com
© 2010, Acta Orthopædica Belgica.
-

were younger than 6 years, and only 2 of the 28 spastic equinovarus feet presenting recurrence. Banks (2) reported excellent or good results in 83% of patients after Z-lengthening. Anterior transfer of the posterior tibial tendon through the interosseous membrane to the dorsum of the foot converts the tendon to an ankle dorsiflexor with unacceptably high percentage of poor results attributable to either calcaneal deformity or overcorrection (21,23), in other studies, however, good or satisfactory results have been reported in 29% to 100% of patients (17,24). Rerouting or anterior transposition by removing the tendon from its sheath and rerouting it anteriorly to the medial malleolus has also been reported with good results in all 34 feet (1). Bisla *et al* (4) reported improvement in only 20% of feet after rerouting of the tendon and noted that complete correction either of varus or equinus deformity is difficult to achieve. Split posterior tibial tendon transfer was first described by Kaufer (11) and was popularized by Green *et al* (9) and Kling *et al* (12), as a technique that balances the hind part of the foot and maintains the plantar flexion power. According to these authors, it should be applied only in patients from 4 to 6 years of age due to the potential risk of converting the foot to a valgus deformity in children younger than 4 years of age. A prerequisite for a split posterior tibial tendon transfer is the ability to walk. Contraindications include a fixed bony deformity, co-spasticity of the tibialis anterior tendon, and a contracted tibialis posterior or Achilles tendon.

MATERIALS AND METHODS

Written parental permission was obtained to use information held in the hospital records to be used in this review, as an Institutional Review Board (IRB) does not exist in our country. Between 2002-2006, 68 children with CP and varus hindfoot deformity were treated with a split posterior tendon transfer in our department. Eighteen patients did not meet the inclusion criteria and were excluded. Of the fifty remaining patients, ten failed to return and seven could not be contacted, so that 33 patients were finally available for follow-up. Our inclusion criteria were: 1. ambulant patients with cerebral

palsy, 2. age no less than 6 years at the time of operation, 3. varus deformity of the hindfoot during gait (stance and swing phase), 4. flexible varus hindfoot deformity, 5. follow-up at least 4 years.

We retrospectively evaluated 38 feet (24 right/14 left) in 33 ambulant patients, 23 females and 10 males, with flexible spastic varus hindfoot deformity. Twenty-eight patients presented a unilateral and 5 a bilateral involvement. The mean age at the time of operation was 10.8 years (range 6-17) and the mean follow-up was 10 years (range 4-14). There were 20 feet in hemiplegic patients, 11 feet in diplegic patients and 7 feet in quadriplegic patients. We used the technique of Green *et al* (9), with four incisions in all cases. Eighteen feet also presented an equinus hindfoot deformity, requiring simultaneous Achilles tendon lengthening.

There were 23 feet presenting with a concomitant cavus foot component that underwent supplementary operations performed at the same time as the index operation. Plantar soft tissue release was performed in 15 feet, a Jones procedure was performed in 5 feet, a transfer of the long extensor tendons to the metatarsals in 2 feet, and finally transcutaneous flexor tenotomies in 23 feet (table I).

Clinical evaluation was based on the inspection of the patients while standing and walking, on the range of motion of the foot and ankle, on callus formation and on the foot appearance using the clinical criteria of Kling *et al* (12). Results are graded excellent when the child manages to walk with a plantigrade foot, without fixed or postural deformity, in a regular shoe and has no callosities: patients and parents are pleased with the result and no brace is required post-operatively. Results are graded good in children who walk with less than 5° varus, valgus, or equinus of the hindfoot, wear regular shoes, with no callosities and are satisfied with the outcome. Feet with recurrent equinovarus deformity, or overcorrected into a valgus or calcaneovalgus deformity are considered as poor results.

The talo-first metatarsal angle, between the axis of the talar neck and the axis of the first metatarsal, was measured on anteroposterior and lateral weight-bearing radiographs. The angle is considered positive when the first metatarsal is abducted relatively to the axis of the talus and negative when

Table I.
Supplementary operations performed concomitantly and after the index operation.

<i>Supplementary operations</i>	Feet (No)
Transcutaneous flexor tenotomies	23
Achilles cord lengthenings	18
Plantar soft tissue releases	15
Jones	5
Extensor tendons transfer to the metatarsals	2
<i>After index operation</i>	
Calcaneocuboid fusion (Evans)	4

the first metatarsal is adducted. The position of the hindfoot was evaluated according to the criteria of Chang *et al* (6) : severe varus was defined when the hind foot was in >10° varus and additional operations were required ; mild varus was defined when the hind foot was in 5° to 10° of varus and no additional operations were required ; neutral position was defined when the hind foot was in neutral position or in less than 5° of varus or valgus. Mild valgus was defined when the hind foot was in 5° to 10° of valgus with no additional operations required and severe valgus when the hind foot was in more than 10° of valgus and additional operations were required.

RESULTS

Twenty feet were graded excellent, 14 good and 4 poor (table II). None of the feet presented mild or severe valgus postoperatively, while the 4 feet which were graded as poor presented a severe varus deformity and underwent a calcaneocuboid fusion 16 and 18 months respectively after the index operation.

On the anteroposterior and lateral weight-bearing radiographs, the feet with severe varus had a negative talo-first metatarsal angle (mean : -26.8° ± 18.4°), those with mild varus had a mean of -14.5° ± 12.2°. In feet with the hindfoot in neutral position the mean value was 5.0° ± 7.4°. The results in hemiplegic patients were better and significantly different than in the diplegic and quadriplegic ones (chi-square, p = 0.005).

Table II. — Results.
Number in parentheses is the total number of feet with the percentage of the results according to the involvement.

	Excellent (20)	Good (14)	Poor (4)
Hemiplegia (20)	18 (90%)	2 (10%)	-
Diplegia (11)	2 (18.1%)	9 (81.8%)	-
Quadriplegia (7)	-	3 (42.8%)	4 (57.1%)

All patients with an excellent result were brace free at the last follow-up, with significant improvement in gait and were able to walk with plantigrade feet, using regular shoes. Parents were also satisfied with the outcome. The patients with good results continued to use a night brace (AFO). All of them had good correction of the hind foot equinus and the ankle was able to dorsiflex to at least 90°. The patients presenting a poor result required continued bracing because of the severe residual varus deformity, with excessive weight bearing on the lateral border of the foot and painful callosities. These patients required further foot realignment.

DISCUSSION

All reports regarding split posterior tendon transfer have shown favourable results (9,10,12,15,19,22) comparable to our study. One of the prerequisites for split tibialis posterior tendon transfer was the ability of the patients to walk, as it is unnecessary to restore the muscle balance of feet in non-ambulant patients. In these cases, the deformity can be corrected in a later stage by performing bone surgery. Although gait analysis has been recommended for pre- and postoperative evaluation, it is not available in every hospital and the action of the tibialis posterior tendon can be evaluated clinically during gait, as it always brings the hindfoot into varus during the entire gait cycle. Co-spasticity of the anterior tibial tendon should be excluded, as it is well documented that the varus deformity of the hindfoot is caused by overactivity of the posterior tibial tendon and weakness or absence of the peroneal muscles (9), whereas varus or supination deformity of the middle part of the foot or the forefoot is caused by overactivity of the anterior tibial tendon. The power of the posterior tibial tendon should be at least 4+

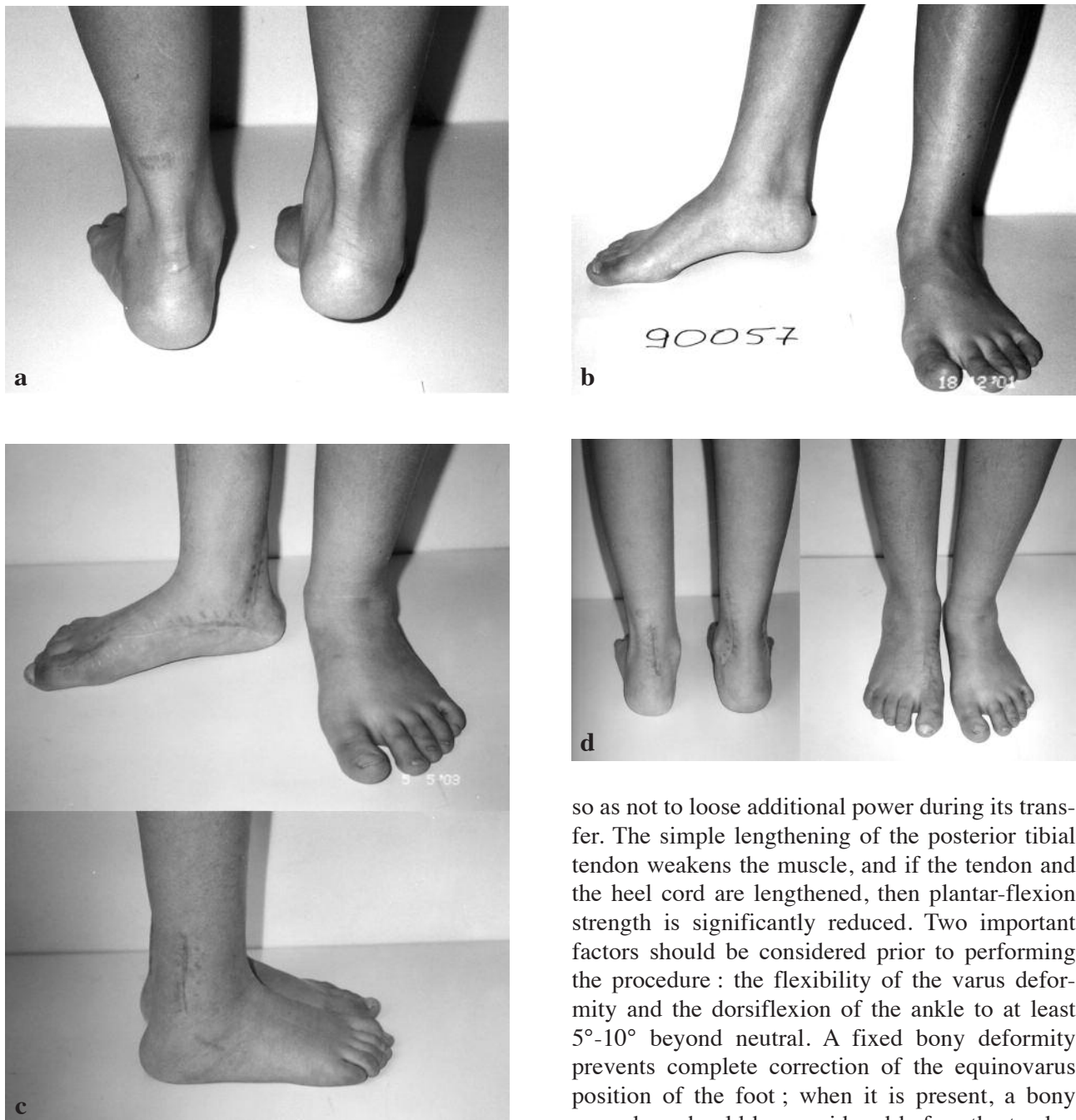


Fig. 1. — (a) 12-year-old female patient with right equinovarus hindfoot deformity in weight bearing position. (b) Lateral view of the same foot with mild cavus component. (c) Postoperative lateral views of the patient after plantar soft tissue release, Achilles lengthening and split posterior tibial tendon transfer. (d) Postoperative anterior and posterior views of the same patient after six years follow-up.

so as not to lose additional power during its transfer. The simple lengthening of the posterior tibial tendon weakens the muscle, and if the tendon and the heel cord are lengthened, then plantar-flexion strength is significantly reduced. Two important factors should be considered prior to performing the procedure: the flexibility of the varus deformity and the dorsiflexion of the ankle to at least 5° - 10° beyond neutral. A fixed bony deformity prevents complete correction of the equinovarus position of the foot; when it is present, a bony procedure should be considered before the tendon transfer, to prevent persistent varus. All patients with a fixed deformity requiring bony procedures were excluded. Twenty-seven out of thirty-eight feet in our series presented a concomitant cavus foot component and underwent supplementary operations performed at the same time as the index operation (fig 1a-d).

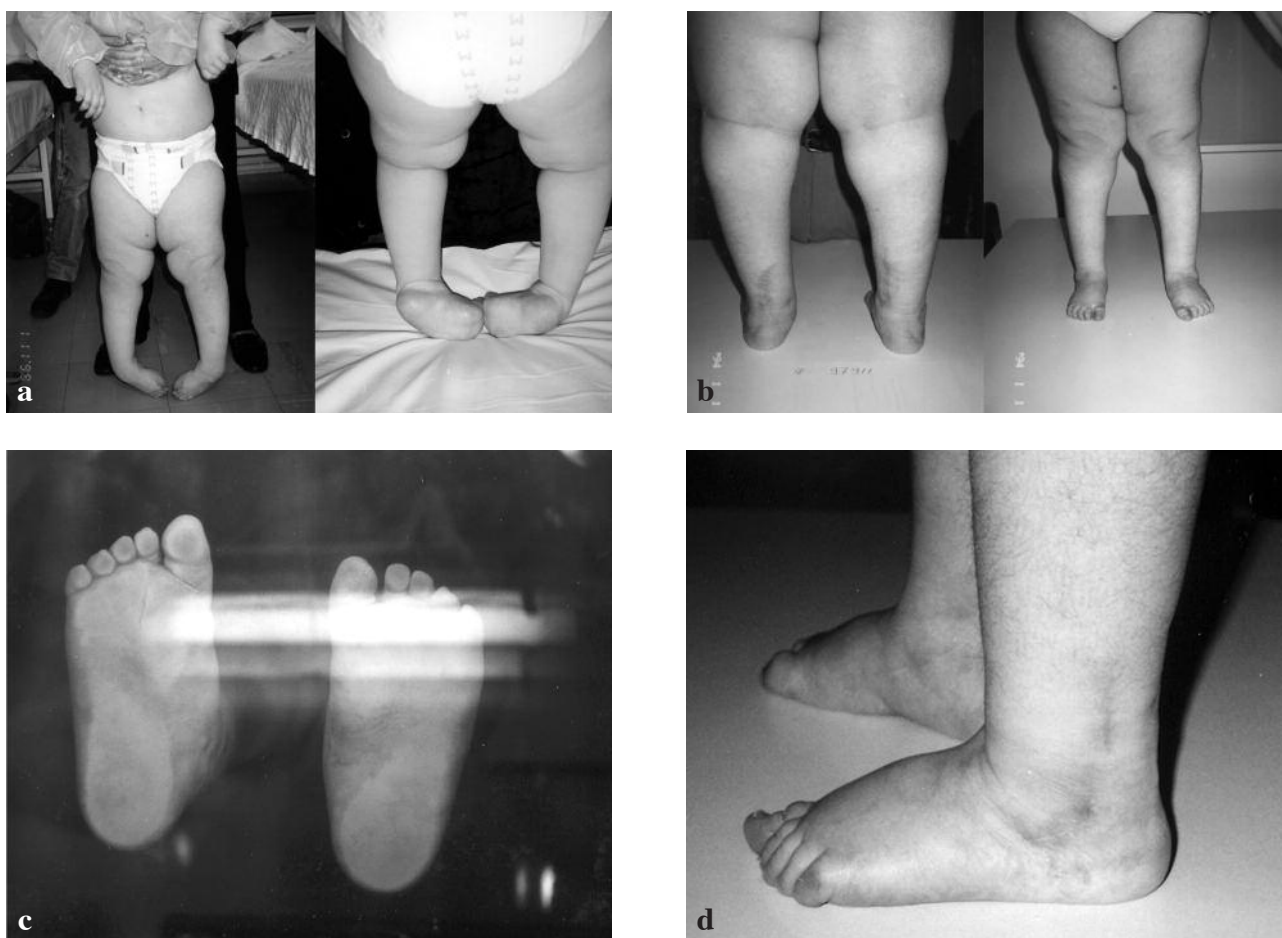

Fig. 2. — (a) Seven-year-old female patient with severe equinovarus hindfoot deformity with inability to stand and walk. (b) Postoperative posterior and anterior views after Achilles lengthening and bilateral split posterior tibial tendon transfer. (c) Final result on the podoscope. (d) Lateral view after 4 years follow-up.

A plantar soft tissue release was the most common procedure, as this release constitutes a keystone procedure for lengthening the shortened base of the foot, and its contribution to the successful outcome for the correction of the cavus component cannot be overemphasized. A concomitant Achilles tendon lengthening was necessary in 18 feet due to the equinus position of the hindfoot (fig 2a-d and table I). The extensor tendons transfer to the metatarsals aimed to improve the metatarsophalangeal dysfunction, to enhance ankle dorsiflexion and, in association with the transcutaneous flexor tenotomies in several toes, to correct the clawing.

We did not observe any overcorrection, which is postoperatively most difficult to treat (8). The poor results were in four feet with severe varus deformity which required a calcaneocuboid fusion.

Whether the posterior tibial tendon transfer is a suitable method of treatment for hindfoot varus in athetoid patients remains controversial. Baker and Hill (1) reported good results. Phelps (16) reported that this technique resulted in an athetoid shift to other muscles and that only bone surgery was suitable. Samilson (20) reported that the results of the procedure in cases of athetosis were unpredictable and very often failed. On the contrary Barnes and

Herring (3) reported one spastic-athetoid patient who underwent a split posterior tibial tendon transfer with a concomitant intramuscular lengthening of the posterior tibial tendon with an excellent result. More recently Kapaya *et al* (10) reported 3 feet with 2 good and 1 excellent result in spastic-athetoid cerebral palsy patients. We excluded all the athetoid patients with equinovarus hindfoot deformity as the deforming forces are too strong to make it possible to balance the hindfoot with a split transfer ; these patients are suitable candidates only for bony procedures.

One of our inclusion criteria was that the age of the patients at the time of surgery should be more than 6 years, as this is an important factor for the final outcome. Ruda and Frost (18) reported after intramuscular posterior tendon lengthening in 29 patients, a varus recurrence in two patients, both less than 6 years of age. Lee and Bleck (13) reported a recurrence of 29% in patients less than 8 years of age at the time of operation, as the spastic muscle tends to retain its contractile properties even if it is weakened or transferred at an age younger than 8 years. The rapid bone growth in children who undergo a split posterior tibial tendon transfer when less than 6 years of age, may lead to recurrence. We selected a follow-up period of more than 4 years as the failure rate increases with time and the final results can be estimated only after skeletal maturity (6). Our results in hemiplegic patients were better and significantly different than in diplegic and quadriplegic patients, indicating that the underlying neurologic impairment affects the results of the surgery. Residual varus deformity in our series was attributed to technical intraoperative errors in balancing the tension between the medial and lateral halves of the tendon. Four feet underwent a bony procedure to correct the hind foot deformity at a later stage. In three feet, some technical difficulty was encountered in suturing the split posterior tibial tendon to the peroneus brevis onto the cuboid, the split half being too short. Although we performed a concomitant intramuscular lengthening of this part of the tendon, to make it long enough for transfer, we do not recommend it, as the tendon loses more of its power.

Based on our experience, we strongly recommend the split posterior tibialis tendon transfer in cerebral palsy children to balance the flexible varus hind foot deformity, especially in hemiplegic patients older than 8 years. We are not convinced that similar good results can be achieved in athetoid patients, as the deforming forces are very strong and it is difficult to balance the hind part of the foot with a split tendon transfer.

One important drawback of our study, however, was the fact that less than 50% of all patients undergoing a split tibialis posterior tendon transfer in the given time period were available for follow-up.

REFERENCES

1. **Baker LD, Hill HM.** Foot alignment in the cerebral palsy patient. *J Bone Joint Surg* 1964 ; 46-A : 1-15.
2. **Banks HH.** The management of spastic deformities of the foot and ankle. *Clin Orthop Relat Res* 1977 ; 122 : 70-76.
3. **Barnes MJ, Herring JA.** Combined split anterior tibial tendon transfer and intramuscular lengthening of the posterior tibial tendon. *J Bone Joint Surg* 1991 ; 73-A : 734-738.
4. **Bisla RS, Louis HJ, Albano P.** Transfer of tibialis posterior tendon in cerebral palsy. *J Bone Joint Surg* 1976 ; 58-A : 497-500.
5. **Bleck EE.** *Orthopaedic Management of Cerebral Palsy.* WB Saunders, Philadelphia, 1979.
6. **Chang CH, Albarracin JP, Lipton GE, Miller F.** Long-term follow-up of surgery for equinovarus foot deformity in children with cerebral palsy. *J Paediatr Orthop* 2002 ; 22 : 792-799.
7. **Duncan WR.** Tonic reflexes of the foot. Their orthopaedic significance in normal children and in children with cerebral palsy. *J Bone Joint Surg* 1960 ; 42-A : 859-868.
8. **Fulford GE.** Surgical management of ankle and foot deformities in cerebral palsy. *Clin Orthop Relat Res* 1990 ; 253 : 55-61.
9. **Green NE, Griffin PP, Shiavi R.** Split posterior tibial tendon in spastic cerebral palsy. *J Bone Joint Surg* 1983 ; 65-A : 748-754.
10. **Kapaya H, Yamada S, Nagasawa T et al.** Split posterior tibial tendon transfer for varus deformity of hindfoot. *Clin Orthop Relat Res* 1996 ; 323 : 254-260.
11. **Kaufner H.** Split tendon transfers. *Orthop Trans* 1977 ; 1 : 191.
12. **Kling TF, Kaufner H, Hensinger RN.** Split posterior tibial tendon transfers in children with cerebral spastic paralysis and equinovarus deformity. *J Bone Joint Surg* 1985 ; 67-A : 186-194.
13. **Lee CL, Bleck EE.** Surgical correction of equinus deformity in cerebral palsy. *Dev Med Child Neurol* 1980 ; 22 : 287-292.

14. **Majestro TC, Ruda R, Frost HM.** Intramuscular lengthening of the posterior tibialis muscle. *Clin Orthop Relat Res* 1971 ; 79 : 59-60.
15. **Medina PA, Karpman RR, Yeung AT.** Split posterior tibial tendon transfer for spastic equinovarus foot deformity. *Foot Ankle* 1989 ; 10 : 65-67.
16. **Phelps WM.** Long-term results of orthopaedic surgery in cerebral palsy. *J Bone Joint Surg* 1957 ; 39-A : 53-59.
17. **Root L, Miller SR, Kirz P.** Posterior tibial tendon transfer in patients with cerebral palsy. *J Bone Joint Surg* 1987 ; 69-A : 1133-1139.
18. **Ruda R, Frost HM.** Cerebral palsy. Spastic varus and forefoot adductus, treated by intramuscular posterior tibial tendon lengthening. *Clin Orthop Relat Res* 1971 ; 79 : 61-70.
19. **Saji MJ, Upadhyay SS, Hsu LCS, Leong JCY.** Split tibialis posterior transfer for equinovarus deformity in cerebral palsy. Long-term results of a new surgical procedure. *J Bone Joint Surg* 1993 ; 75-B : 498-501.
20. **Samilson RL.** Tendon transfers in cerebral palsy. *J Bone Joint Surg* 1976 ; 58-B : 153-154.
21. **Schneider M, Balon K.** Deformity of the foot following anterior transfer of the posterior tibial tendon and lengthening of the Achilles tendon for spastic equinovarus. *Clin Orthop Relat Res* 1977 ; 125 : 113-118.
22. **Synder M, Kumar SJ, Stecyk MD.** Split tibialis posterior tendon transfer and tendo Achillis lengthening for spastic equinovarus feet. *J Paediatr Orthop* 1993 ; 13 : 20-23.
23. **Turner JW, Cooper RR.** Anterior transfer of the tibialis posterior through the interosseous membrane. *Clin Orthop Relat Res* 1972 ; 83 : 241-244.
24. **Van der Werf GJIM, Tonino AJ.** Transportation of the posterior tibial tendon in spastic equinovarus. *Arch Orthop Trauma Surg* 1984 ; 103 : 128-130.