



Modular proximal femoral replacement in salvage hip surgery for non-neoplastic conditions

Mathew D SEWELL, Sammy A. HANNA, Richard W. CARRINGTON, Robin C. Pollock, John A. SKINNER, Stephen R. CANNON, Timothy W.R. BRIGGS

From the Royal National Orthopaedic Hospital, Stanmore, United Kingdom

Addressing severe proximal femoral bone loss in revision hip surgery is a challenging reconstructive problem. The use of modular proximal femoral megaprotheses is one of many available options to address this. This is a retrospective review of 15 patients who had undergone limb salvage at our institution using a modular proximal femoral replacement. There were 8 males and 7 females with a mean age of 67 years (34 to 85) and a mean follow-up of 60 months (1 to 99). Indications included re-implantation for deep infection in nine patients, aseptic loosening in three, peri-prosthetic fracture in two and painful excision arthroplasty in one. Mean Harris hip score increased from 28 (13 to 49) pre-operatively to 69 (39 to 85) at final follow-up (paired t-test, $p < 0.0001$) and mean Toronto Extremity Salvage score increased from 26% (14 to 40) to 71% (35 to 82) (paired t-test, $p < 0.0001$). Prosthesis survival with revision as the endpoint was 87% at 5 years. There were two dislocations (14%) and there was failure to eradicate deep infection in two. Modular proximal femoral replacement provided good function and versatility with an acceptable complication rate for patients with severe proximal femoral bone loss with or without infection.

Key words: proximal femoral replacement ; modular ; bone loss ; infection ; loosening.

INTRODUCTION

Addressing loss of proximal femoral bone around a failed total hip replacement (THR) is a

challenging reconstructive problem. Femoral bone stock deficiency may result from a variety of factors which include infection, peri-prosthetic fracture, osteolysis from wear debris accumulation, stress shielding and multiple previous revisions (3,4,14,6,30). Surgical options to address this problem include resection arthroplasty (6), long-stemmed implants with or without impaction allografting (5,12), allograft-prosthetic composites (2,17) or customised and modular proximal femoral endoprotheses (21,23,27,28,32). Resection arthroplasty results in a

- Mathew D. Sewell MRCS, Specialist Orthopaedic Registrar
- Sammy A. Hanna MRCS, Specialist Orthopaedic Registrar
- Richard W. Carrington FRCS (Orth), Consultant Orthopaedic Surgeon.
- Robin C. Pollock FRCS (Orth), Consultant Orthopaedic Surgeon.
- John A. Skinner FRCS (Orth), Consultant Orthopaedic Surgeon.
- Stephen R. Cannon MCh (Orth), FRCS, Consultant Orthopaedic Surgeon.
- Timothy W. R. Briggs MD (Res), MCh (Orth), FRCS, Professor of Orthopaedic Surgery.

Royal National Orthopaedic Hospital, Stanmore, UK.

Correspondence : Mr SA Hanna, MRCS, Specialist Registrar in Trauma and Orthopaedic Surgery, London Bone & Soft Tissue Tumour Service, Royal National Orthopaedic Hospital, Brockley Hill, Stanmore, Middlesex, HA7 4LP, UK.

Email : sammyhanna@hotmail.com

© 2010, Acta Orthopædica Belgica.

shortened limb with poor walking ability (22). In patients with severe bone loss (Paprosky grade IIIB and IV femoral defects) (11), long-stemmed cemented or press-fit implants may not be suitable due to lack of adequate distal fixation. In these patients allograft-prosthetic composites or endoprostheses may be used.

Endoprostheses have the advantage of allowing early weight bearing with shorter operative times and do not pose a risk with disease transmission. These factors make them a particularly good option for the elderly patient with medical co-morbidities.

Modular endoprosthetic systems are a relatively new development and have been used in the proximal femur with great success in tumour surgery (7,24). They allow reconstruction of a wide range of skeletal defects without the significant expense or time required to manufacture a custom-made implant and have the advantage of allowing intraoperative flexibility. There are few reports in the literature on the use of modular proximal femoral replacements in non-neoplastic disease (23,28,32)

and their use has not been reported when severe proximal femoral bone loss has been complicated by deep infection.

The aim of this study was to assess the clinical and functional outcome of a modular proximal femoral replacement (PFR) for patients with severe proximal femoral bone loss requiring revision hip surgery, and particularly a sub-group whose previous surgery was complicated by deep infection.

MATERIALS AND METHODS

Between 2001 and 2006, 15 consecutive patients underwent a modular PFR at our institution for non-neoplastic disease. These were identified from our operative records database. Clinical data from medical records, radiological studies and clinic reviews were retrospectively reviewed. Functional scores were obtained through outpatient clinic reviews and patient-filled questionnaires. There were 8 males and 7 females with a mean age of 67 years (34 to 85) at the time of operation. One patient died 15

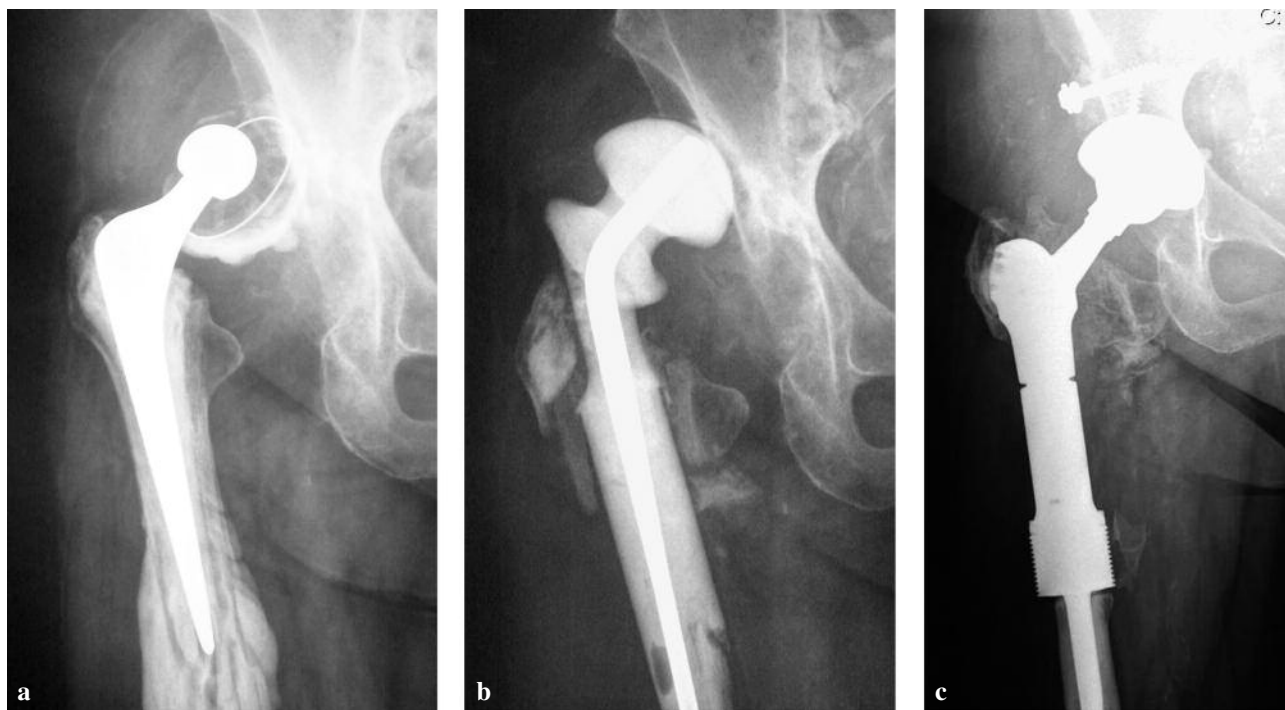


Fig. 1. — Septic loosening of both components of a cemented THR (a) with significant bone loss treated by a two-stage revision (b) with antibiotic cement spacer-G ; (c) Second-stage revision to PFR with uncemented cup. Infection eradicated clinically, biochemically and radiologically at last follow-up with a HHS of 76 and TESS of 74.

days post-operatively from aspiration pneumonia. Overall mean follow-up was 60 months (1 to 99). Patients had undergone a mean of 2.8 (1 to 4) previous operations on the affected hip. For patients who underwent primary THR, mean time between primary THR and index PFR was 14.5 years (range 3.4 to 29.3). The mean duration between the last hip surgery (i.e. THR or fracture fixation) and index PFR was 53 months (6 to 198).

All operations were carried out at a single institution by the five senior authors (RWJC/RP/JAS/SRC and TWRB). Indications for revision included infected THR in six patients (fig 1), aseptic loosening in three, Vancouver type B3 (25) periprosthetic fracture in two, infected non-union of a proximal femoral fracture in one (in a patient who

had previously had multiple previous osteotomies for developmental dysplasia of the hip), re-implantation for previous resection arthroplasty performed for infection in one (fig 2) and infected non-union of an extracapsular femoral neck fracture in two. All patients who required this procedure had Paprosky grade IIIB or IV femoral defects.

The nine patients who had infected prostheses underwent a two-staged revision to modular PFR. The mean duration of infection in THR before index PFR was 36 months (28 to 55). The first stage consisted of removal of prosthesis, radical resection of potentially infected bone, thorough debridement and insertion of antibiotic spacer. The second stage comprised of further debridement and revision hip surgery with a PFR. The second stage was usually

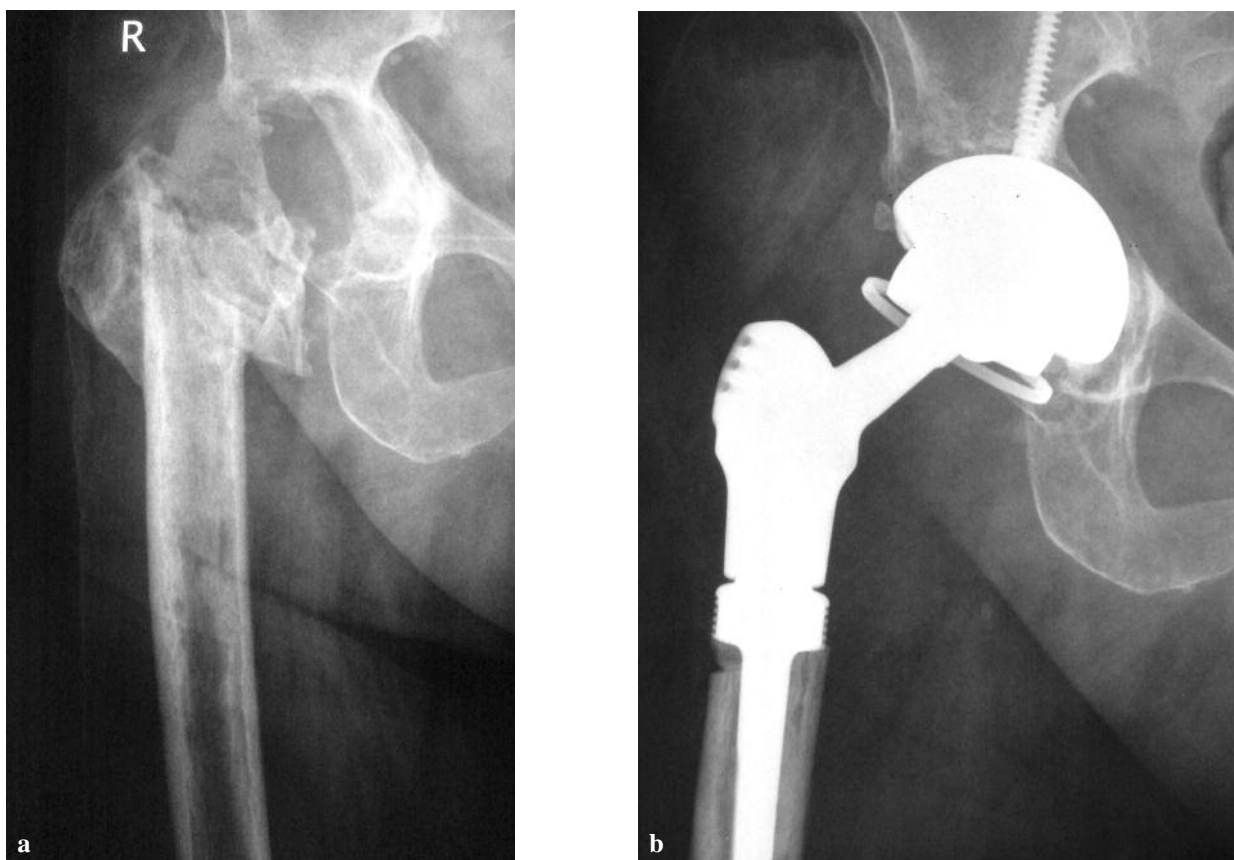


Fig. 2. — Painful excision arthroplasty (a) managed by PFR with uncemented constrained acetabular liner (b). Patient noted a significant improvement in both pain and function with a HHS of 67 and TESS of 72 at final follow-up.

carried out at six weeks after a return to normal of the inflammatory markers with intravenous antibiotics being given in the interim. In three patients the second stage was delayed due to medical comorbidities and raised infectious markers (white cells, C-reactive protein and ESR). The six cases with aseptic indications were subject to single-stage PFR.

Patients were reviewed clinically and radiographically at six weeks, 12 weeks, six months, 12 months and annually thereafter. Functional evaluation using the Harris Hip Score (HHS) (19) and Toronto Extremity Salvage Score (TESS) (9) was performed pre-operatively and at the patient's last follow-up. The TESS is a patient-reported measure of function. The questionnaire is a disease-specific measure designed to assess physical disability for patients after limb-salvage surgery for musculoskeletal tumours. Its lower extremity version consists of 30 questions regarding everyday activities such as dressing, working, mobility and leisure and allows a percentage score to be calculated.

Serial antero-posterior radiographs were independently reviewed by consultant musculoskeletal radiologists to assess femoral defects (pre-PFR), osseointegration and presence of any loosening at the cement-bone interface (post-PFR). The acetabulum was divided into three zones as described by DeLee and Charnley (10). The femoral side was divided into seven zones to assess radiolucent zones and loosening (16).

We used Gross *et al's* criteria (15) to define a successful outcome: increase in the HHS of > 19 points, radiologically stable implant with no requirement for further femoral reconstruction. Statistical analysis was performed using a paired t-test to analyse pre-operative and last follow-up TESS and HHS scores (Stata version 10.1, Stata-Corp, Texas, US). A p-value of < 0.05 was considered significant. Kaplan-Meier survivorship analysis with implant revision as the endpoint was also performed.

The prosthesis

The METS® (Modular Endoprosthesis Tumour System) proximal femoral replacement is a modular

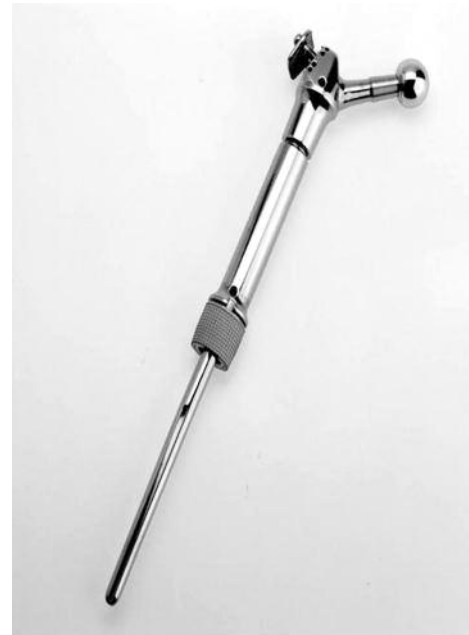

Fig. 3. — The METS® PFR showing the modular head, trochanteric re-attachment plate, shaft, HA-coated collar and cemented stem. (Illustration courtesy of Stanmore Implants Worldwide Ltd)

system made of titanium alloy (Ti 6Al 4V) (Stanmore Implants Worldwide Ltd, Centre for Biomechanical Engineering, Stanmore, UK) (fig 3). The system consists of a variety of different sized and sided trochanters, anatomical in shape with the provision for trochanteric re-attachment, a range of shafts in 15 mm increments to allow for variations in length resection, a range of different diameter collars to match the size of the resected bone and a range of fluted stems for rotational stability which are cemented into the intramedullary canal. There is the option to use a polished or a hydroxyapatite (HA)-coated collar at the bone-prosthesis junction with HA-collar option having the potential for osseointegration. This results in reactive new bone formation that grows proximally from the resection site over the shaft of the implant to form a bony bridge. This is believed to reduce loosening by acting as a 'purse string' that seals the bone-implant interface, preventing the migration of wear particles (21). The HA-collar option was used in all patients in this study. A range of modular metal (cobalt

chromium) and ceramic heads are available. Individual components of the system are connected using interlocking taper junctions. For minimal femoral resections where the smallest shaft may not be suitable, an integral shaft/stem component is available for use.

Surgical Technique

With the patient in the lateral decubitus position, old skin incisions were modified to obtain an extended lateral transfemoral approach (20) to the hip and femur, including an extended trochanteric osteotomy if necessary. Meticulous debridement was performed with removal of all unhealthy tissue, retained cement and metalwork. The acetabulum was inspected and assessed for stability. In all but one case it was removed and, with the exception of one case, an uncemented acetabular shell with the potential for biological fixation was implanted. The femur was divided transversely at the most proximal level of non-infected, intact femoral cortex.

In infected cases an antibiotic loaded spacer was used. This either took the form of a loosely cemented METS® prosthesis covered in antibiotic loaded cement or by using a spacer-G (Tecres SpA, Verona, Italy), where the distal cement had been chipped off the distal end to reveal the screw thread. This was then inserted into a femoral nail to gain additional length and the whole construct covered in antibiotic cement over the desired length prior to re-implantation (fig 1b).

In one stage revision or at second stage, the femoral canal of the distal fragment was reamed aiming to retain as much healthy cancellous bone as possible for optimal cement interdigitation. Where the canal was narrow enough, a cement restrictor was inserted distally to optimise cement pressurisation. After trialling, the appropriate sized METS® femoral components were assembled using pre-operative planning radiographs, leg lengths and stability indicators such as soft tissue tension around the hip as determinants. The femoral stem was then cemented in anatomically appropriate rotation ensuring that the HA-collar was placed directly against diaphyseal bone with no interposing cement. Any remaining proximal femoral bone was

wrapped around the prosthesis and secured with Dall-Miles cables (Stryker, Kalamazoo, Michigan, USA). Whenever possible the greater trochanter with attached abductors was osteotomised and reattached to the endoprosthesis with the trochanteric reattachment plate and screws or cable-grip wires. When the greater trochanter was deficient or absent, the abductor muscles were sutured to tensor fasciae latae using a mass suture technique. The choice of femoral head size depended on the stability of the implant and varied between a 28 mm and 36 mm head. A constrained acetabular liner was required in one patient for intra-operative instability. None of the cases required an allograft. Tissue was sent for histological examination and culture in all cases.

Post-operatively intravenous antibiotics were continued until microbiological results were available. Thromboprophylaxis consisted of foot pumps, thromboembolic deterrent stockings and low molecular weight heparin. Patients were initially placed on 'slings and springs' for two days, then mobilised weight-bearing as tolerated after post-operative radiographs, with an abduction brace if abductor control was poor. At six weeks, once active hip abduction had been achieved and satisfactory radiographs obtained, full weight-bearing was allowed.

RESULTS

One patient died 15 days post surgery from bronchopneumonia, the remaining 14 patients were available for follow-up at a mean time of 64 months (43 to 99) (table I). As defined by Gross *et al* (24), the operation was successful in 12 of 14 patients (86%). Two patients failed to obtain an increase in HHS of > 19. No patients required further femoral reconstruction and all implants were radiologically stable at last follow-up. There have been no cases of aseptic loosening and all patients noted a significant improvement in their pain. Trendelenburg sign was positive in 11 of 14 patients (79%) post-operatively compared with 15 patients (100%) pre-operatively. Mean postoperative knee flexion was 84° (10° to 110°) and mean leg length discrepancy was 1.2 cm (0 to 6).

Mean HHS significantly improved from 28 (13 to 49) pre-operatively to 69 (39 to 85) post-operatively (paired t-test, $p < 0.0001$). Mean TESS increased significantly from 26% (14 to 40) pre-operatively to 71% (35 to 82) post-operatively (paired t-test, $p < 0.0001$). Of the two patients with poor scores, one required an excision arthroplasty for infection and the other had multiple joint pathology which compromised function.

Acetabular components were placed in 15° to 20° of anteversion and 50° or less of inclination. The femoral components were placed in neutral version. Post-operative radiographs confirmed the components to be well fixed and in satisfactory positions in all cases.

No progressive radiolucent lines were noted around any of the acetabular components at any stage of follow-up. One stem (in an infected THR case) showed evidence of progressive loosening at last follow-up, but in view of the absence of new correlating clinical symptoms, no action has been

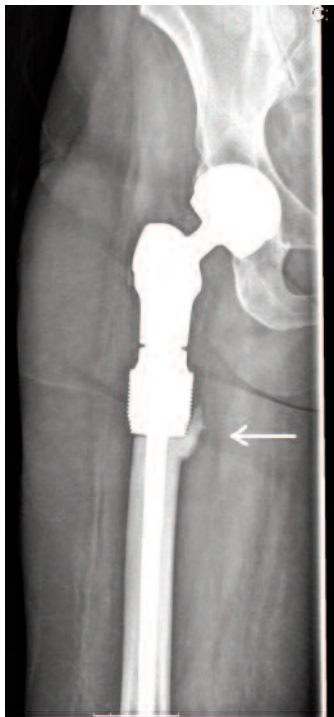


Fig. 4. — Bone ingrowth (white arrow) around the HA-collar forming an extra-cortical bridge, which helps seal the cement-stem interface from wear debris.

taken. Bone ingrowth around the HA-collar was noted in 7 of the 14 patients (fig 4).

Implant survivorship with prosthesis revision as the endpoint was 87% (13 of 15) at five years (fig 5). Dislocation was seen in two patients at a mean time of 3 months (1 to 5). One patient with a 36 mm femoral head dislocated on the first post-operative day. This was managed by open reduction and insertion of a constrained acetabular liner. The patient currently requires one crutch to mobilise. The other patient had a 32 mm femoral head which dislocated at 5 months. This was successfully managed by closed reduction and bracing. This patient was walking unaided at last follow-up.

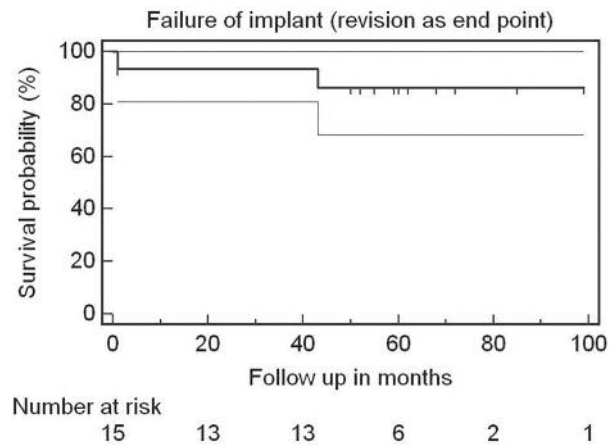


Fig. 5. — Kaplan-Meier survival curve with implant revision as the end-point and 95% confidence intervals.

Cultured organisms from the infected THR's included methicillin-resistant staphylococci, coagulase-negative staphylococci and enterococcus. Deep infection was eradicated in 7 of 9 patients (78%), however there was failure to eradicate deep infection in two. One patient underwent excision arthroplasty at 43 months. This patient noted an improvement in pain but had poor mobility, requiring a frame to mobilise. The other patient was managed by debridement and suppressive oral anti-antibiotic therapy. Both patients reported improved function and pain compared with their pre-operative state at final follow-up.

Table I. — Patient data and outcome for patients managed with a METS® PFR as limb salvage in non-neoplastic disease.

Case/sex/ age (years)	Original pathology *	Indication †	Length of resection (mm)	Acetabulum preparation	Head size (mm)	Follow-up (months)	Complication	Pre-op HHS/ TESS‡	Post-op HHS/ TESS
1/F/78	OA	Infected THR	45	Uncemented	36	99	nil	28/29	76/71
2/F/70	Femoral neck frac- ture	Infected non- union and DHS hardware failure	40	Uncemented	32	43	Deep infection – girdlestone at 43	27/24	39/35
3/M/74	Femoral neck frac- ture	Infected non- union of DHS fracture fixation	50	Uncemented	32	85	Dislocation – closed reduction	24/15	75/82
4/M/53	OA	Infected THR	80	Uncemented	36	72	nil	36/31	71/74
5/M/34	RA	Aseptic loosening	30	Uncemented	32	72	nil	29/20	65/60
6/M/60	OA	Peri-prosthetic fracture	90	Old cemented cup retained	28	68	Superficial wound infection	18/14	85/78
7/F/72	OA	Aseptic loosening and recurrent dis- location	45	Uncemented	32	62	nil	42/38	72/80
8/M/59	OA	Infected THR	90	Uncemented	36	61	dislocation – open reduction and change of liner	49/40	71/79
9/F/79	OA	Peri-prosthetic fracture	55	Uncemented	32	60	nil	13/18	79/76
10/F/85	OA	Painful excision arthroplasty with LLD	65	Uncemented	32	60	nil	22/20	67/72
11/M/87	OA	Aseptic loosening	50	Cemented	32	1	aspiration pneu- monia	20/14	Died
12/F/68	OA	Infected THR	60	Uncemented	32	59	nil	25/32	76/74
13/M/80	Femoral neck frac- ture	Infected THAR	50	Uncemented	36	55	nil	31/30	70/79
14/M/74	OA	Infected THR	55	Uncemented	28	52	Persistence of deep infection – antibiotic sup- pression	26/36	42/60
15/F/49	DDH (mul- tiple sur- geries)	Infected non- union of proximal femoral fracture	50	Uncemented	36	50	nil	31/27	73/68

* OA, osteoarthritis, RA, rheumatoid arthritis, DDH, developmental dysplasia of the hip.

† THR, total hip replacement, DHS, dynamic hip screw, LLD, leg length discrepancy.

‡ HHS, Harris Hip Score, TESS, Toronto Extremity Salvage Score.

DISCUSSION

Managing femoral bone stock deficiency in revision hip surgery can be challenging. Where there is inadequate femoral bone to support a long-stemmed implant, options include excision arthroplasty, endoprosthetic replacement or proximal femoral allograft-prosthesis composite. Excision arthroplasty results in poor function (22) and is often not favoured by the patient especially when previously mobile. Proximal femoral allografting can provide good function (34), however is technically difficult, poses a risk with disease transmission and may be associated with restricted post-operative weight bearing and longer operative times (27). There is also the risk of graft resorption with potential for infection. For these reasons, custom-made or modular endoprostheses may be the preferred option in elderly patients with co-morbidities. In relatively younger patients with Paprosky IIIB and IV defects, we use a custom-made 'internal proximal femoral replacement' prosthesis that allows a proximal wrap of soft tissues and cemented distal fixation (21).

Modular endoprosthetic systems have certain advantages over custom-made prostheses. They are available off-the-shelf at lower cost and allow intra-operative versatility and adjustment to balance resection margins and stability where there is uncertainty. Despite their success in neoplastic disease (7,24), there are few reports for the use of modular PFRs in non-neoplastic conditions (23, 28,32). Parvizi *et al* (28) used a modular megaprosthesis to reconstruct the proximal femur in 43 patients with mean follow-up 36.5 months. They reported a low infection (2%) and relatively high instability (19%) rate with a mean HHS of 65. Most patients were revised for peri-prosthetic fracture and no patient had pre-existing infection. Follow-up was limited and the authors did not comment on the degree of bone loss or the Paprosky grade in their patients.

The main difference between our study and previously reported studies of PFRs in non-neoplastic disease is the high incidence (60% ; 9 of 15 patients) of patients undergoing the procedure for infected hip implants. Management of infected THR's can take many forms including antibiotic

suppression (13), early debridement (8), excision arthroplasty, one-stage revision with antibiotic loaded cement (29) or bone graft (33) and two-stage revision using either cemented or uncemented components (18). The aim is eradication of infection and restoration of function. This may be more difficult in patients with femoral bone stock deficiency due to the extent of potentially infected bone and some authors consider this a contraindication to re-implantation (27,31), such that a three-stage protocol with bone grafting has been proposed (26). There are no reports in the literature on the use of PFRs to eradicate deep infection in the presence of severe proximal femoral bone loss. We adopt a policy of two-stage revision with radical excision of infected bone and meticulous debridement. Following this approach, 7 of 9 (78%) patients had their infection eradicated. This rate is less than after conventional two-stage revision for infection in primary THR (18) but comparable to that after single-stage revision (29). The re-infection rate is also comparable to that when allografts are used (3,26).

Instability is a well-recognised complication for PFRs in both neoplastic (7) and non-neoplastic conditions (23,28,32). Proposed factors that affect dislocation in PFRs include resection of the joint capsule, the extent to which the abductor mechanism is able to be preserved or restored, patient age, head size and use of bipolar head versus THR. The two patients who dislocated in our study had a deficient greater trochanter with no possibility to reconstruct the abductor mechanism to the endoprosthesis. Our observed instability rate (14%) is higher than after conventional revision hip arthroplasty (1), but similar to that seen for allograft-prosthesis composites (17) and other studies of PFRs (32).

The other main concern with PFRs is the risk of aseptic loosening in both the femoral and acetabular components. The low incidence of radiolucency around the acetabular component in this series is related to the press-fit acetabular component used in most cases with the potential for biological fixation. The HA-collar on the femoral side enhances extra-cortical bone integration with the prosthesis, forming an extra-cortical bridge, which seals the implant-cement interface and prevents wear particles from migrating down the bone-cement interface (21).

We have classified the femoral defects as Paprosky grade IIIB and IV to provide clinicians with a guide as to what femoral defects these prostheses may be used in. They can provide good function with a complication rate comparable to that seen with other methods of femoral reconstruction. It is encouraging to note that they may provide a biological method of fixation with osseointegration occurring around the HA-collar. Early results are favourable, although further follow-up is needed to assess long-term survival.

We conclude that attempting limb salvage with modular proximal femoral endoprostheses in non-neoplastic conditions and significant proximal femoral bone loss is a reasonable alternative to excision arthroplasty and other reconstructive methods, especially in elderly patients with multiple comorbidities and patients with infected THR's. These implants are readily available, achieve immediate distal fixation and allow early weight bearing and mobilisation. For patients with severe proximal femoral bone loss complicated by infection, their intra-operative versatility facilitates two-stage revision surgery with reported infection eradication results comparable to those reported with allograft techniques.

Acknowledgements

The authors acknowledge the contribution made by Stanmore Implants Worldwide Ltd, in addition to Timothy Morris from the MRC Clinical Trials Unit, Euston.

REFERENCES

1. **Alberton GM, High WA, Morrey BF.** Dislocation after revision total hip arthroplasty : an analysis of risk factors and treatment options. *J Bone Joint Surg* 2002 ; 84-A : 1788-1792.
2. **Allan DG, Lavoie GJ, McDonald S, Oakeshott R, Gross AE.** Proximal femoral allografts in revision hip arthroplasty. *J Bone Joint Surg* 1991 ; 73-B : 235-240.
3. **Berry DJ, Chandler HP, Reilly DT.** The use of bone allografts in two-stage reconstruction after failure of hip replacements due to infection. *J Bone Joint Surg* 1991 ; 73-A : 1460-1468.
4. **Callaghan JJ, Salvati EA, Pellicci PM, Wilson PD, Ranawat CS.** Result of revision for mechanical failure after cemented total hip replacement, 1979 to 1982. *J Bone Joint Surg* 1985 ; 67-A : 1074-1085.
5. **Chandler HP, Ayres DK, Tan RC, Anderson LC, Varma AK.** Revision total hip replacement using the S-ROM femoral component. *Clin Orthop Relat Res* 1995 ; 319 : 130-140.
6. **Chandler HP, Penenberg BL.** Femoral reconstruction. In : *Bone Stock Deficiency in Total Hip Replacement : Classification and Management.* Slack Inc, Thorofare, NJ, 1989.
7. **Chandrasekar CR, Grimer RJ, Carter SR et al.** Modular endoprosthetic replacement for tumours of the proximal femur. *J Bone Joint Surg* 2009 ; 91-B : 108-112.
8. **Crockarell JR, Hanssen AD, Osmon DR, Morrey BF.** Treatment of infection with debridement and retention of components following total hip arthroplasty. *J Bone Joint Surg* 1998 ; 80-A : 1306-1313.
9. **Davis AM, Wright JG, Williams JI et al.** Development of a measure of physical function for patients with bone and soft tissue sarcoma. *Qual Life Res* 1996 ; 5 : 508-516.
10. **DeLee JG, Charnley J.** Radiological demarcation of cemented sockets in total hip replacement. *Clin Orthop Relat Res* 1976 ; 121 : 20-32.
11. **Della Valle CJ, Paprosky WG.** Classification and an algorithmic approach to the reconstruction of femoral deficiency in revision total hip arthroplasty. *J Bone Joint Surg* 2003 ; 85-A : 1-6.
12. **Gie GA, Linder L, Ling RS et al.** Impacted cancellous allografts and cement for revision total hip arthroplasty. *J Bone Joint Surg* 1993 ; 75-B : 14-21.
13. **Goulet JA, Pellicci PM, Brause BD, Salvati EA.** Prolonged suppression of infection in total hip arthroplasty. *J Arthroplasty* 1988 ; 3 : 109-116.
14. **Gross AE, Hutchinson CR.** Proximal femoral allografts for reconstruction of bone stock in revision arthroplasty of the hip. *Orthop Clin North Am* 1998 ; 29 : 313-317.
15. **Gross AE, Hutchison CR, Alexeeff M et al.** Proximal allografts for reconstruction of bone stock in revision arthroplasty of the hip. *Clin Orthop Relat Res* 1995 ; 319 : 151-158.
16. **Gruen TA, MacNeice GM, Amstutz HG.** Modes of failure of cemented stem-type femoral components: a radiographic analysis of loosening. *Clin Orthop Relat Res* 1979 ; 141 : 17-27.
17. **Haddad FS, Garbuz DS, Masri BA, Duncan CP.** Structural proximal femoral allografts for failed total hip replacements. *J Bone Joint Surg* 2000 ; 82-B : 830-836.
18. **Haddad FS, Muirhead-Allwood SK, Manktelow ARJ, Bacarese-Hamilton I.** Two-stage uncemented revision hip arthroplasty for infection. *J Bone Joint Surg* 2000 ; 82-B : 689-694.
19. **Harris WH.** Traumatic arthritis of the hip after dislocation and acetabular fractures : treatment by mould arthroplasty. *J Bone and Joint Surg* 1969 ; 51-A : 737-755.
20. **Head WC, Mallory TH, Berklacich FM et al.** Extensile exposure of the hip for revision arthroplasty. *J Arthroplasty* 1987 ; 2 : 265-273.

21. **Jaiswal PK, Jagiello J, David LA et al.** Use of an 'internal proximal femoral replacement' with distal fixation in revision arthroplasty of the hip. *J Bone Joint Surg* 2008 ; 90-B : 11-15.
22. **Kanthor GS, Osterkamp JA, Dorr LD et al.** Resection arthroplasty following infected total hip replacement. *J Arthroplasty* 1986 ; 1 : 83-89.
23. **Malkani AL, Settecerrie JJ, Sim FH, Chao EY, Wallrichs SL.** Long-term results of proximal femoral replacement for non-neoplastic disorders. *J Bone Joint Surg* 1995 ; 77-B : 351-356.
24. **Manoso MW, Frassica DA, Lietman ES, Frassica FJ.** Proximal femoral replacement for metastatic bone disease. *Orthopedics* 2007 ; 30 : 384-388.
25. **Masri BA, Dominic Meek RM, Duncan CP.** Peri-prosthetic fractures : evaluation and classification. *Clin Orthop Relat Res* 2004 ; 420 : 80-95.
26. **Nestor BJ, Hanssen AD, Ferrer-Gonzalez R, Fitzgerald RH.** The use of porous prostheses in delayed reconstruction of total hip replacements that have failed because of infection. *J Bone Joint Surg* 1994 ; 76-A : 349-359.
27. **Parvizi J, Sim FH.** Proximal femoral replacements with megaprotheses. *Clin Orthop Relat Res* 2004 ; 420 : 169-175.
28. **Parvizi J, Tarity TD, Slenker N et al.** Proximal femoral replacement in patients with non-neoplastic conditions. *J Bone Joint Surg* 2007 ; 89-A : 1036-1043.
29. **Raut VV, Siney PD, Wroblewski BM.** One-stage revision of infected total hip replacements with discharging sinuses. *J Bone Joint Surg* 1994 ; 76-B : 721-724.
30. **Rubash HE, Sinha RK, Shanbhag AS, Kim SY.** Pathogenesis of bone loss after total hip arthroplasty. *Orthop Clin North Am* 1998 ; 29 : 173-186.
31. **Salvati EA, Chekofsky KM, Brause BD, Wilson PD.** Reimplantation in infection : a 12-year experience. *Clin Orthop Relat Res* 1982 ; 170 : 62-75.
32. **Sim FH, Chao EY.** Hip salvage by proximal femoral replacement. *J Bone Joint Surg* 1981 ; 63-A : 1228-1239.
33. **Winkler H, Stoiber A, Kaudela K, Winter F, Menschik F.** One-stage uncemented revision of infected total hip replacement using cancellous allograft bone impregnated with antibiotics. *J Bone Joint Surg* 2008 ; 90-B : 1580-1584.
34. **Zehr RJ, Enneking WF, Scarborough MT.** Allograft-prosthesis composite versus megaprosthesis in proximal femoral reconstruction. *Clin Orthop Relat Res* 1996 ; 322 : 207-223.