



## Autologous matrix-induced chondrogenesis (AMIC) A one-step procedure for retropatellar articular resurfacing

Jan Philipp BENTHIEN, Peter BEHRENS

From Basel University Hospital, Basel, Switzerland and Luebeck University Hospital, Luebeck, Germany

**The objective of this technical note is to describe the autologous matrix induced chondrogenesis (AMIC) procedure and to evaluate its possible role for resurfacing of retropatellar cartilage defects.**

**AMIC is a one-step procedure combining microfracturing with application of a collagen I/III membrane to protect the initial blood clot and to serve as a scaffold for the developing chondrocytes.**

**A retrospective analysis of our experience in three patients followed for 18 months is presented.**

**Keywords :** retropatellar cartilage defects ; autologous matrix induced chondrogenesis.

### INTRODUCTION

There is no gold standard treatment of cartilage defects. Several methods have been developed for this purpose. One method is simple abrasion chondroplasty (6,8) with which the defects in the cartilage are shaved and debrided. Brittberg (7,14) introduced autologous chondrocyte transplantation (ACT), which involves a two-step procedure : chondrocytes are harvested from a non-weight-bearing area, processed in laboratory and, in a second procedure, implanted in the defect protected by a periosteal flap.

Steadman *et al* (16,17) introduced microfracturing, in which the subchondral bone/cartilage border is perforated with an osteotome, thus encouraging the development of fibrous cartilage from mesenchymal stem cells (MSCs) that evolve directly

from the subchondral blood vessels. The defect and the site of microfracturing are not covered.

A different method is transplantation of osteochondral transplants from a non weight bearing donor site to the defect in a one-step procedure (osteochondral autologous transplantation or OATS) (10,12).

Matrix-induced chondrogenesis has long been a subject of research with a collagen matrix serving as a scaffold for cartilage formation (3,4,9,15). Matrix-induced autologous chondrocyte transplantation (MACT) involves a method with which a membrane is applied on transplanted chondrocytes in a chondral defect (4).

Autologous matrix induced chondrogenesis (AMIC) as first introduced by Behrens (3), is a one-step procedure combining the standard procedure of

---

■ Jan Philipp Benthien, MD, Assistant Professor, Head of Hip, Knee and Endoprosthesis Division.

*Department of Orthopaedic Surgery, University of Basel, Switzerland.*

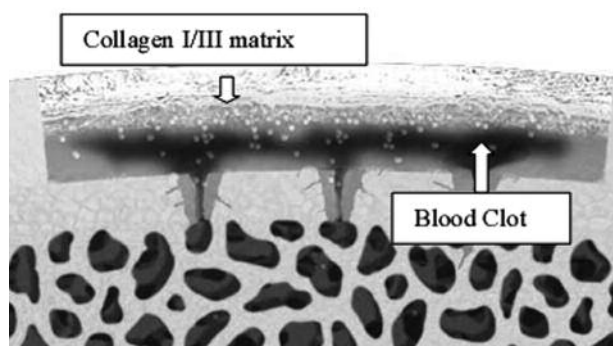
■ Peter Behrens, MD, Professor of Orthopaedic Surgery.

*Department of Orthopaedic Surgery, University of Luebeck, Germany.*

Correspondence : Jan P. Benthien, PD Dr. med, Assistant Professor, Head of Hip, Knee and Endoprosthesis Division, Department of Orthopaedic Surgery, University Hospital Basel Spitalstrasse 21, CH-4031 Basel, Switzerland.

E-mail : [jbenthien@uhbs.ch](mailto:jbenthien@uhbs.ch)

© 2010, Acta Orthopædica Belgica.



**Fig. 1.** — Principle of the autologous matrix-induced chondrogenesis (AMIC). A scaffold protects the blood clot which is supplied by vessels from the cancellous bone stock.

microfracturing with the coverage of the defect by a collagen I/III matrix (fig 1). Its potential in marrow stimulation has later been confirmed by Steinwachs *et al* (18). The membrane protects the blood clot and its mesenchymal stem cells (fig 1).

Typical indications are symptomatic full-thickness chondral and subchondral defects in the major joints, post-traumatic or osteochondrosis dissecans, located in main weight-bearing areas of a joint or in the area of maximal pain.

This procedure should not be performed when kissing lesions (2 defects on opposite sides), inflammatory diseases (e.g. rheumatoid arthritis), associated fracture, tumour or generalised osteoarthritis are present, nor in non compliant patients.

This technical note describes the procedure and reflects our experience with the AMIC method.

### Surgical procedure

A patient qualifies for the AMIC method if a chondral defect in the articular surface of the patella has been diagnosed. Patella tracking should have been restored to normal. Varus or valgus malalignment should be recognized and corrected before the procedure is considered.

Initially arthroscopy is performed to evaluate the size and location of the defect and also the amount of accompanying disorder. A mini arthrotomy is accomplished, and the defect is visualized openly. The defective cartilage tissue and subchondral bone

is removed with a very sharp curette. Micro-fracturing is performed to reach the subchondral intraosseous blood vessels. The size of the defect is evaluated, and a commercially available collagen I/III membrane is applied. It should be slightly undersized. An aluminium template may be used to define the correct size of the membrane. A blood sample is taken from the patient and prepared with a centrifuge.

The serum is mixed with commercially available fibrin glue, using only the fibrinogen component. This yields a partial autologous fibrin glue (PAF) where the thrombin component is autologous and the fibrinogen component allogenic. The membrane is glued to the defect.

After fixation of the matrix, the joint is slowly and gently moved to ensure that the membrane stays in place. The matrix may also be fixed with commercially available allogenic fibrin glue or it may be sutured.

Postoperatively, 6 weeks of partial weight bearing is recommended, accompanied by a limited range of flexion with full extension. Ninety degrees flexion should be reached after 6 weeks.

### Our experience

In a retrospective analysis of 3 patients with retropatellar osteochondral defects we noted an improvement of the Oxford Knee Score after 18 months. One of these patients had been treated with microfracturing alone and was referred to us for the AMIC procedure. In postoperative radiographs and MRI scans, defect closure was noted.

### DISCUSSION

Patellar chondral injuries account for a broad spectrum of patients with anterior knee pain (11). Most studies show that, overall, isolated retropatellar lesions are less common but still important as a morbidity factor for anterior knee pain (5,6,13). However, since most studies focus on the arthroscopic treatment of cartilage defects, retropatellar lesions may be uncommonly reported because they are not easily accessible to arthroscopic treatment (5).

Simple abrasion chondroplasty is still applied, but results in former studies have varied (6,8). Recent data for this method are rare. Friedmann *et al* reported that 82% of patients with isolated patellofemoral chondromalacia responded well after abrasion arthroplasty alone (8), while Bert *et al* reported that 33% of patients did worse after abrasion arthroplasty (6).

Steadman *et al* (16,17) have reported excellent results with microfracturing in 72 patients with chondral defects, which included 8 retropatellar defects. Regardless of lesion location, 95% of patients had decreased symptoms and improved function. Other authors have not been able to replicate these results (13). The small number of patellar defects in that study shows the scarcity of this location as compared to other locations. Mithoefer *et al* (13) studied 48 patients with isolated femoral defects (including 23% trochlear lesions) treated with microfracturing : 67% of the patients reported good or excellent results. Autologous osteochondral grafting is an option for full thickness defects, with limitations related to the defect size and the donor site morbidity (10).

Bartlett *et al* and Brittberg *et al* reported good to excellent results after ACT (2,16,17). Matrix-induced autologous chondrocyte implantation (MACI) has the disadvantage of a procedure similar to ACT with the addition of an expensive membrane but seems to yield satisfying results (4).

The AMIC procedure as described in this paper has the advantage of a one-step procedure that combines microfracturing with the possibility of chondrocyte differentiation from MSCs on a collagen matrix. It may actually be considered as a further development of microfracturing.

A unique feature of this method is that the blood clot formed initially as a result of microfracturing is protected and that the collagen membrane may be used as a scaffold for chondrocytes to form (9) (fig 1).

However, although microfracturing has been well documented for over 10 years, this new AMIC procedure has to be further evaluated by prospective randomized studies. These are currently performed.

It has yet to show its advantages over microfracturing or simple débridement alone. A disadvantage

which may be minimized by minimally invasive methods is the open procedure (1). Our cases seem to support the value of the AMIC procedure in retropatellar defects, a problem which, according to the literature, is difficult to treat arthroscopically and may be unresponsive to simple microfracturing alone.

The addition of Platelet Rich Plasma (PRP) may be considered, to encourage differentiation of chondrocytes. However, this should be studied carefully as the exact influence of the growth factors included in PRP on mesenchymal stem cells and chondroblasts is not well understood. Full replacement of the partial autologous fibrin glue with PRP is not advisable due to PRP's low adhesive potential.

## CONCLUSION

No definite statement about the AMIC procedure may be given, since long term results with this method are missing and our experience is based on three cases with a follow-up of 18 months. The Oxford Knee score improvement obtained in these three cases is encouraging. Since retropatellar lesions seem to do less well with both ACT and OATS (5), the AMIC technique may be an option. It is too early to make a complete evaluation of this method. Further randomised cohort studies are encouraged.

## REFERENCES

1. Anders S, Schaumburger J, Schubert T, Grifka J, Behrens P. Matrix-associated autologous chondrocyte transplantation : minimally invasive technique. *Oper Orth Traumatol* 2008 ; 20 : 208-219.
2. Bartlett W, Skinner JA, Gooding CR *et al*. Autologous chondrocyte implantation versus matrix-induced autologous chondrocyte implantation for osteochondral defects of the knee. A prospective randomized study. *J Bone Joint Surg* 2005 ; 87-B : 640-645.
3. Behrens P, Bosch U, Bruns J *et al*. [Indications and implementation of recommendation of the working group "Tissue regeneration and Tissue Substitution" for autologous chondrocyte transplantation.] (in German). *Z Orthop Ihre Grenzgeb* 2004 ; 142 : 529-539.
4. Behrens P, Bitter T, Kurz B, Russlies M. Matrix associated autologous chondrocyte transplantation – a 5 year follow up. *Knee* 2006 ; 13 : 194-202.

5. **Bentley G, Biant LC, Carrington RWJ et al.** A prospective, randomised comparison of autologous chondrocyte implantation versus mosaicplasty for osteochondral defects of the knee. *J Bone Joint Surg* 2003 ; 85-B : 223-230.
6. **Bert JM, Maschka K.** The arthroscopic treatment of uni-compartmental gonarthrosis : A five year follow up study of abrasion arthroplasty plus arthroscopic débridement and arthroscopic débridement alone. *Arthroscopy* 1989 ; 5 : 25-32.
7. **Brittberg M.** Autologous chondrocyte implantation-technique and long-term follow-up. *Injury* 2008 ; 39 Suppl : S40-49.
8. **Friedmann MJ, Berasi CC, Fox JM et al.** Preliminary results with abrasion arthroplasty in the osteoarthritic knee. *Clin Orthop Rel Res* 1984 ; 182 : 200-205.
9. **Gille J, Ehlers EM, Okroi M, Ruslies M, Behrens P.** Apoptotic chondrocyte death in cell matrix biocomposites used in autologous chondrocyte transplantation. *Annals Anat* 2002 ; 184 : 317-323.
10. **Jakob RP, Franz T, Gautier E, Mainil-Varlet P.** Autologous osteochondral grafting in the knee : indication, results and reflections. *Clin Orthop Relat Res* 2002 ; 401 : 170-184.
11. **Kramer DE, Kocher MS.** Management of patellar and trochlear chondral injuries. *Oper Tech Orthop* 2007 ; 17 : 234-243.
12. **Lahav A, Burks RT, Greis PE et al.** Clinical outcomes following osteochondral autologous transplantation (OATS). *J Knee Surg* 2006 ; 19 : 169-173.
13. **Mithoefer K, Williams RJ, Warren RF et al.** The microfracture technique for the treatment of articular cartilage lesions in the knee. A prospective cohort study. *J Bone Joint Surg* 2005 ; 87-A : 1911-1920.
14. **Peterson L, Minas T, Brittberg M et al.** Two to 9-year outcome after autologous chondrocyte transplantation of the knee. *Clin Orth Relat Res* 2000 ; 374 : 212-234.
15. **Skodacek D, Brandau S, Deutsche T, Lang S, Rotter N.** Growth factors and scaffold composition influence properties of tissue engineered human septal cartilage implants in a murine model. *Int J Immunopathol Pharmacol* 2008 ; 21 : 807-816.
16. **Steadman JR, Briggs KK, Rodrigo JJ et al.** Outcomes of microfracture for traumatic chondral defects of the knee- average 11 year follow up. *Arthroscopy* 2003 ; 15 : 477-484.
17. **Steadman JR, Rodkey WG, Rodrigo JJ.** Microfracture : surgical technique and rehabilitation to treat chondral defects. *Clin Orthop Relat Res* 2001 ; 391 : S362-369.
18. **Steinwachs, MR, Guggi T, Kreuz PC.** Marrow stimulation techniques. *Injury* 2008 ; 39 Suppl 1 : S26-31.