



Non-tuberculous thoracic and lumbar spondylodiscitis : single-stage anterior debridement and reconstruction, combined with posterior instrumentation and grafting

Metin OZALAY, Orcun SAHIN, Alihan DERINCEK, Ulas ONAY, Tugba TURUNC, Mustafa UYSAL

From Baskent University Hospital and Malazgirt State Hospital, Ankara, Turkey

Debridement is warranted for the treatment of non-tuberculous spondylodiscitis in case of neurological compromise, deformity, instability, abscess formation, extensive destruction, intractable pain or failure of medical management. The additional use of instrumentation is still controversial, but might fight infection and yield stability. The purpose of this retrospective study was to evaluate the outcome of 16 cases of non-tuberculous thoracic or lumbar spondylodiscitis treated with anterior debridement and reconstruction (tricortical graft or titanium mesh cage), combined with single-stage posterior instrumentation and grafting. The pathogens identified were : *Brucella* (5), coagulase-negative *Staphylococcus aureus* (4), *Staphylococcus aureus* (3), unidentified (4). All 16 infections resolved without recurrence. Bony union was obtained in all cases. Fourteen out of 16 patients (87.5%) were completely relieved of pain and fully active, an excellent result according to Macnab's criteria ; the other two patients obtained a good result. All 7 patients who had a neurological deficit improved. There were two superficial infections, which healed with debridement and antibiotics. A single iliac vein injury was primarily repaired. In conclusion, the proposed technique is an effective and safe treatment for pyogenic spondylodiscitis, if surgery is mandatory.

Keywords : spondylodiscitis ; debridement ; reconstruction ; instrumentation ; single-stage.

INTRODUCTION

The increasing number of spinal infections has become a global health concern. It is currently due to reactivation of latent infections, more drug-resistant agents and more immunocompromised patients. It has been shown that delay in diagnosis can lead to increased morbidity and mortality (4,9,17) ; early diagnosis and treatment are therefore of paramount importance.

-
- Metin Ozalay, MD, Associate Professor.
 - Alihan Derincek, MD, Orthopaedic Surgeon.
 - Ulas Onay, MD, Orthopaedic Resident.
 - Mustafa Uysal, MD, Assistant Professor.
Department of Orthopaedics and Traumatology, Baskent University, Ankara, Turkey.
 - Tugba Turunc, MD, Associate Professor.
Department of Infection Diseases, Baskent University, Ankara, Turkey.
 - Orcun Sahin, MD, Orthopaedic Surgeon
Department of Orthopaedics and Traumatology, Malazgirt State Hospital, Ankara, Turkey.
Correspondence : Metin Ozalay, Baskent University, Department of Orthopaedics and Traumatology, Fevzi Cakmak Caddesi. 10. sokak, No : 45, 06490 Ankara, Turkey.
E-mail : mozalay@hotmail.com
© 2010, Acta Orthopædica Belgica.
-

Spinal infections encompass a spectrum of conditions comprising spondylitis, discitis, spondylodiscitis, pyogenic facet arthropathy, epidural infection, meningitis, polyradiculopathy and myelitis (42). All of these have a specific presentation and clinical course.

In general, haematogenous pyogenic infection of the spine has been reported as either spondylodiscitis or pyogenic osteomyelitis (5). It is a rare condition, but increased experience has led to more successful treatment (11,12). Long periods of intravenous antibiotic therapy and immobilization with a brace are most often sufficient. Surgery is indicated in case of neurological compromise, deformity, instability, abscess formation, extensive destruction, intractable pain or failure of medical management.

There is still controversy about the best surgical treatment. Many spine surgeons are unwilling to place an implant in an infected area. Some authors go one step further and advocate debridement-only surgery, followed by antibiotic treatment and second-stage instrumentation (10,32,34). Other authors propose single-stage anterior decompression, bone grafting and instrumentation (2,3,13,29). We propose an intermediate approach: anterior debridement and reconstruction (tricortical graft or titanium mesh cage) combined with single-stage posterior instrumentation.

PATIENTS AND METHODS

Sixteen patients (9 males, 7 females) with a mean age of 66 years (range: 43-80) were included in the study (table I). The inclusion criteria were: non-tuberculous spondylodiscitis, surgical treatment as described above, a minimum follow-up of two years, and regular check-ups (3 weeks postoperatively, 1 month, 3 months, 6 months and annually thereafter). The exclusion criteria were: post-surgery spondylodiscitis, or staged surgery.

These 16 surgical cases were part of a larger group of 74 patients with non-tuberculous spondylodiscitis; the other 58 cases were successfully treated conservatively with antibiotics. The mean duration of symptoms before admission was 3.7 months (range: 0.5 to 12 months) and the mean duration of conservative treatment before surgery was 2.2 months (range: 1 to 3 months). The average follow-up period was 32.9 months (range: 24 to

48 months). Medical comorbidities were present in all patients except two: mostly diabetes mellitus (9 patients). The thoracic spine was involved in 6 patients, the thoracolumbar junction in 2, and the lumbar spine in 8; all infections were monofocal, except case 4 which was bifocal.

All patients had fever and pain on palpation. The Frankel classification was used for pre- and postoperative neurological evaluation. Thirteen out of 16 patients (81.2%) had an elevated white blood cell count, while all 16 had an elevated ESR and CRP level (table I). Plain radiographs, magnetic resonance imaging (MRI), and radionuclide studies (technetium- and/or gallium-67 scanning) were performed in all patients and reviewed with a radiologist. MRI-scans assessed the size of any abscess (epidural, pre- or paravertebral) and changes such as oedema and myelomalacia (fig 1). The bone scans were used to rule out multi-focal involvement.

The diagnosis of non-tuberculous spondylodiscitis was based on physical examination, neuro-imaging, laboratory findings and percutaneous needle biopsy (40). The following pathogens were identified: *Brucella* (5), coagulase-negative *Staphylococcus aureus* (4), *Staphylococcus aureus* (3); no pathogen was identified in 4 cases.

Preoperatively, two bactericidal and synergistic antibiotics were administered intravenously in high doses: mostly a first-generation cephalosporin and an aminoglycoside. Postoperatively, the antibiotics were adapted to the antibiogram performed on the specimens obtained. The duration of treatment was determined by the clinical evolution, the ESR and the C-reactive protein. Generally speaking, the antibiotics were administered intravenously for 6 weeks, and orally for 6 weeks.

A single surgical team performed all the operations. Patients were operated in the lateral decubitus position for the anterior radical debridement and reconstruction, and subsequently in the prone position for the posterior instrumentation and grafting. A meticulous debridement of all granulation tissue, devitalized disc and sequestra was carried out down to bleeding cancellous healthy bone. Pyogenic and tuberculous organisms were traced via Gram staining, cultures and histological examination. Wide decompression of the thecal sac was done, while any epidural abscess was drained. If a corpectomy was performed, a titanium mesh cage (TMC) was used in order to achieve stability of the spine. If only an anterior discectomy was performed, a tricortical iliac autograft (TCG) was used. No plates or other supplemental devices were used anteriorly. Finally, a midline incision exposed the posterior elements and the transverse processes. Pedicular screws allowed a firm grip for the

Table I. — Clinical material

N°	Age (years)	Risk Factor	Follow-up (mo)	Symptoms before admission (mo)	ESR (mm)	CRP (mg/l)	WBC (n/mm ³)	Micro-organism
1	69	DM	24	0.5	85	104	18600	S.aureus
2	56	DM, CRF	28	2	74	115	12100	S.aureus
3	43	CLF	32	12	99	112	11400	CNS
4	55	DM	24	5	77	54	16800	Not identified
5	56	COLD	48	3	92	96	17900	S.aureus
6	63	DM	42	3	64	24	6500	Brucella
7	75	DM	38	2	33	25	28300	Brucella
8	80	None	26	1	110	96	8600	Not identified
9	79	None	29	1	63	96	12000	Not identified
10	68	DM	31	0.5	110	51	10600	CNS
11	70	UTI	36	12	105	96	15500	Brucella
12	64	CAD	35	9	90	85	6750	Brucella
13	77	DM	41	3	44	96	17900	CNS
14	67	CRF	40	2	51	96	11600	CNS
15	58	DM	25	3	62	33	12500	Brucella
16	76	DM, CAD	28	1	59	37	15050	Not identified

DM : Diabetes mellitus ; CRF : Chronic renal failure ; CLF : Chronic liver failure ; COLD : Chronic obstructive lung disease ; CAD : Coronary artery disease ; UTI : Urinary tract infection.

CNS : Coagulase negative staphylococcus.

internal fixator, after which autologous iliac bone grafts were added (fig 2). Postoperatively all patients were immediately mobilized with an external thoracolumbosacral orthosis. Duration of surgery and preoperative blood loss were recorded.

The clinical outcome was assessed according to the modified Macnab criteria (30) : 4 different grades from excellent to poor. Radiological evaluations were performed by one investigator blinded to the clinical outcome. Interbody fusion by means of a tricortical graft was confirmed when bony trabeculae crossed the entire length of the graft bed and graft. When a mesh cage was used, fusion was deemed to have occurred when the following conditions were fulfilled : no pain or tenderness over the site of the operation, a 'sentinel sign' (bone bridging the interspace anterior to the cage on a lateral view) (31), no radiological signs of loosening or failure of the implant, and less than 3° of angular change on lateral flexion/extension radiographs. The Cobb method was used to measure kyphosis.

RESULTS

The mean duration of surgery was 4.2 hours (range : 3 hours to 5 hours). An epidural abscess was drained in 6 patients, and a gluteal abscess in one of these. In 2 patients, a lung abscess was detected during surgery and drained by a thoracic surgeon. A tricortical graft (TCG) was used in 12 cases and a Titanium mesh cage (TMC) in 4 (table II). In case 4, which was bifocal, TCG and TMC were used at separate levels. The estimated blood loss was 820 ml (range 420-1000 ml).

After surgery, infection was successfully controlled in all patients, and white blood cell count, ESR and CRP returned to normal in a mean of 4.8 months (range, 2 to 6 months).

Three patients had complications. Two had a superficial infection, posteriorly, which healed with

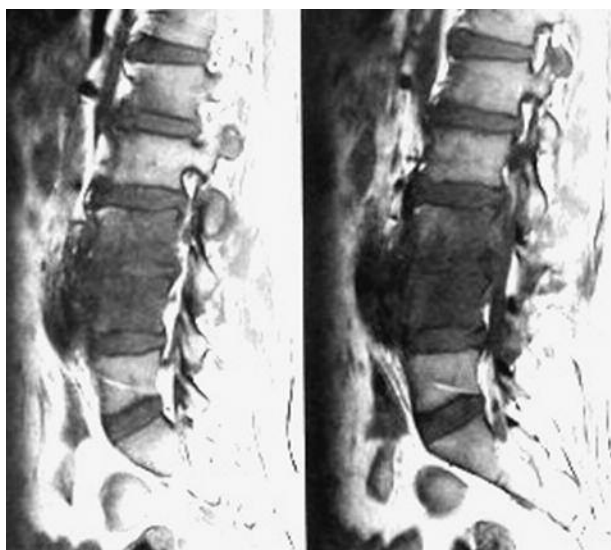


Fig. 1. — Preoperative sagittal MRI-scan of the lumbar spine. T2-weighted images showing L3-L4 spondylodiscitis.

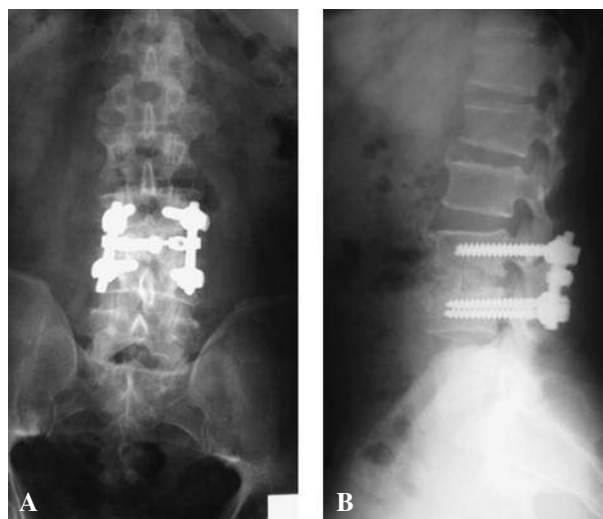


Fig. 2. — A, B. Postoperative antero-posterior and lateral radiographs showing L3-L4 anterior reconstruction and posterior spinal instrumentation.

Table II. — Outcome analysis

No	Epidural Abscess	TMC/TCG	Complications	2 nd surgery	Frankel Pre/Post	Macnab criteria
1	–	TCG	None	None	E/E	Excellent
2	+	TMC	None	None	E/E	Excellent
3	+	TCG	Superficial infection	Debridement	B/D	Good
4	–	TCG+TMC	None	None	E/E	Excellent
5	+	TMC	None	None	C/E	Excellent
6	–	TCG	None	None	E/E	Excellent
7	–	TMC	Superficial infection	Debridement	B/D	Good
8	–	TCG	None	None	E/E	Excellent
9	–	TMC	None	None	E/E	Excellent
10	+	TCG	None	None	E/E	Excellent
11	–	TCG	None	None	C/E	Excellent
12	–	TCG	Injury iliac vein	None	B/C	Excellent
13	+	TCG	None	None	D/E	Excellent
14	+	TCG	None	None	E/E	Excellent
15	–	TCG	None	None	E/E	Excellent
16	–	TCG	None	None	D/E	Excellent

TMC : Titanium mesh cage
TCG : Tricortical graft.

debridement and antibiotics. One sustained an iliac vein injury which was primarily repaired.

At final follow-up, 14 patients (87.5%) were completely relieved of pain and 2 (12.5%) had mild residual pain which did not interfere with their daily activities or require regular analgesics. According to Macnab's criteria, these 14 patients (87.5%) had an excellent result and 2 (12.5%) a good result (table II). All 7 patients with a neurological deficit improved. Bony fusion with incorporation of the graft was achieved in all patients. All infections had resolved without recurrence. There were no hardware problems. As to the kyphos, there was an average correction of 12.7° postoperatively, decreasing to 10.7° after a minimum follow-up of 2 years, which means an average loss of 2°.

DISCUSSION

Although there have been advances in diagnosis and treatment of spinal infections with further refinement of microbiological and histopathological techniques, early detection and management remain a matter of considerable difficulty (12). A correct diagnosis may be delayed by more than a month in over two thirds of the patients. A rise in the world's elderly and immunocompromised populations is bringing an increased incidence of pyogenic and granulomatous infections of the spine, hence, timely diagnosis of pyogenic spondylodiscitis with back pain and fever may prevent greater tissue destruction, spinal instability and progressive neurological deficit (41). Advances in therapy have reduced mortality rates, but early diagnosis is essential for a satisfactory outcome.

Conservative or operative treatment ?

Traditionally, the mainstay treatment of pyogenic infections of the spine remains medical management, with external immobilization and culture-specific antibiotics for a minimum of 4 to 6 weeks (33,38,39). However, large clinical series have demonstrated the need for surgical intervention in up to 43% to 57% of the patients, in case of neurological compromise, deformity, instability, abscess formation, extensive destruction, intractable pain or failure of medical management.

Anterior or posterior debridement ?

Vertebral osteomyelitis predominantly involves the vascular vertebral body, with involvement of the posterior elements in only 5% of the cases (5). This explains why anterior debridement has become the gold standard for a better infection control (7,10,12,14,19, 32,36,38).

Anterior or posterior instrumentation ?

Anterior debridement without instrumentation may lead to kyphosis (10,12,22), which is an argument for some kind of support. The use of instrumentation confers better sagittal balance, little loss of correction and high fusion rates compared with non-instrumented cases (12,20,21,32,35). Posterior instrumentation avoids the infected area and has been advocated by several authors (6,7,15,18,26,27, 41); the authors also chose for this technique. Anterior instrumentation in an infected area was first described by Kostuik (25). Recently, Dai *et al* (8) obtained 100% of good results with this technique in a series of 22 cases. This aspect is still controversial.

Single-stage or 2-stage approach ?

This is also a matter of debate (27). A number of authors have reported good results with a 2-stage approach for the treatment of spinal infections because they felt that a waiting period would be essential to optimize the patients' condition (1,10,19). On the other hand, some authors reported good results with minimum perioperative morbidity utilizing a single-stage approach (28,36,38). Also, the use of spinal instrumentation in the presence of active infection has been shown to be safe and effective (21,27,36,38). In a study by Kuklo *et al* (27) 21 patients with pyogenic vertebral osteomyelitis underwent single-stage surgery (mesh cage and posterior instrumentation); neither recurrence of infection nor perioperative complications were reported. A single-stage procedure has several advantages, such as avoidance of a second anaesthesia, reduced blood loss, avoidance of graft displacement during transfers, earlier mobilization,

less anxiety for the patient, shortened hospital stay and less expenses.

Clinical outcome

Recurrent infection has been mentioned in 2 to 18% of the cases after treatment of vertebral osteomyelitis with debridement and antibiotics (14, 20,33). Other series have reported a 0% recurrence rate (10,12,19,28), which was confirmed by the current study.

The fact that an objective functional outcome score was not used was a shortcoming of this study. Few similar series have reported such functional results. However, according to Macnab 's criteria (30), 87.5% of our patients had an excellent result, without pain or restriction of activity.

From a neurological viewpoint, all 7 patients with a neurological deficit improved, according to the Frankel classification. These findings were consistent with the literature (27,29,41).

Roentgenological outcome

After posterior instrumentation, fusion rates up to 93% and 96% have been reported (12,14,32). The current study did even better, with 100%. As stated by Hadjipavlou *et al* (20) posterior stabilization through instrumentation was the critical factor in these improved results. The authors believe that posterior instrumentation and grafting is the principal stabilizer of the vertebral column in order to achieve a successful fusion.

According to the literature, correction of the kyphosis has ranged from 7.2° to 12.4°, with 2.2° to 3.0° loss of correction at final follow-up (28,38). The authors noted an average correction of 12.7° post-operatively, decreasing to 10.7° after a minimum follow-up of 2 years, which means an average loss of 2°. Tricortical iliac crest bone graft has been shown to be the best option in the presence of infection (32). However, although the tricortical graft corrects the spinal alignment in the immediate postoperative period, long-term results have shown only partial correction (24) with complications such as pseudarthrosis, graft collapse, and extrusion, even in the presence of rigid posterior instrumenta-

tion (38). Fayazi *et al* (16) were first to try to avoid these problems by means of a titanium mesh cage (TMC), but could not avoid an average increase of the kyphosis with 10°. Other investigators found no adverse effect of the TMC on the course of the infection (23,27). The authors somehow preferred a tricortical graft when only a discectomy was performed, i.e. in 75% of the cases. Moreover, they did not detect any complications after use of a tricortical graft. They only used a TMC in case of corpectomy, creating a large defect. This decision was based on previous studies demonstrating that autograft as an anterior strut was superior in the face of infection (19,32).

REFERENCES

1. Arnold PM, Baek PN, Bernardi RJ, Luck EA, Larson SJ. Surgical management of nontuberculous thoracic and lumbar vertebral osteomyelitis : report of 33 cases. *Surg Neurol* 1997 ; 47 : 551-561.
2. Benli IT, Acaroglu E, Akalin S *et al*. Anterior radical debridement and anterior instrumentation in tuberculosis spondylitis. *Eur Spine J* 2003 ; 12 : 224-234.
3. Benli IT, Kaya A, Acaroglu E. Anterior instrumentation in tuberculous spondylitis : is it effective and safe ? *Clin Orthop Relat Res* 2007 ; 460 : 108-116.
4. Bouchez B, Arnott G, Delfosse JM. Acute spinal epidural abscess. *J Neurol* 1985 ; 231 : 343-344.
5. Calderone RR, Larsen JM. Overview and classification of spinal infections. *Orthop Clin North Am* 1996 ; 27 : 1-8.
6. Carragee E, Iezza A. Does acute placement of instrumentation in the treatment of vertebral osteomyelitis predispose to recurrent infection : long-term follow-up in immunosuppressed patients. *Spine* 2008 ; 33 : 2089-2093.
7. Carragee EJ. Pyogenic vertebral osteomyelitis. *J Bone Joint Surg* 1997 ; 79-A : 874-880.
8. Dai LY, Chen WH, Jiang LS. Anterior instrumentation for the treatment of pyogenic vertebral osteomyelitis of thoracic and lumbar spine. *Eur Spine J* 2008 ; 17 : 1027-1034.
9. Danner RL, Hartman BJ. Update on spinal epidural abscess : 35 cases and review of the literature. *Rev Infect Dis* 1987 ; 9 : 265-274.
10. Dimar JR, Carreon LY, Glassman SD *et al*. Treatment of pyogenic vertebral osteomyelitis with anterior debridement and fusion followed by delayed posterior spinal fusion. *Spine* 2004 ; 29 : 326-332.
11. Eismont FJ, Bohlman HH, Soni PL, Goldberg VM, Freehafer AA. Pyogenic and fungal vertebral osteomyelitis with paralysis. *J Bone Joint Surg* 1983 ; 65-A : 19-29.
12. Emery SE, Chan DP, Woodward HR. Treatment of hematogenous pyogenic vertebral osteomyelitis with

- anterior debridement and primary bone grafting. *Spine* 1989 ; 14 : 284-291.
13. **Eysel P, Hopf C, Vogel I, Rompe JD.** Primary stable anterior instrumentation or dorsoventral spondylodesis in spondylodiscitis ? Results of a comparative study. *Eur Spine J* 1997 ; 6 : 152-157.
 14. **Fang D, Cheung KM, Dos Remedios ID, Lee YK, Leong JC.** Pyogenic vertebral osteomyelitis : treatment by anterior spinal debridement and fusion. *J Spinal Disord* 1994 ; 7 : 173-180.
 15. **Faraj AA, Webb JK.** Spinal instrumentation for primary pyogenic infection. Report of 31 patients. *Acta Orthop Belg* 2000 ; 66 : 242-247.
 16. **Fayazi AH, Ludwig SC, Dabbah M, Bryan Butler R, Gelb DE.** Preliminary results of staged anterior debridement and reconstruction using titanium mesh cages in the treatment of thoracolumbar vertebral osteomyelitis. *Spine J* 2004 ; 4 : 388-395.
 17. **Feldenzer JA, McKeever PE, Schaberg DR, Campbell JA, Hoff JT.** Experimental spinal epidural abscess : a pathophysiological model in the rabbit. *Neurosurgery* 1987 ; 20 : 859-867.
 18. **Fountain SS.** A single-stage combined surgical approach for vertebral resections. *J Bone Joint Surg* 1979 ; 61-A : 1011-1017.
 19. **Graziano GP, Sidhu KS.** Salvage reconstruction in acute and late sequelae from pyogenic thoracolumbar infection. *J Spinal Disord* 1993 ; 6 : 199-207.
 20. **Hadjipavlou AG, Mader JT, Necessary JT, Muffoletto AJ.** Hematogenous pyogenic spinal infections and their surgical management. *Spine* 2000 ; 25 : 1668-1679.
 21. **Hee HT, Majd ME, Holt RT, Pienkowski D.** Better treatment of vertebral osteomyelitis using posterior stabilization and titanium mesh cages. *J Spinal Disord Tech* 2002 ; 15 : 149-156.
 22. **Hodgson AR, Stock FE, Fang HS, Ong GB.** Anterior spinal fusion. The operative approach and pathological findings in 412 patients with Pott's disease of the spine. *Br J Surg* 1960 ; 48 : 172-178.
 23. **Korovessis P, Petsinis G, Koureas G, Iliopoulos P, Zacharatos S.** One-stage combined surgery with mesh cages for treatment of septic spondylitis. *Clin Orthop Relat Res* 2006 ; 444 : 51-59.
 24. **Korovessis P, Sidiropoulos P, Piperos G, Karagiannis A.** Spinal epidural abscess complicated closed vertebral fracture. A case report and review of literature. *Spine* 1993 ; 18 : 671-674.
 25. **Kostuik JP.** Anterior spinal cord decompression for lesions of the thoracic and lumbar spine, techniques, new methods of internal fixation results. *Spine* 1983 ; 8 : 512-531.
 26. **Krödel A, Krüger A, Lohscheidt K, Pfahler M, Refior HJ.** Anterior debridement, fusion, and extrafocal stabilization in the treatment of osteomyelitis of the spine. *J Spinal Disord* 1999 ; 12 : 17-26.
 27. **Kuklo TR, Potter BK, Bell RS, Moquin RR, Rosner MK.** Single-stage treatment of pyogenic spinal infection with titanium mesh cages. *J Spinal Disord Tech* 2006 ; 19 : 376-382.
 28. **Liljenqvist U, Lerner T, Bullmann V et al.** Titanium cages in the surgical treatment of severe vertebral osteomyelitis. *Eur Spine J* 2003 ; 12 : 606-612.
 29. **Lim JK, Kim SM, Jo DJ, Lee TO.** Anterior interbody grafting and instrumentation for advanced spondylodiscitis. *J Korean Neurosurg Soc* 2008 ; 43 : 5-10.
 30. **Macnab I.** Negative disc exploration. An analysis of the causes of nerve-root involvement in sixty-eight patients. *J Bone Joint Surg* 1971 ; 53-A : 891-903.
 31. **McAfee PC.** Interbody fusion cages in reconstructive operations on the spine. *J Bone Joint Surg* 1999 ; 81-A : 859-880.
 32. **McGuire RA, Eismont FJ.** The fate of autogenous bone graft in surgically treated pyogenic vertebral osteomyelitis. *J Spinal Disord* 1994 ; 7 : 206-215.
 33. **McHenry MC, Easley KA, Locker GA.** Vertebral osteomyelitis : long-term outcome for 253 patients from 7 Cleveland-area hospitals. *Clin Infect Dis* 2002 ; 34 : 1342-1350.
 34. **Ozuna RM, Delamarter RB.** Pyogenic vertebral osteomyelitis and postsurgical disc space infections. *Orthop Clin North Am* 1996 ; 27 : 87-94.
 35. **Patzakis MJ, Rao S, Wilkins J, Moore TM, Harvey PJ.** Analysis of 61 cases of vertebral osteomyelitis. *Clin Orthop Relat Res* 1991 : 178-183.
 36. **Przybylski GJ, Sharan AD.** Single-stage autogenous bone grafting and internal fixation in the surgical management of pyogenic discitis and vertebral osteomyelitis. *J Neurosurg* 2001 ; 94 (1 suppl) : 1-7.
 37. **Rath SA, Neff U, Schneider O, Richter HP.** Neurosurgical management of thoracic and lumbar vertebral osteomyelitis and discitis in adults : a review of 43 consecutive surgically treated patients. *Neurosurgery* 1996 ; 38 : 926-933.
 38. **Safran O, Rand N, Kaplan L, Sagiv S, Floman Y.** Sequential or simultaneous, same-day anterior decompression and posterior stabilization in the management of vertebral osteomyelitis of the lumbar spine. *Spine* 1998 ; 23 : 1885-1890.
 39. **Sapico FL, Montgomerie JZ.** Pyogenic vertebral osteomyelitis : report of nine cases and review of the literature. *Rev Infect Dis* 1979 ; 1 : 754-776.
 40. **Stringham DR, Hadjipavlou A, Dzioba RB, Lander P.** Percutaneous transpedicular biopsy of the spine. *Spine* 1994 ; 19 : 1985-1991.
 41. **Sundararaj GD, Babu N, Amritanand R et al.** Treatment of haematogenous pyogenic vertebral osteomyelitis by single-stage anterior debridement, grafting of the defect and posterior instrumentation. *J Bone Joint Surg* 2007 ; 89-B : 1201-1205.
 42. **Tali ET.** Spinal infections. *Eur Radiol* 2004 ; 50 : 120-133.
 43. **Tay BK, Deckey J, Hu SS.** Spinal infections. *J Am Acad Orthop Surg* 2002 ; 10 : 188-197.