



Treatment of chronic wounds at the olecranon

Nadine HOLLEVOET, Wim VANHOVE, René VERDONK

From Ghent University Hospital, Ghent, Belgium

Surgical resection of the olecranon bursa may be complicated by wound healing problems. Treatment with debridement and primary skin closure can be attempted. We reviewed eight patients in whom this approach had failed. In four patients we achieved wound healing with a pedicled flap (three antecubital fasciocutaneous island flaps and one radial forearm flap). In three patients the wound healed after closure of the skin and immobilization of the elbow in extension. In one elderly patient with diabetes and rheumatoid arthritis an antecubital fasciocutaneous island flap failed. It can be concluded that the antecubital fasciocutaneous island flap and primary closure of the skin followed by immobilization of the elbow in extension can be used to treat chronic wounds at the olecranon.

Keywords : chronic wounds ; olecranon ; pedicled fasciocutaneous flap.

INTRODUCTION

Olecranon bursitis is generally caused by trauma (acute or repetitive), infection or inflammatory disease (4,9). Conservative treatment, which is usually successful, should be attempted first, as surgical resection of the bursa may be fraught with complications such as wound healing problems and recurrence (4,5).

When the surgical wound fails to heal, an attempt can be made to close the skin after debridement and excision of the fistula. This treatment is only indicated for small wounds where the skin can be

approximated without tension (7). In the event of larger soft-tissue defects, a flap is required. Several options exist, such as local transposition flaps, pedicled flaps and free flaps (4,7,8). Good results have been reported with the antecubital fasciocutaneous island flap (11). This is a pedicled flap based on a fasciocutaneous perforator arising from the radial artery in the distal part of the antecubital fossa, named the inferior cubital artery (2).

After surgical resection of an olecranon bursa, an elbow cast is often applied as too much flexion of the elbow can cause tension on the skin at the olecranon and impair the vascularisation. With the elbow in extension there is no tension on the dorsal skin, which allows for primary wound closure in the event of small soft-tissue defects. We immobilised the elbow in extension in a few patients even though immobilisation of the elbow joint in this position is generally not recommended because it can lead to stiffness and cause discomfort.

-
- Nadine Hollevoet, MD, PhD, Orthopaedic Surgeon.
 - Wim Vanhove, MD, Orthopaedic Surgeon.
 - René Verdonk, MD, PhD, Professor in Orthopaedic Surgery and Head of the Department.
Department of Orthopaedic Surgery and Traumatology, Ghent University Hospital, Ghent, Belgium.
- Correspondence : Nadine Hollevoet, Department of Orthopaedic Surgery and Traumatology, Ghent University Hospital, De Pintelaan 185, B-9000 Gent, Belgium.
E-mail : nadine.hollevoet@ugent.be
© 2010, Acta Orthopædica Belgica.
-

At our institution we treated eight patients who presented with persistent wound problems after one or more attempts had been made to close the skin following surgical resection of the olecranon bursa. The study was designed to retrospectively evaluate two treatment methods: the antecubital fasciocutaneous island flap and primary closure of the skin with immobilisation of the elbow in extension.

PATIENTS AND METHODS

Between October 2003 and February 2009 eight patients were treated at our institution for chronic wounds at the olecranon. All but one patient had initially been operated on at another hospital for olecranon bursitis. Previous attempts to close the wound with debridement, primary skin closure, antibiotics and splinting of the elbow in 90° of flexion had failed. One woman and seven men with a mean age of 56 years (range: 30-78) were reviewed. The medical files provided us with information on the number of previous operations at the olecranon, risk factors for wound healing (6,7), complications of the treatment and the time to wound healing (at the olecranon and at the donor site of the pedicled flap).

In five patients an antecubital fasciocutaneous flap was planned following the surgical technique described by Van Landuyt *et al* (11). An example of a chronic wound treated with this flap is given in fig 1a. The flap is centered at the junction between the middle and distal third of the forearm along the cephalic vein (fig 1b). Skin, subcutaneous tissue, and fascia are incised at the distal end of the flap, and the cephalic vein is identified and ligated. The flap is further elevated in the subfascial plane from distal to proximal. The pedicle contains adipofascial tissue on either side of the cephalic vein (fig 1c), and also includes the inferior cubital artery which tends to run along the cephalic vein in the forearm. In one patient the type of flap had to be changed because of anatomical variations, and a radial forearm flap, based on the radial artery, was used instead (10).

In three patients primary closure of the skin and immobilisation of the elbow in extension was the first choice of treatment. The wound was debrided and the skin closed with separate stitches. Postoperatively, a splint with the elbow in extension was applied. A few days later the splint was replaced by a circular cast with a window at the olecranon to enable wound care. The wrist was not immobilised. Elbow flexion was allowed when the wound had healed.

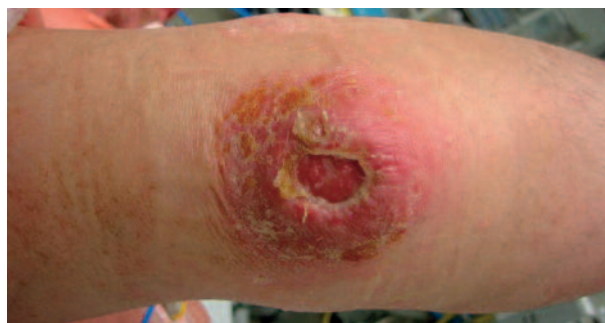

Fig. 1a. — Preoperative skin defect at the olecranon of a 41-year old man who was treated with an antecubital fasciocutaneous island flap.

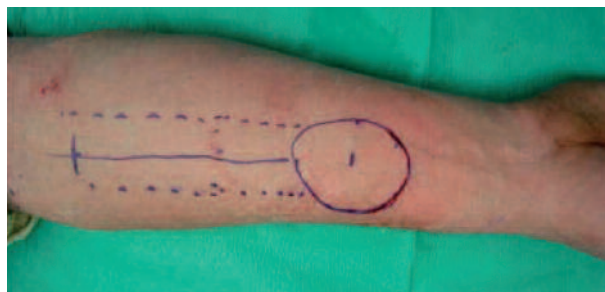


Fig. 1b. — Outline of the flap

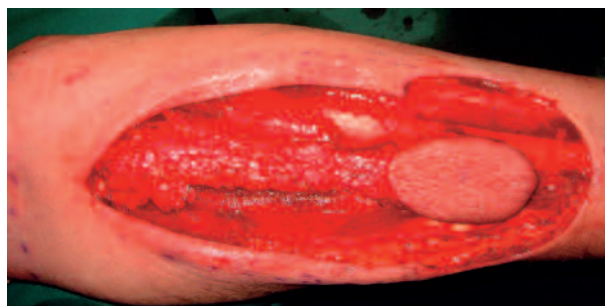

Fig. 1c. — Peroperative view of the flap and pedicle

RESULTS

The characteristics of the patients are presented in table I. They are numbered in chronological order of treatment. All patients had one or more factors that may have impeded wound healing such as diabetes, smoking and rheumatoid arthritis. Some patients took medications with a possible negative

Table I. — Patient data

N°	Sex	Age (yrs)	Risk factors for wound healing	Number of previous operations	Treatment	Complications	Days to wound healing
1	m	51	diabetes, smoking	4	FCF	skin graft loss	42
2	m	41	smoking	3	FCF	delayed healing skin graft	69
3	m	68	smoking	3	RFF	haematoma and infection at donor site	35
4	m	30	smoking	2	FCF	partial flap necrosis	58
5	m	50	smoking, anticoagulants	4	ext cast		39
6	f	77	diabetes, RA glucocorticoids, methotrexate	2	FCF ext cast	flap necrosis haematoma at donor site persistent fistula	–
7	m	78	RA, methotrexate glucocorticoids	1	ext cast		18
8	m	57	diabetes	4	ext cast		21

m : male, f : female, FCF : antecubital fasciocutaneous island flap, RFF : radial forearm flap, ext cast : extension cast elbow, RA : rheumatoid arthritis.

effect on wound healing, such as methotrexate, glucocorticoids and anticoagulants. All patients had undergone previous surgery, e.g. resection of the olecranon bursa. In some of them up to four attempts at primary skin closure had been made.

The antecubital fasciocutaneous island flap was planned in five patients, but we had to change the type of flap in one patient, because the cephalic vein was absent at the site where the flap was outlined. Complications are listed in table I. In four patients who were treated with a flap, wound healing was delayed at the donor site and in one patient at the olecranon because of partial flap necrosis, which may have been related to heavy smoking habits. Anatomical variations may also have played a role : the cephalic vein was more radial and dorsal than in the other patients and there probably was slightly too much tension on the pedicle. In one elderly patient with several risk factors for wound healing (diabetes, rheumatoid arthritis, glucocorticoids and methotrexate) the flap failed. The soft-tissue defect after removal of the dead flap

was small and the wound could be closed with the elbow in extension. The elbow was kept in extension for two weeks, but a fistula was still present two years postoperatively.

Because of flap complications, we also tried to achieve wound healing with immobilisation of the elbow in extension after primary closure of the skin. This method gave good results in three patients, without any complications such as residual stiffness. The time to wound healing was shorter in the patients treated with the elbow extension cast (table I). One elderly male patient who lived alone, had to be hospitalized during his treatment, because he was not able to take care of himself with his elbow immobilised in extension.

DISCUSSION

Several treatment options have been described to treat chronic wound problems with skin defects at the olecranon, such as primary skin closure, skin grafts, vacuum-assisted closure (VAC), local

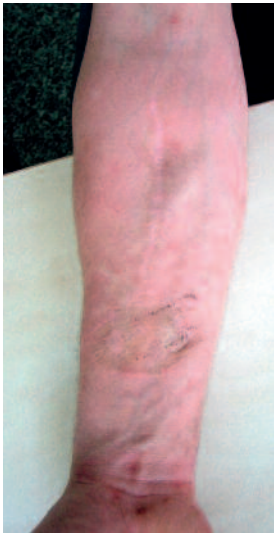

Fig. 1d. — Appearance of the donor site one year postoperatively.

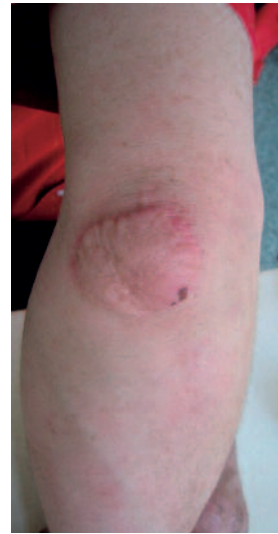

Fig. 1e. — Appearance of the flap one year postoperatively

random flaps, pedicled axial fasciocutaneous flaps (e.g., radial forearm flap, lateral arm flap, antecubital fasciocutaneous flap, posterior interosseous flap), pedicled muscle flaps and free flaps (4,7,8). For small defects good results have been reported with the anconeus flap, the radial forearm flap (3,7,8) and with a local transposition flap and skin graft (4).

The antecubital fasciocutaneous island flap can also be used to cover small defects and has several advantages : no major vessel is sacrificed, the arm contour is preserved (fig 1d and fig 1e) and sensation can be provided by including the lateral cutaneous nerve (11). However, anatomical variations of the palmar forearm veins may cause confusion when the flap is outlined. The cephalic vein may be absent in 3% of men and in 1% of women (1). We encountered some complications with this flap, such as skin graft rejection, haematoma and infection at the donor site and partial flap necrosis. In one patient the flap did not survive, probably because too many factors interfered with wound healing. Diabetes, smoking, old age and immunosuppressive medication have been reported to impair wound healing (6,7). Van Landuyt *et al* treated four patients with the antecubital fasciocutaneous island flap. Two of them presented risk

factors for wound healing but did not develop any complications (11).

For small skin defects at the olecranon, debridement of the wound and closure of the skin followed by immobilisation of the elbow in extension for 2 to 3 weeks, may be performed as an alternative to a flap. This treatment resulted in less complications and faster wound healing than did pedicled flaps. Wound healing problems at the olecranon are common, probably because the skin at the elbow becomes tight in flexion, which may impair vascularisation. The splint should not be removable, so as to prevent patients from flexing the elbow. We did not encounter any problems with elbow stiffness in the three patients treated with an elbow extension cast, but this treatment should probably be reserved for patients with normal elbow joints.

REFERENCES

1. **Botte MJ.** Vascular systems. In : Doyle JR, Botte MJ (eds). *Surgical Anatomy of the Hand & Upper Extremity*. Lippincott Williams & Wilkins, Philadelphia, 2003, p 237-293.
2. **Cormack GC.** The antecubital forearm flap. In : Gilbert A, Masquelet AC, Hentz VR (eds). *Pedicle Flaps of the Upper Limb*. 2nd ed, Martin Dunitz, London, 1992, p 81-88.

3. **Choudry UH, Moran SL, Li S, Khan S.** Soft-tissue coverage of the elbow : an outcome analysis and reconstructive algorithm. *Plast Reconstr Surg* 2007 ; 119 : 1852-1857.
4. **Damert HG, Altmann S, Schneider W.** [Soft-tissue defects following olecranon bursitis. Treatment options for closure.] (in German). *Chirurg* 2009 ; 80 : 448-454.
5. **Degreef I, De Smet L.** Complications following resection of the olecranon bursa. *Acta Orthop Belg* 2006 ; 72 : 400-403.
6. **Deodhar AK, Rana RE.** Surgical physiology of wound healing : a review. *Postgrad Med* 1997 ; 43 : 52-56.
7. **Jensen M, Moran SL.** Soft tissue coverage of the elbow : a reconstructive algorithm. *Orthop Clin North Am* 2008 ; 39 : 251-264.
8. **Stevanovic M, Sharpe F, Itamura JM.** Treatment of soft tissue problems about the elbow. *Clin Orthop Relat Res* 2000 ; 370 : 127-137.
9. **Stewart NJ, Manzanares JB, Morrey BF.** Surgical treatment of aseptic olecranon bursitis. *J Shoulder Elbow Surg* 1997 ; 6 : 49-54.
10. **Tizian C, Sanner F, Berger A.** The proximally pedicled arteria radialis forearm flap in the treatment of soft tissue defects of the dorsal elbow. *Ann Plast Surg* 1991 ; 26 : 40-44.
11. **Van Landuyt K, De Cordier BC, Monstrey SJ et al.** The antecubital fasciocutaneous island flap for elbow coverage. *Ann Plastic Surg* 1998 ; 41 : 252-257.