



## Giant sacral schwannoma A case report and review of the literature

Cagatay OZTURK, Cuneyt MIRZANLI, Omer KARATOPRAK, Mehmet TEZER, Mehmet AYDOGAN, Azmi HAMZAOGLU

*From the Istanbul Spine Center, Florence Nightingale Hospital, Istanbul, Turkey*

**Intraspinal schwannomas localized in the sacrum are relatively infrequent, accounting for 1-5% of all spinal axis schwannomas. They frequently grow to considerable size before detection ; hence, the term giant sacral schwannoma. Sacral schwannomas arise from the sacral nerve roots. The diagnosis of schwannomas in the spinal canal is difficult because of their slow growth, often resulting in extensive bony destruction. This case report documents the management of a 48-year-old male with a giant sacral schwannoma. We performed a two-stage surgery with intralesional tumour resection. The patient is now free of any complaint, complications and there is no recurrence two years after resection of the schwannoma. Intralesional excision of a sacral schwannoma is a less invasive procedure than total or partial sacrectomy. Using a combined anterior and posterior approach, satisfactory tumour excision and stabilization can be achieved, while avoiding the high morbidity related with total sacrectomy.**

**Keywords :** giant sacral schwannoma ; intralesional resection ; partial sacrectomy ; surgical treatment.

### INTRODUCTION

Schwannomas (neurilemomas) are benign neurogenic tumours arising from Schwann cells of the peripheral nerve sheath. These tumours have a predilection for the head and neck, the extremities and the posterior mediastinum (2). They occur without gender predominance in the 20 to 50 years age

group and are associated with von Recklinghausen's disease in 18% of cases (5). Malignant change is exceedingly rare.

Intraspinal schwannomas localized in the sacrum are relatively infrequent, accounting for 1-5% of all spinal axis schwannomas (8,10,17) ; they frequently grow to considerable size before detection ; hence, the term giant sacral schwannoma. Sacral schwannomas arise from the sacral nerve roots. Diagnosis of schwannomas in the spinal canal is difficult because of their late growth (12), often resulting in extensive bony destructions (1).

The symptoms are mild, and it is not until the tumour becomes large that patients notice pain or swelling. In the management of intrasacral schwannoma, curative treatment imposes total surgical removal because other treatments, including chemotherapy and radiotherapy, may not be

- 
- Cagatay Ozturk, MD, Consultant Orthopedic Surgeon.
  - Cuneyt Mirzanli, MD, Consultant Orthopedic Surgeon.
  - Omer Karatoprak, MD, Consultant Orthopedic Surgeon.
  - Mehmet Tezer, MD, Consultant Orthopedic Surgeon.
  - Mehmet Aydogan, MD, Consultant Orthopedic Surgeon.
  - Azmi Hamzaoglu, MD, Consultant Orthopedic Surgeon.

*Istanbul Spine Center, Florence Nightingale Hospital, Istanbul, Turkey.*

Correspondence : Cagatay Oztürk, Consultant Orthopedic Surgeon, Istanbul Spine Center, Florence Nightingale Hospital, Abide-I Hürriyet Cad. 290, 80220, Şişli, Istanbul-Turkey.  
E-mail : cgtyztrk@yahoo.com

© 2009, Acta Orthopædica Belgica.

effective. The surgical removal carries the risk of sacrificing nerve roots, causing severe functional impairment.

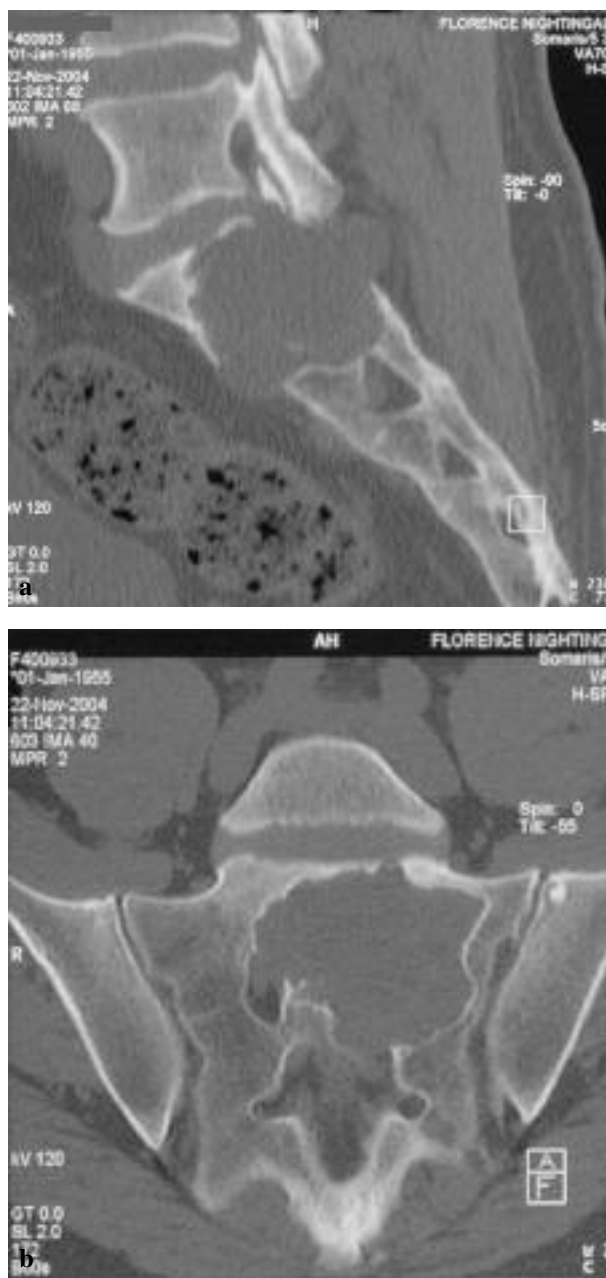
In this report, we document the management of a patient with a giant sacral schwannoma. The diagnosis was made preoperatively from clinical and radiological findings, and needle biopsy results. Despite the rarity of these tumours it is important that the diagnosis be considered preoperatively by the surgeon and the radiologist interpreting the scans, as well as the pathologist examining the needle biopsies. The diagnosis of this benign entity may influence further treatment by limiting surgical invasiveness and avoiding unnecessary adjuvant therapy.

### CASE REPORT

A 48-year-old male presented to our center with paraesthesia in the lower extremities and low back pain. Pain and paraesthesia had increased gradually during the last two months. He also had a history of mild back pain and sciatica over the last two years and was diagnosed previously as presenting a lumbar disc herniation and received some medical treatment and physiotherapy. There was no history of trauma and he was otherwise healthy.

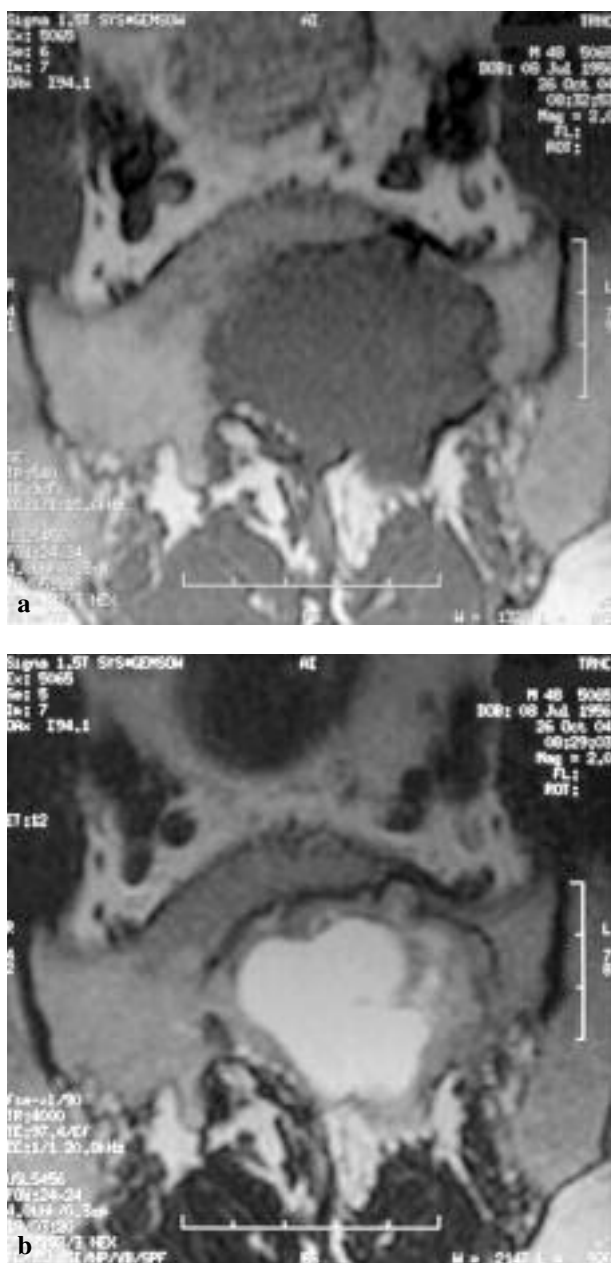
Percussion tenderness was elicited on the sacral region on physical examination. A bilateral positive straight leg raising test at 40° and numbness at both feet were noted. Sphincter tone and perianal sensation were normal. Laboratory tests and chest radiograph revealed no abnormalities.

Conventional radiographs of the pelvis and lumbosacral spine showed a missing contour of the body of S1 and S2. Computerized tomography (CT) investigation showed an intrasacral destructive and expansile mass originating from the left S1 nerve root, invasion of the sacral canal and erosion of S1 and upper half of S2 body. The mass was extending anteriorly into the presacral area via the left S1 foramen and posteriorly into the paraspinal area (fig 1). In addition, magnetic resonance imaging (MRI) identified a solitary soft tissue mass, which showed low signal isointense with the surrounding muscles in T1-weighted images and high signal and isointensity in T2-weighted images (fig 2). The



**Fig. 1.** — Computed tomography (CT) investigation showed an intrasacral destructive and expansile mass originating from the left S1 nerve root, invasion of sacral canal and erosion of S1 and upper half of S2 body. The mass was extending into the presacral area via the left S1 foramen anteriorly, and into the paraspinal area posteriorly.

central part of the mass was cystic in appearance. The dimension of the tumour was 6 × 5 × 3.5 centimeters.



**Fig. 2.** — Magnetic resonance imaging (MRI) identified a solitary soft tissue mass, which showed low signal isointense with the surrounding muscles in T1-weighted images and high signal and isointensity in T2-weighted images.

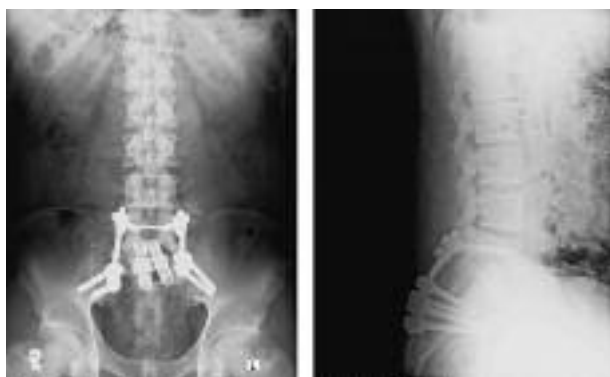After consultation with radiologists and pathologists, the lesion was thought to be benign, and a CT-guided biopsy was performed. Histological examination of the specimen revealed a cellular neoplasm

composed of short fascicles and spindle cells. The diagnosis was confirmed histopathologically as schwannoma.

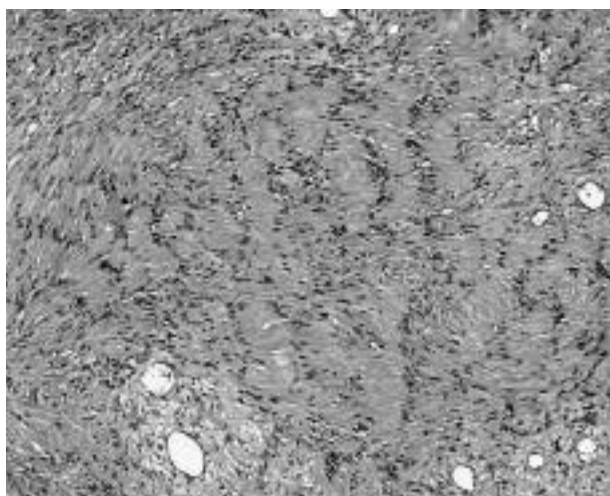
Because of the location of the tumour, it was decided to perform a two-stage surgery with intraleisional tumour resection. First, a retroperitoneal route was used. Anterior to the sacrum, a reddish brown, encapsulated mass was identified eccentric to the left side, which infiltrated a large proportion of the left sacrum without invading the left sacroiliac joint. The tumour also invaded the right sacrum beyond the midline. The tumour originated from the first sacral nerve root. Dissection was carried out around the tumour to isolate it from the surrounding structures. S1 and S2 bodies were totally resected. The defect was reconstructed with 3 curved titanium mesh cages filled with cancellous allograft bone. One week after the anterior procedure, a posterior approach was performed. The dorsolumbar spine and the sacrum were exposed via a midline incision. The sacral canal was unroofed, and lumbar laminectomies were performed. The isolated tumour was exposed. En bloc resection of the tumour with the left S1 nerve root was performed. Posterior instrumentation and fusion with spinopelvic fixation was performed (fig 3).

Histological examination of the resected specimen revealed that the greatest portion of the tumour was composed of interlacing bundles of elongated cells with spindle-shaped nuclei, diagnostic of a benign schwannoma (fig 4).

The postoperative neurological examination showed transient weakness and slight numbness in the left limb, which improved spontaneously. Bladder and bowel dysfunction were not noted. There were no wound healing problems and no infections. The patient was mobilized on the second postoperative day, and discharged after 15 days. Follow-up consisted of routine radiographs every 6 months. The patient was last reviewed 2 years after operation. Conventional anteroposterior and lateral X-ray views of the lower lumbar vertebrae and sacrum showed the lumbosacral arthrodesis with no changes in the alignment and no recurrence (fig 5). The patient is now free of any complaint, complications and recurrence two years after the resection of the schwannoma.



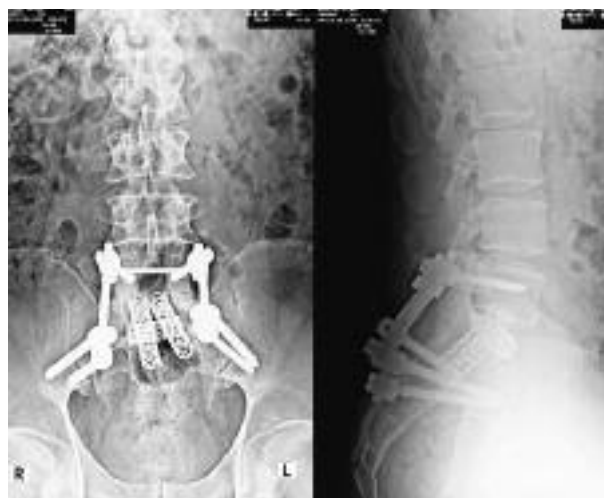**Fig. 3.** — Postoperative anteroposterior and lateral radiographs of the patient.



**Fig. 4.** — Histological examination of the resected specimen revealed that the greatest portion of the tumour was composed of interlacing bundles of elongated cells with spindle-shaped nuclei, diagnostic of a benign schwannoma.

## DISCUSSION

Schwannomas, also known as neurilemmomas are benign tumours arising from peripheral nerves and spinal nerve roots. They are sometimes described as giant because of their size. After bony invasion of the sacrum, these tumours expand ventrally and dorsally and may compress adjacent healthy tissues. Schwannomas are solid and well circumscribed, encapsulated masses. Large schwannomas (> 8 cm) often undergo cystic degeneration



**Fig. 5.** — Conventional anteroposterior and lateral X-ray views of the lower lumbar vertebrae and sacrum showing the lumbo-sacral arthrodesis with no changes in the alignment or recurrence.

due to necrosis or haemorrhage (18). Neither tumour size nor mitotic activity has been found to reflect malignant behaviour (7) yet schwannomas may erode into adjacent bony structures (19).

Our patient's symptoms had been present for two years ; he complained mainly of mild back pain and sciatica. His symptoms worsened during the last two months and paresthesia and numbness became the primary complaints. The sudden change and exacerbation of symptoms in this patient can be related with growth of the tumour and invasion of the healthy surrounding tissues.

CT and MRI scans confirm the presence of the tumour and provide valuable information about its exact anatomic location in relation to the spinal roots, the sacral canal and adjacent viscera (2). There are no specific radiological features associated with schwannomas, but the following findings are highly suggestive : a well-demarcated round or oval mass with heterogeneous contrast enhancement due to cystic and haemorrhagic changes (3) ; presence in the region of a known nerve ganglion or pathway ; calcification and cystic change in a large tumour (11) ; iso-or slightly hyperintense signal intensity on T1-weighted images compared with muscle, and high signal intensity on T2-weighted images (9,23).

Differential diagnoses of sacral masses include a wide variety of pathologies (6,13,16), malignant or benign. Benign bone lesions such as osteoblastoma, aneurysmal bone cyst and giant cell tumour occur infrequently in the sacrum. The first two tumours are usually seen in the posterior elements, lamina and pedicles. Giant cell tumours originate from vertebral bodies but usually are not associated with a sclerotic rim. In our patient, a sclerotic rim was confirmed by CT. This rim around a soft tissue mass suggests a benign-aggressive soft tissue tumour rather than a primary bone tumour.

Malignant tumours in this region include metastatic carcinoma, myeloma, chordoma and chondrosarcoma. The long-standing symptoms of the patient excluded metastatic carcinoma and myeloma. Low-grade chordomas and low-grade chondrosarcomas occur in this location, but MRI images show typical signal changes due to the myxoid matrix produced by these tumours.

Treatment options for giant sacral schwannomas differ according to the individual features of the tumour. The largest series of sacral schwannomas was reported by Abernathy *et al* (1). They performed intralesional excision in 13 cases. Because of the high local recurrence rate of sacral schwannoma in their report, some authors have advocated wide excision and total sacrectomy (14,20-22). The morbidity of this operation is high and reconstruction after total sacrectomy is very challenging. Preoperative embolisation is a valuable primary and adjunctive treatment option for many sacral tumours. Closer collaboration between the surgeon and the oncologist will lead to wider use of embolisation techniques, thereby improving the treatment of sacral tumours, but preoperative embolisation was not used in our patient. No local recurrence was seen at the latest follow-up, two years after intralesional excision of the tumour.

In the current case, we performed a staged combined circumferential approach, because of the localisation and extent of the tumour. A pararectal retroperitoneal approach was used for anterior access. After freeing of vascular and other visceral structures, the tumour was completely removed with surrounding margins, the sacrum was thoroughly curetted and the defect was reconstructed

with titanium mesh cages (TMC) combined with anterior fusion. TMCs are now used more frequently, because they provide more mechanical stability than auto- or allografts. Through the posterior approach, spinopelvic fixation was used to augment the fixation stability.

The desirable extent of resection remains debated. Some authors advocate complete surgical excision which may include adjacent viscera if necessary to achieve negative soft-tissue margins (9,15). It is their belief that a malignant behaviour of the lesion can never be excluded, and the potential for malignant transformation of retained tumorous tissue, recurrent growth and pain necessitates a more radical excision. The treatment of choice, however, appears to be local tumour excision avoiding unnecessary sacrifice of a functionally important nerves if possible (4,19). The rationale is based on the low rate of local recurrence, even with a portion of the capsule remaining intact, and the rarity of malignant transformation seen with benign schwannomas. Sufficient amounts of blood products should be made available during the surgery because schwannomas are highly vascular and intraoperative blood loss may be substantial.

In conclusion, giant sacral schwannomas are rare tumours and their surgical treatment is challenging because of the complex anatomy of the sacrum. Intralesional excision of the tumour is definitely a less invasive procedure as compared with total or partial sacrectomy. Tumour excision and stabilisation can be accomplished using a combined anterior-posterior approach, while avoiding the high morbidity related with total sacrectomy.

## REFERENCES

1. Abernathy CD, Onofrio BM, Scheithauer B, Pairolo PC, Shives TC. Surgical management of giant sacral schwannomas. *J Neurosurg* 1986 ; 65 : 286-295.
2. Bastounis E, Asimacopoulos PJ, Pikoulis E *et al*. Benign retroperitoneal neural sheath tumours in patients without von Recklinghausen's disease. *Scand J Urol Nephrol* 1996 ; 31 : 129-136.
3. Chui MC, Bird BL, Rogers J. Extracranial and extraspinal nerve sheath tumours : computed tomographic evaluation. *Neuroradiology* 1988 ; 30 : 47-53.
4. Das Gupta TK, Brasfield RD, Strong EW, Hajolu SI. Benign solitary schwannoma. *Cancer* 1993 ; 72 : 513-514.

5. **Enzinger FM, Weiss SW.** *Soft Tissue Tumours.* Mosby, St. Louis (Mo.), 1995.
6. **Feldenzer JA, McGauley JL, McGillicuddy JE.** Sacral and presacral tumors : Problems in diagnosis and management. *Neurosurgery* 1989 ; 25 : 884-891.
7. **Felix EL, Wood D, Das Gupta TK.** Tumours of the retroperitoneum. *Curr Probl Cancer* 1981 ; 6 : 3-18.
8. **Gautier-Smith PC.** Clinical aspects of spinal neurofibromas. *Brain* 1967 ; 90 : 359-394.
9. **Guz BV, Wood DP Jr, Montie JE, Pontes JE.** Retroperitoneal nerve sheath tumours : Cleveland clinic experience. *J Urol* 1989 ; 142 : 1434-1437.
10. **Kato T, George B, Mourier KL.** Intraforaminal neurinoma in the lumbosacral region. *Neurol Med Chir (Tokyo)* 1993 ; 33 : 86-91.
11. **Kinoshita, Naganuma H, Ishii K, Itoh T.** CT features of retroperitoneal neurilemmoma. *Eur J Radiol* 1998 ; 27 : 67-71.
12. **Kotoura Y, Shikata J, Yamamuro T.** Radiation therapy for giant intrasacral schwannoma. *Spine* 1991 ; 16 : 239-242.
13. **Lin PP, Horenstein MG, Healey JH.** Sacral mass in a 56-year-old woman. *Clin Orthop Relat Res* 1997 ; 344 : 333-337.
14. **McCarty CS, Waugh JM, Mayo CW.** The surgical treatment of presacral tumors : A combined problem. *Proc Staff Meet Mayo Clin* 1952 ; 27 : 73-75.
15. **Miller PL, Tessler A, Alexander S, Pinck BD.** Retroperitoneal neurilemmoma. *Urology* 1978 ; 6 : 619-623.
16. **Ortolan EG, Sola CA, Gruenberg MF, Carballo Vazquez F.** Giant sacral schwannoma. A case report. *Spine* 1996 ; 21 : 522-526.
17. **Rasmussen TB, Kernohan JW, Adson AW.** Pathologic classification, with two surgical considerations of intraspinal tumors. *Ann Surg* 1940 ; 111 : 513-530.
18. **Rattier B, Desrousseaux B, Dereux HJ, Atat I, Ampe J.** [Benign retroperitoneal pelvic schwannomas. A study of two cases.] (in French). *J Chir (Paris)* 1990 ; 127 : 209-212.
19. **Regan JF, Juler GL, Schmutzer KJ.** Retroperitoneal neurilemmoma. *Am J Surg* 1977 ; 134 : 140-145.
20. **Santi MD, Mitsunaga MM, Lockett JL.** Total sacrectomy for a giant sacral schwannoma. A case report. *Clin Orthop Relat Res* 1993 ; 294 : 285-289.
21. **Stener B, Gunterberg B.** High amputation of the sacrum for extirpation of tumors : principles and technique. *Spine* 1978 ; 3 : 351-354.
22. **Takeyama M, Koshino T, Nakazawa A et al.** Giant intrasacral cellular schwannoma treated with high sacral amputation. *Spine* 2001 ; 15 : E216-219.
23. **Verstraete KL, Achten E, De Schepper A et al.** Nerve sheath tumors : evaluation with CT and MR imaging. *J Belge Radiol* 1992 ; 75 : 311-320.