



Aneurysmal bone cyst of the scapula A case report

Panagiotis MEGAS, Zafiria G. PAPATHANASSIOU, George KASIMATIS, Dionysios J. PAPACHRISTOU

From the University Hospital, Patras, Greece

Aneurysmal bone cyst (ABC) is an uncommon, benign but locally destructive bone lesion of unknown origin. Differential diagnosis can be challenging as it shares common radiological and pathological features with other benign and malignant bone lesions. The degree of diagnostic difficulty grows even more when an unusual location has to be taken into account.

We report a rare and challenging case of a large primary ABC located at the scapula of a young male, who was surgically treated with subtotal removal of the scapula.

Keywords : scapula ; aneurysmal bone cyst.

INTRODUCTION

Despite a long experience of more than 60 years with aneurysmal bone cysts (ABCs) their aetiology, natural course and optimal treatment still remain controversial (15). "Classically" the lesion has been regarded as a post-traumatic and/or reactive process. However, recent molecular genetic studies have demonstrated *USP6* oncogene rearrangements in primary ABCs, implying a neoplastic basis for this lesion (3,14,17-18). ABC was first described as an individual entity by Jaffe and Lichtenstein in 1942 ; it accounts for 1%-2% of all primary bone tumours (4,10). ABC can be either primary or secondary. The latter co-exists with other osseous lesions such as chondroblastoma, giant cell tumour, osteosarcoma, in 30% of cases (3-4). Most common-

ly, ABCs involve skeletally immature patients under the age of 20 years (80%) with a slight female predominance (13,15-16). They can be encountered in any bone but there is a clear predilection for the metaphyses of long tubular bones (femur : 22%, tibia : 17%, humerus : 10%) followed by the spine (12%) and pelvis (9%) (1,4). The scapula is a rare site for this lesion to develop and to the best of the authors' knowledge only few cases of scapular ABCs have been reported in the literature either in multicentric studies ($\leq 2,5\%$) or as sporadic reports (6,7,9,10-12,15,19-21).

We describe a rare case of a large primary scapular aneurysmal bone cyst effectively treated with subtotal removal of the scapula, discuss the most prominent radiological and histopathological

-
- Panagiotis Megas, MD, PhD, Associate Professor.
 - George Kasimatis, MD, Orthopaedic Surgeon.
Orthopaedic Clinic, University Hospital of Patras, Greece.
 - Zafiria G. Papathanassiou, MD, Radiologist.
Radiology Department, University Hospital of Patras, Greece.
 - Dionysios J. Papachristou, MD, PhD, Assistant Professor.
Department of Anatomy-Histology-Embryology, University of Patras, School of Medicine ; Assistant Professor (Adjunct) Department of Pathology, University of Pittsburgh Medical Center, Pittsburgh, PA, USA.

Correspondence : Dr Zafiria Papathanassiou, Polikastis 21b, Patras 26442, Greece. E-mail : papaze@otenet.gr

© 2009, Acta Orthopædica Belgica.

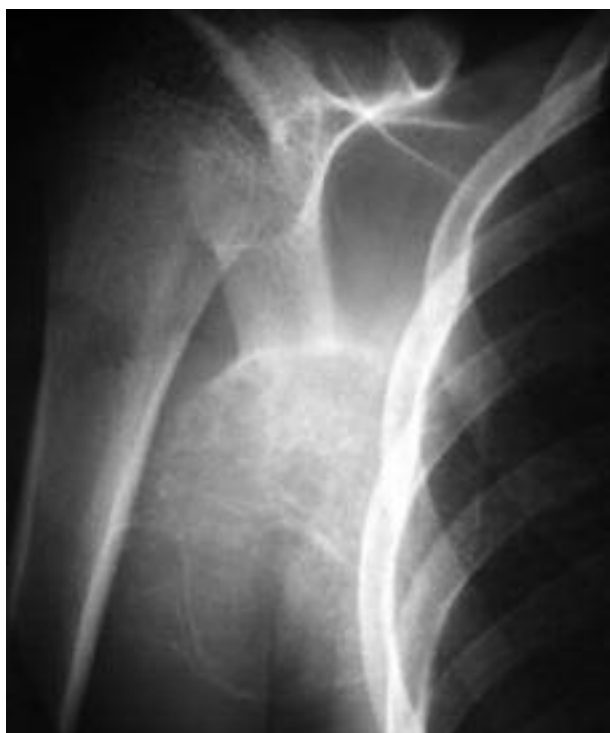

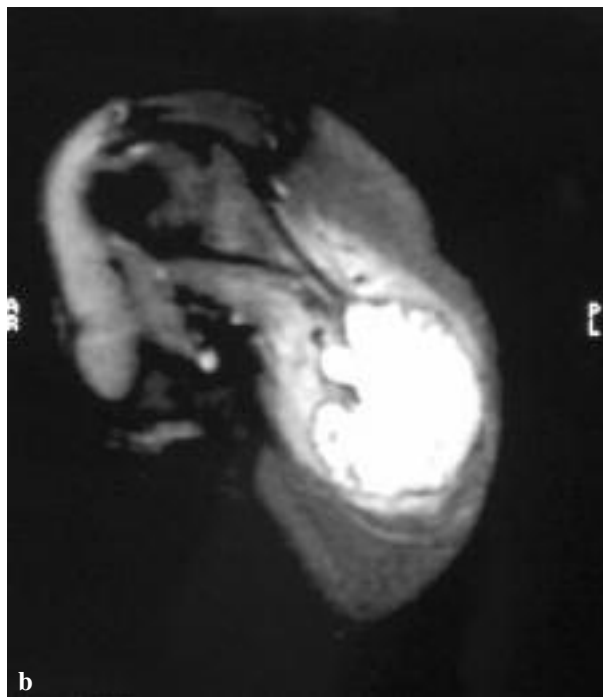
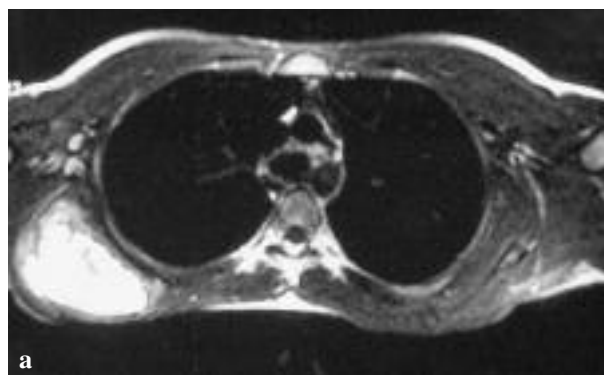
Fig. 1. — Anterior-Posterior radiograph exhibiting a large osteolytic lesion with a thin cortical margin located at the lower region of the right scapula.

characteristics and comment on current curative methods.

CASE REPORT

A 15-year old male presented with a large swelling in the region of the right scapula that had been increasing in size progressively over the past two years. He reported pain and tenderness over the affected area over the past six months. No history of trauma or infection was mentioned. Physical examination revealed a mildly tender, large, firm mass located at the lower half of the scapula. Slight movement restriction of the shoulder was also noted. No axillary or cervical lymph nodes were palpable.

Plain radiographs showed a huge expansile lesion located at the lower part of the scapula, displaying multicystic and sclerotic changes. Neither cortical erosion nor signs of fracture were noted



Figs. 2a, b. — MRI Images : T2 Spin Echo and T2 with Fat Saturation images confirm the cystic nature of the lesion. Notice the multiple fluid-fluid levels contained within its loculations.

(fig 1). MR images showed evidence of a large multi-loculated lesion containing septations with multiple fluid-fluid levels (fig 2a, b). Its maximum diameter was 9.5 cm. The lesion had low to intermediate signal intensity on T1-, and high signal intensity on T2-weighted images. The bony margins of the lesion were thin but well defined. Intense contrast uptake of the septa was additionally noted. Surrounding soft tissues showed no abnormalities (fig 3a, b, c). The above mentioned imaging

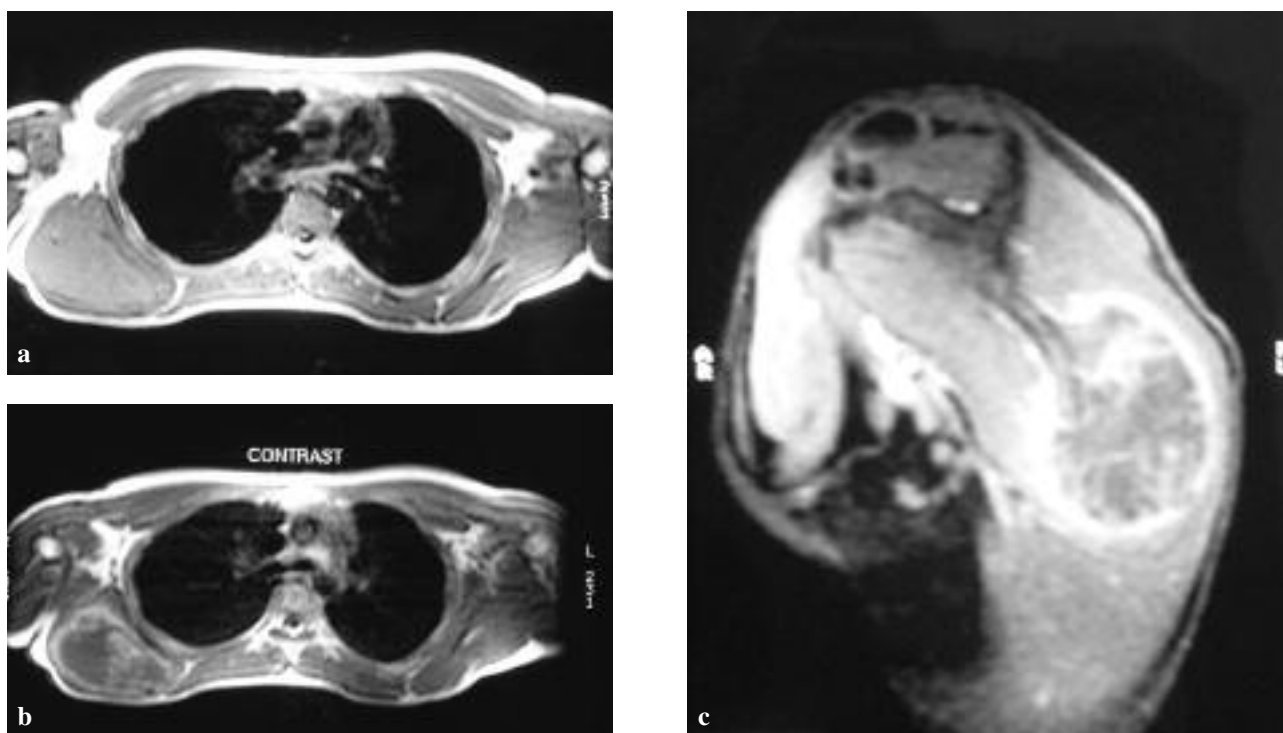


Fig. 3a, b, c. — MRI Images : On pre-contrast T1 Spin Echo images the lesion shows intermediate signal intensity. The periphery of low intensity corresponds to a thin and intact “shell”. Post contrast T1 SE and T1 with Fat Saturation images demonstrate marked marginal enhancement. Internal septations are better delineated on post-contrast images.

features were highly suggestive of a benign, cystic but locally invasive process. The differential diagnosis included mainly ABC and to a lesser degree giant cell tumour and chondromyxoid fibroma.

This case was managed by orthopaedic surgeons and radiologists specialized in musculoskeletal oncology. It was decided to proceed to surgical treatment without making a preliminary biopsy. First of all, as previously mentioned, the imaging features of the lesion were not indicative of malignancy. In addition, because of the large size of the tumour as well as because of the overlapping histological characteristics of the lesions included in the panel of differential diagnosis, we presumed that biopsy would be associated with an increased possibility of obtaining inadequate or non-specific material for accurate pathologic evaluation.

At operation, the scapula was exposed through an inverted L-shaped incision. All muscles attached to the back of the scapula were carefully separated

subperiosteally and a complete wide resection of the lesion was performed, resulting in subtotal removal of the scapula.

Gross examination of the resected specimen revealed a large, well circumscribed, haemorrhagic cystic mass that contained fibrous septa and spicules of bone. No macroscopic features of malignancy were evident. Histological examination showed a large cystic lesion composed of blood-filled cystic spaces, separated by fibrous septa. Additionally, reactive woven bone, rimmed by activated osteoblasts and numerous multinucleated giant cells along with haemosiderin deposits could be easily identified (fig 4). These histopathologic features suggested the diagnosis of an ABC.

After excision, the recovery was swift and uneventful. Full range of shoulder motion was regained, with only slight deformity. At the 4-year MRI follow-up, no evidence of local recurrence was noted (fig 5a, b).

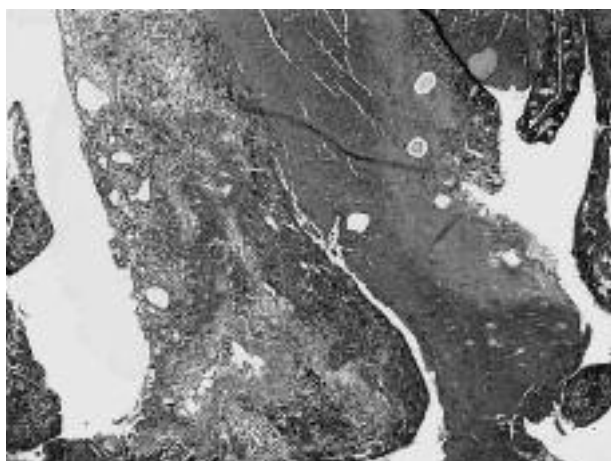
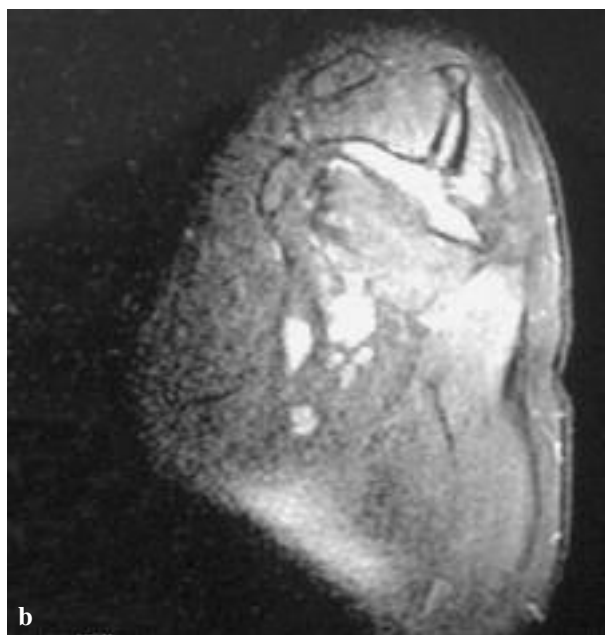
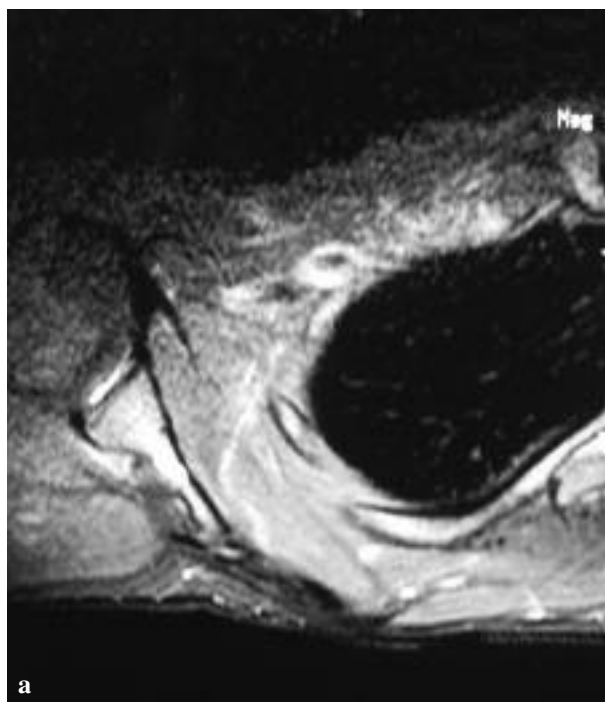


Fig. 4. — Histology : Histopathologic evaluation of the lesion revealed blood-filled cystic spaces. Numerous multinucleated giant cells and spicules of reactive bone were evident (Haematoxylin & Eosin, original magnification $\times 4$).

DISCUSSION

Herein, we describe a case of a large ABC situated in the scapula of a 15 year-old male. This case is interesting because tumours of the scapula are rare and usually malignant (22). Indeed, two studies from referral centers for musculoskeletal oncology have reported that the vast majority of the scapular tumours in their series were malignant. Both malignant and benign scapular lesions usually affect children and young adults ; unfortunately in most instances radiological findings are not sufficient to allow for a safe diagnosis (22). To the best of our knowledge only eight cases of scapular ABCs have been described in literature over the past few decades (7,9,11,12,19-21). A demographic study from 150 ABCs presented by Mankin *et al* (14) reported that scapular ABCs were encountered in only 3 patients of their series (2%). In line with these data, De Silva *et al* reported 2 cases of scapular ABCs (2.3%) in a total of 86 lesions (5).

Generally, ABCs present with pain and swelling of relatively rapid progression. In 72% of cases, the period between onset of symptoms and treatment is 6 months or less (1). Symptoms related to compression of adjacent structures may occasionally be present (1,8,15-16).



Figs. 5a, b. — Follow-up Images : Proton Density with Fat Saturation axial and sagittal planes (4 years post surgery) show no evidence of recurrence.

Radiographically, these lesions most commonly appear expansile, lytic, eccentrically located, with “soap-bubble” appearance and outlined by a thin

rim of subperiosteal bone. CT scans demonstrate multiloculations, define the bony extent of the lesion and detect possible fractures. MR imaging verifies the expansile nature of the cyst containing septa and fluid-fluid levels. Furthermore, valuable information concerning soft tissue alterations and intramedullary extension is provided (8,16).

Differential diagnosis includes mainly giant cell tumour, chondromyxoid fibroma and telangiectatic osteosarcoma (8). Distinction between these entities can be quite difficult, but the accurate evaluation of age of presentation, location of the lesion, progression rate and histological features contributes greatly to the diagnosis.

Management of ABCs depends upon age, location, extent and aggressiveness of the lesion. Although controversy exists regarding the optimal treatment, a certain degree of consensus has recently emerged : for stage I (according to the Enneking surgery staging system) inactive lesions that have a well-defined cortex, careful monitoring is recommended. Occasionally, these lesions heal completely after curettage. Intervention is needed in cases of pain or increase in size. For active or aggressive lesions (stage II-III) that present with incomplete periosteal rim, indefinite borders and osteolysis, surgical treatment will depend on tumour location. Complete surgical excision is the preferable choice but it is not always feasible. Technical difficulties primarily related to the complex anatomy of the affected area may cause severe functional impairment. Marginal en-bloc resection is recommended for eccentric lesions or for lesions within bones such as fibula, clavicle, scapula and ribs as in our case. In these patients there is little morbidity and minimal risk of recurrence. When the location of the cyst is a limitation (e.g. pelvis, spine or in proximity to an open growth plate), treatment is usually by curettage with bone grafting. Related recurrence rate within 6 to 24 months after the surgery, remains high (20%-70%) especially in children and in stage III-aggressive lesions (3-4,8,16).

Alternatively, non operative methods like selective arterial embolisation, demineralised bone particles or Ethibloc injection (except for spinal lesions) have been recently introduced for the treatment of extensive ABCs with difficult approach or in cases

of post surgical relapse, with encouraging initial results. However, these methods are technically demanding, are not free of complications and may not be available in all centers. Radiation therapy is reserved for aggressive, partially resected and/or recurrent lesions but is associated with considerable risk of axial deformation and radiation induced malignancy (3-4,8).

ABC is an enigmatic lesion in terms of aetiology and pathogenesis and sometimes it is difficult to be distinguished from other benign or malignant lesions solely based on radiology. Its benign nature should not obscure its local aggressiveness. Even though ABC of the scapula is rare, it should be suspected among other possible diagnoses, when a scapular swelling is encountered. Clinical data, combined with imaging and histopathologic findings are the cornerstone of the accurate diagnosis prior to any intervention. In the vast majority of the cases, including ours, surgical treatment is generally satisfactory ; nevertheless newer minimally invasive techniques will contribute considerably as alternative and effective therapeutic solutions in the management of extensive lesions with complex anatomy, where conventional surgical approaches might be hazardous.

REFERENCES

1. **Campanacci M, Cappana R, Picci P.** Unicameral and aneurysmal bone cyst. *Clin Orthop Relat Res* 1986 ; 204 : 25-36.
2. **Chadha M, Singh AP.** Aneurysmal bone cyst of the clavicle. *J Can Chir* 2008 ; 51 : 32-33.
3. **Cottarolda J, Bourelle S.** Modern concepts of primary aneurysmal bone cyst. *Arch Orthop Trauma Surg* 2007 ; 127 : 105-114.
4. **Cottarolda J, Bourelle S.** Current treatments of primary aneurysmal bone cysts. *J Pediatr Orthop* 2006 ; 15-B : 155-167.
5. **de Silva MV, Raby N, Reid N.** Fibromyxoid areas and immature osteoid are associated with recurrence of primary aneurysmal bone cysts. *Histopathology* 2003 ; 43 : 180-188.
6. **Frank A, Slowick Jr, Crawford J et al.** Aneurysmal Bone Cyst : An analysis of thirteen cases. *J Bone Joint Surg* 1968 ; 50-A : 1142-1151.
7. **Haber HP, Drews K, Scheel-Walter H, Klingebiel T.** Aneurysmal bone cyst in early childhood. Ultrasound findings. *Pediatr Radiol* 1993 ; 23 : 405-406.

8. **Hresko MT, Miele JF, Goldberg MJ.** Unicameral bone cyst in the scapula of an adolescent. *Clin Orthop Relat Res* 1988 ; 236 : 141-144.
9. **Gold RH, Mirra JM.** Case report 234. Aneurysmal bone cyst of left scapula with intramural calcified chondroid. *Skeletal Radiol* 1983 ; 10 : 57-60.
10. **Jaffe HL, Lichtenstein L.** Solitary unicameral bone cyst : With emphasis on the roentgen picture, the pathologic appearance and the pathogenesis. *Am Surg* 1942 : 1004-1025.
11. **James ES.** Subtotal removal of the scapula for aneurysmal bone cyst. *J Bone Joint Surg* 1957 ; 39-B : 128-130.
12. **Kaila R, Ropars M, Briggs TW, Cannon SR.** Aneurysmal bone cyst of the paediatric shoulder girdle : a case series and literature review. *J Pediatr Orthop* 2007 ; 16-B : 429-36.
13. **Leithner A, Machacek F, Lang S et al.** Aneurysmal bone cyst. A population based epidemiologic study and literature review. *Clin Orthop Relat Res* 1999 ; 363 : 176-179.
14. **Leithner A, Machacek F, Haas OA et al.** Aneurysmal bone cyst : a hereditary disease ? *J Pediatr Orthop* 2004 ; 13-B : 214-217.
15. **Mankin HJ, Hornicek FJ, Ortiz-Cruz E, Villafuerte J, Gebhardt MC.** Aneurysmal bone cyst : a review of 150 patients. *J Clin Oncol* 2005 20 ; 23 : 6756-6762.
16. **Mendenhall WM, Zlotecki AR, Gibbs CP et al.** Aneurysmal bone cyst. *Am J Clin Oncol* 2006 ; 29 : 311-315.
17. **Oliveira AM, Perez-Atayde AR, Inwards CY et al.** USP6 and CDH11 oncogenes identify the neoplastic cell in primary aneurysmal bone cysts and are absent in so-called secondary aneurysmal bone cysts. *Am J Pathol* 2004 ; 165 : 1773-1780.
18. **Panagopoulos I, Mertens F, Löfvenberg R, Mandahl N.** Fusion of the *COL1A1* and *USP6* genes in a benign bone tumor. *Cancer Genet Cytogenet* 2008 ; 180 : 70-73.
19. **Pullan CR, Alexander FW, Halse PC.** Aneurysmal bone cyst : a report of three cases. *Arch Dis Child* 1978 ; 53 : 899-901.
20. **Ruggieri M, Milone P, Smilari P et al.** Aneurysmal bone cyst of the acromion : a case report. *Pediatr Radiol* 1995 ; 25 Suppl 1 : S147-9.
21. **Tandogan R, Hucumenoglu S, Benli T, Aydin E, Yüçeturk A.** Unusual causes of scapular clicking. Lymphangioma of the thoracic wall and aneurysmal bone cyst of the scapula. *Arch Orthop Trauma Surg* 1997 ; 116 : 516-518.
22. **Zvekotkina LS, Kuznetsova IP, Lipovich MM.** [Case of an aneurysmal cyst of the scapula.] (in Russian). *Vestn Rentgenol Radiol* 1971 Sept ; 46 : 99-101.