



## Combined syringe cement pressurisation and intra-osseous suction : An effective technique in total knee arthroplasty

Jon J. MATTHEWS, Luke BALL, Stephen M. BLAKE, Peter J. COX

*From the Princess Elizabeth Orthopaedic Centre, Royal Devon and Exeter Hospital, Exeter, United Kingdom*

Our study looked at the short and medium-term results of a cost-effective technique of bone surface preparation and cement introduction in total knee arthroplasty (TKA). Numerous factors determine the outcome following TKA. Early failure and component loosening have been attributed to inadequate bone-cement and prosthesis-cement interfaces, established at the time of surgery. Various operative techniques have been reported to achieve effective cement penetration and inter-digitation into cancellous bone, with techniques of cement pressurization and intra-osseous suction being employed. We have devised a technique of cement pressurization using a modified standard 20 ml syringe, combined with intra-osseous suction. Retrospective evaluation of a series of 50 post-operative radiographs has shown that effective and even penetration of cement to a depth of 8.0 to 10.6 mm can be achieved consistently with this technique, during TKA, without the use of tourniquet. In addition evaluation of post-operative plain radiographs with minimum follow-up of 5 years showed 16 knees with minor, non-progressive lucent lines around the tibial component with a maximum Knee Society TKA Roentgenographic score of 2. To conclude we propose that this simple technique of surface preparation and cement introduction produces good results in the short and medium-term.

**Keywords :** total knee arthroplasty ; cement pressurization ; intra-osseous suction.

### INTRODUCTION

The long-term survival of a cemented total knee arthroplasty (TKA) depends on a number of factors including accurate soft tissue balancing, limb realignment, implant choice and design and the patient's activity level. Achieving an adequate bone-cement and prosthesis-cement interface is also extremely important, and poor cementing technique results in reduced shear strengths (3) and early failure.

The bone-cement interface is optimized by thorough lavage, complete coverage with cement, minimal blood contamination and reduced intramedullary bleeding pressure (4). During hip arthroplasty the optimal cement-bone interface shear strength is achieved by exposing and cleaning strong cancellous bone, followed by the drying of bone surfaces with hydrogen peroxide and pressurizing low-viscosity cement onto the prepared

- 
- Jon J. Matthews FRCSEd (Tr&Orth), Specialist Registrar.
  - Luke Ball, MRCS, Senior House Officer.
  - Stephen M. Blake, FRCS (Tr&Orth), Specialist Registrar.
  - Peter J. Cox FRCS (Tr&Orth), Consultant.

Correspondence : Jon Matthews, 48 Station Road, Horrabridge, Yelverton, Devon PL20 7SS, United Kingdom.

E-mail : jonjmatthews@googlemail.com

© 2009, Acta Orthopædica Belgica.

surface to overcome bleeding pressures (3). The sealed confines of the femoral canal or acetabulum aid pressurisation, unlike the flat cut surfaces encountered during total knee arthroplasty. In addition, the potential advantages of operating without a tourniquet have been discussed by several authors. In higher risk patients such as the obese, those with peripheral vascular disease, poor-quality skin or rheumatoid patients, there are distinct benefits to avoiding the use of a tourniquet (1,6).

However, the ability to achieve a clean, dry bone surface during implant cementation has been the cause of concerns without the use of a tourniquet. For these reasons, several techniques have been described to improve bone surface preparation in total knee arthroplasty. Superficial cement penetration can be ensured with cement impactors (8) but these instruments are expensive and may increase the incidence of fat embolism. Bone surface preparation using pressure lavage to clean the bone and metaphyseal cancellous bone suction to optimise cement penetration via a Wolf needle, reduces the risk of fat embolism and bleeding pressure but can lead to excessive local cement penetration (5). The method described has previously been described (2) and has the advantages of both techniques but costs the fraction of commercially available cement guns.

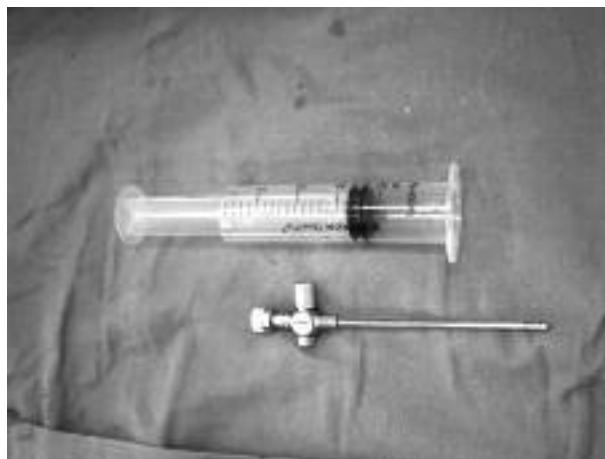The short and medium-term results of a cost-effective technique of bone surface preparation and cement introduction using a modified 20 ml syringe for cement pressurisation and a Wolfe cannulated needle for intra-osseous suction are reported (fig 1).

## PATIENTS AND METHODS


### Operative technique

All operations were performed by the same surgeon, using the AGC total knee arthroplasty. A tourniquet was not used. The femoral and tibial cuts were made and the bone thoroughly lavaged and then dried with hydrogen peroxide soaked swabs (fig 2).

A Wolf cannulated needle was then inserted in the proximal tibial metaphysis, below the prepared surface and in a position which would not interfere with the tibial component insertion (fig 3). Two 20-ml syringes had their plungers removed, their distal ends cut off and the plungers re-inserted the wrong way round. Cement

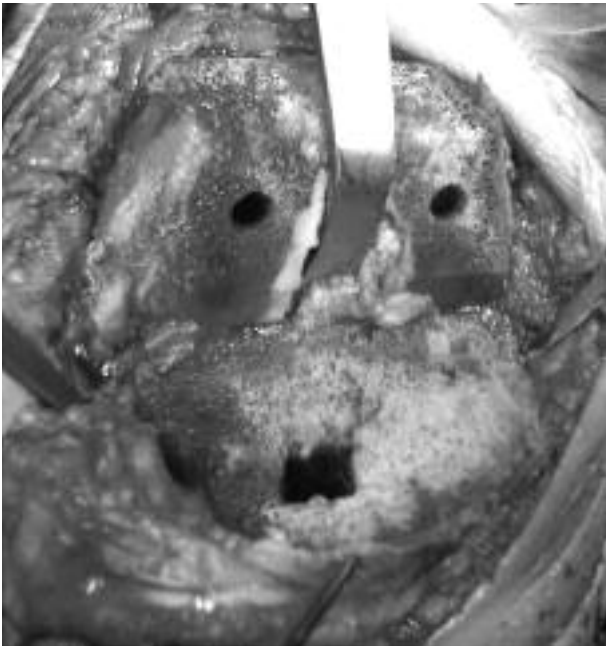


*Fig. 1.* — Modified standard 20 ml syringe with Wolf cannulated needle.

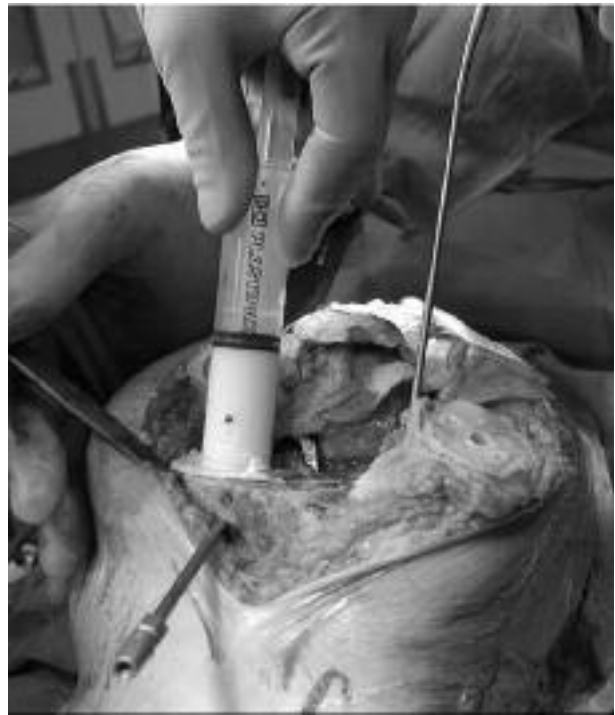

*Fig. 2.* — Prepared bone surfaces prior to cementing in prosthesis.

was drawn into the syringes whilst the viscosity was still low. One syringe was used for the tibial surface and one for the femoral and patellar surfaces. The syringes were firmly pressed against the bone surfaces with the hub acting as a flange. The collar of the syringe acted as a seal to prevent cement extrusion so that when the plunger was pressed, pressure forced cement into the prepared cancellous surface (fig 4). This focal pressurisation process was then repeated over the entire surface of the tibia. Finally, a mantle of cement was applied on top of the pressurized cement (fig 5) and the suction was turned on to pull the cement down the hole prepared in the tibia (fig 6). The suction was then switched off once the prosthesis was inserted to prevent over penetration of the



*Fig. 3.* — Prepared tibial surface with Wolf needle in position.



*Fig. 4.* — The syringe is firmly pressed against the bone surface with the hub acting as a flange.

cement. The process was repeated on the femoral and patellar surfaces, with the Wolfe needle positioned in either of the femoral surfaces.

This technique can also be utilized when performing unicompartmental knee replacements. The tibial syringe needs to be trimmed differently to allow for the presence of the femoral condyle (fig 7). Excellent cement penetration can be achieved on both the femoral and tibial surfaces.

### **Patients**

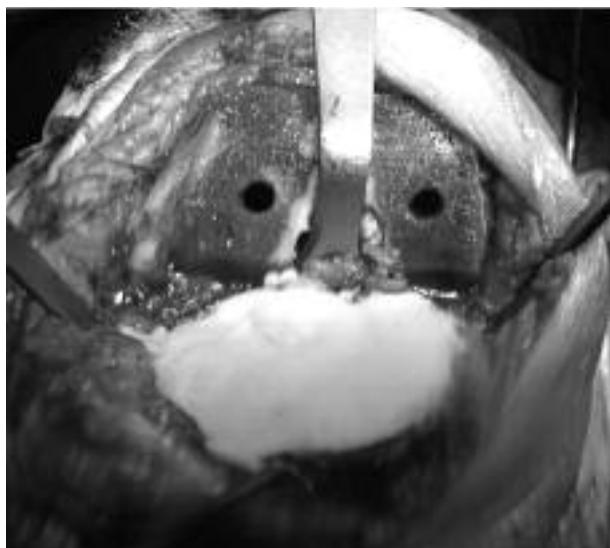
Retrospectively, 50 post-operative anterior-posterior (AP) plain radiographs were reviewed from a series of patients of the same surgeon who had undergone primary TKA using the AGC prosthesis. All procedures had been carried out without the use of a tourniquet. All patients had a diagnosis of osteoarthritis prior to their surgery. To overcome any potential biases, patients with rheumatoid arthritis, significant bone loss on the tibial plateau with marked deformity, cystic erosions and severe osteoporosis noted on preoperative radiographs were not included in the study group. Cement penetration was measured in six positions (four points across the tibial plateau, and

single points medial and lateral to the mid-point of the stem of the tibial component (fig 8). To account for imperfect AP projections where the tibial tray has an elliptical appearance, measurements were taken from a horizontal line through the most medial and lateral points of the ellipse.

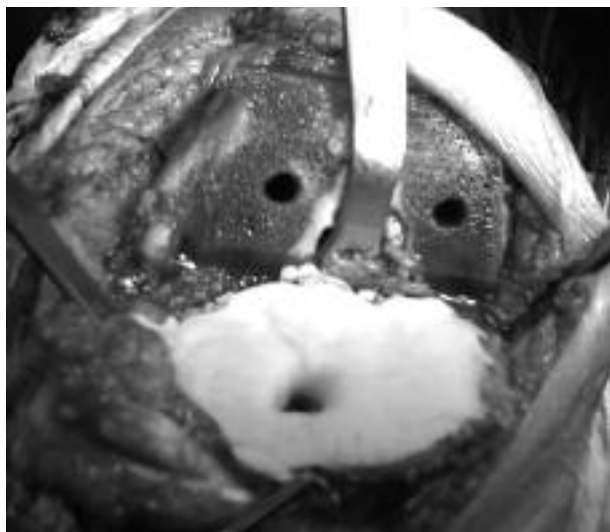
Subsequently the follow-up AP radiographs were reviewed with a minimum radiological follow-up of five years (61 months) and range of follow-up of 61 to 96 months. Forty-one radiographs were reviewed, as nine arthroplasties were lost to follow-up due to the radiographs being destroyed. All radiographs were scored on the tibial components using the Knee Society Roentgenographic Score.

### **RESULTS**

During analysis of 50 post-operative AP radiographs, data were recorded for each of the six measurement positions. Measurements of cement penetration immediately beneath the tibial base plate (positions 1,2,3,4) showed reliable cement penetration across the entire width of the tibial plateau. The

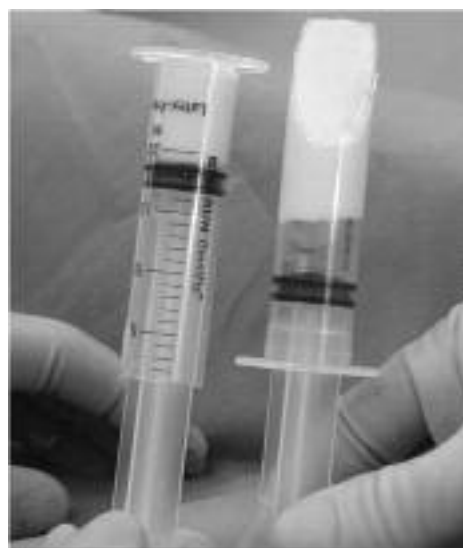

*Fig. 5.* — A mantle of cement is applied on top of the pressurized cement.



*Fig. 6.* — The suction is switched on to draw the cement into the hole prepared on the tibia.

mean depth of cement penetration in this area ranged between 8.0-10.6 mm with a mean of 9.3 mm. Mean depth of cement penetration either side of the stem of the tibial component (positions 5 & 6), was 2.9 mm (range 0-6 mm) medially and 1.3 mm (range 0-4 mm) laterally. We attribute this variance to the positioning of the suction device on the medial side of the tibia in the majority of cases



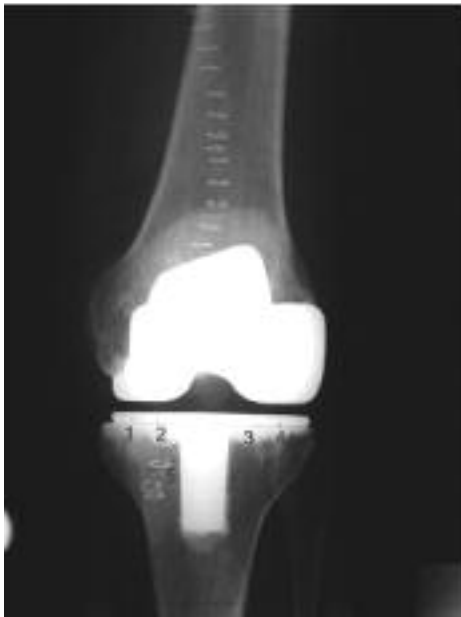*Fig. 7.* — Syringe for total knee arthroplasty on the left and modified syringe for use in unicompartmental knee arthroplasty on the right.

due to increased sclerosis of this region in medial compartment osteoarthritis.

The maximum Knee Society Total Knee Arthroplasty Roentgenographic Score was 2 in the follow-up radiographs that were reviewed. Scores of less than 4 with non-progressive lucent lines are considered not significant. One patient in our series had a revision due to mechanical malalignment.

## DISCUSSION

The techniques of pulse-lavage, intra-osseous suction and cement pressurisation are all known to contribute to a satisfactory cement-bone interface, resulting in a reduced incidence of loosening and failure of the tibial component in TKA. It is important that surgical technique achieves uniform penetration of cement into cancellous bone. The optimum depth of cement penetration is reported to be 3 to 4 mm (8), with an increased incidence of loosening with penetration depths lower than this. Various techniques of cement pressurisation have been described, usually employing commercially available cement pressurisation devices (7). Our results demonstrate that effective cement penetration over the entire surface of the tibial plateau can



**Fig. 8.** — Cement penetration measured in six positions across the tibial plateau.

be achieved using a combination of these techniques, with the modified 20 ml syringe functioning as a highly effective pressurisation device.

The medium-term results of this technique are very encouraging, showing the maintenance of a satisfactory bone-cement interface at a minimum follow-up of five years.

In summary, we have found this to be an effective technique, using widely available disposable

syringes, in preference to commercially available cement guns, keeping costs low. We have demonstrated that the technique produces uniform cement penetration across the tibial plateau, and have noted that caution must be taken to avoid excessive penetration in osteoporotic bone.

## REFERENCES

1. **Abdel-Salam A, Eyres KS.** Effects of tourniquet during total knee arthroplasty : a prospective randomized study. *J Bone Joint Surg* 1995 ; 77-B : 250-253.
2. **Blake SM, Cox PJ.** Obtaining an optimal bone-cement interface total knee arthroplasty. *Ann R Coll Surg Engl* 2006 ; 88 : 317-319.
3. **Halawa M, Lee AJC, Ling RSM, Vangala SS.** The shear strength of trabecular bone from the femur, and some factors affecting the shear strength of the bone cement interface. *Arch Orthop Trauma Surg* 1978 ; 92 :19-30.
4. **Majkowski KA, Miles AW, Bannister C, Perkins J, Taylor GJ.** Bone surface preparation in cemented joint replacement. *J Bone Joint Surg* 1993 ; 75-B : 459-463.
5. **Norton MR, Eyres KS.** Irrigation and suction technique to ensure reliable cement penetration for total knee arthroplasty. *J Arthroplasty* 2000 ; 15 : 468-474.
6. **Parmet JL, Horrow JC, Berman AT et al.** The incidence of large venous emboli during total knee arthroplasty without pneumatic tourniquet use. *Anesth Analg* 1998 ; 87 : 439-444.
7. **Ritter MA, Herbst SA, Keating AM, Faris PM.** Radiolucency at the bone-cement in total knee replacement. The effect of the bone surface preparation and cement technique *J Bone Joint Surg* 1994 ; 76-A : 60-65.
8. **Walker PS, Soudry M, Ewald FC, McVickar H.** Control of cement penetration in total knee arthroplasty. *Clin Orthop Relat Res* 1984 ; 182 : 206-210.