



Angiosarcoma around a knee arthroplasty *Report of a case and literature review*

Adrien ALBERT, Louis LOOTVOET, Etienne LEJEUNE, Alain BEUGNIES, Olivier HIMMER

From Clinique Saint-Luc, Bouge, Belgium

The development of periprosthetic malignancy in proximity to an arthroplasty has been a matter of debate since it was first reported in 1978. We report a case of tibial angiosarcoma, an extremely rare malignancy, which developed in proximity to a primary knee arthroplasty performed ten years before. To our knowledge this is the second case ever described around a knee arthroplasty.

While implantation of orthopaedic material can induce the development of malignant tumours in experimental animals, the overall incidence of malignancy recorded following arthroplasty in clinical studies does not appear to be increased compared to the control population.

Each case of periprosthetic malignancy following arthroplasty must receive attention in order to better understand the underlying pathology and to measure the possibility for an increased risk of development of specific cancer types.

Keywords : angiosarcoma ; haemangiosarcoma ; knee arthroplasty ; bone tumour.

arguments to support the hypothesis of an increased risk of malignancy following arthroplasty. We report the case of a haemangiosarcoma which developed in the proximal tibia, ten years after total knee arthroplasty. To our knowledge, only one case of haemangiosarcoma, an extremely rare tumour, has been described so far around a knee arthroplasty (7).

CASE REPORT

An 85-year-old lady presented to the emergency room with pain in her right knee following a fall. She had undergone primary total arthroplasty of her right knee with a cemented posterior stabilized Insall Burstein prosthesis ten years earlier, with a satisfactory functional result. She was in good general health, without any history of malignancy or severe disease. She was treated for atrial fibrillation and high blood pressure. Initial radiographs

INTRODUCTION

The development of a periprosthetic malignancy following implantation of orthopaedic hardware is a rare occurrence but is widely debated in literature. Despite sporadic case reports and the experimental demonstration of the oncogenicity of some constituents of prosthetic components, a causal relationship in the human has not been demonstrated so far. Furthermore, recent cohort studies do not bring

-
- Adrien Albert, MD, Resident in Orthopaedic Surgery.
 - Louis Lootvoet, MD, Orthopaedic Surgeon.
 - Etienne Lejeune, MD, Orthopaedic Surgeon.
 - Alain Beugnies, MD, Orthopaedic Surgeon, Head of Department.
 - Olivier Himmer, MD, Orthopaedic Surgeon.
- Correspondence : Adrien Albert, Rue Saint-Luc, 7, B-5004 Bouge, Belgium. E-mail : a1.albert@belgacom.net
© 2009, Acta Orthopædica Belgica.
-

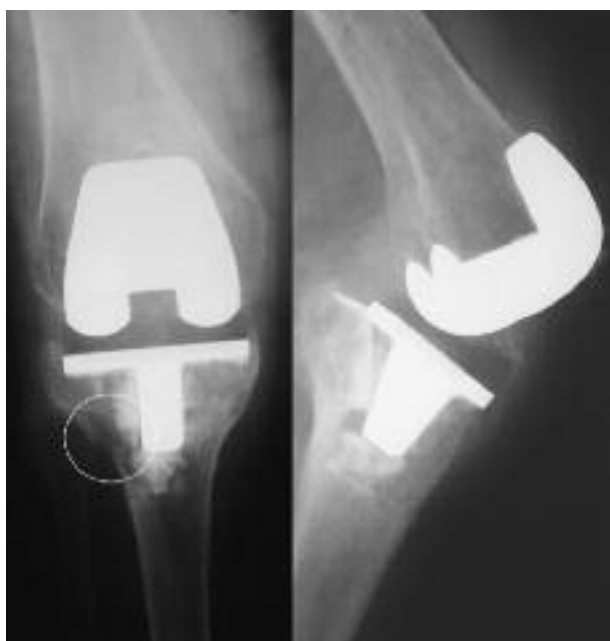

Fig. 1. — Preoperative radiographs showing tibial implant loosening. On careful inspection of the lateral tibial plateau we observe thinning of the cortical bone and cancellous bone rarefaction, suspect of malignancy.

showed anterior tilt and subsidence of the tibial implant (fig 1). The diagnosis of tibial loosening secondary to a traumatic fracture was accepted, and revision of the tibial component was performed four days later. After removal of the implant and bone cement, we observed a complete loss of the cortical bone around the implant, except for the most posterior proximal tibial cortex. Biopsies of the surrounding tissue were sent for histological analysis. A cemented revision tibial component was then implanted, after bone allografting of the defects.

Two pathologists analysed the biopsies and observed dense tumorous cells with regions of necrosis, without any normal tissue left (fig 2a). Immunohistochemistry stains showed positivity for CD31 (fig 2b), and EMA (epithelial membrane antigen) but were negative for other endothelial markers such as CD 34, CD 68 (PGM1), factor VIII-related antigen, and cytokeratin. The biopsies were immunonegative for S100 protein marker, excluding a melanoma. These results demonstrated the endothelial origin of the tumour (17,18). The sug-

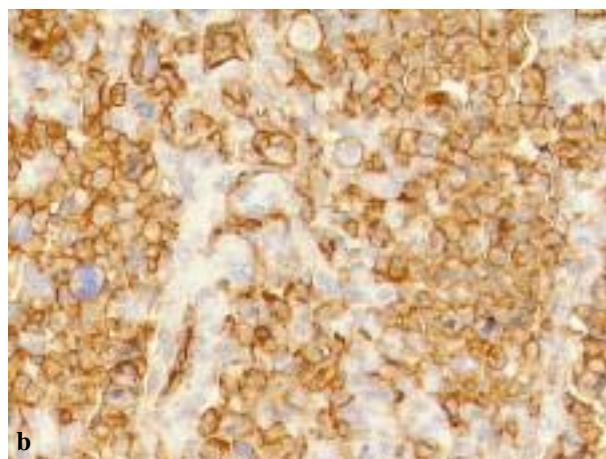
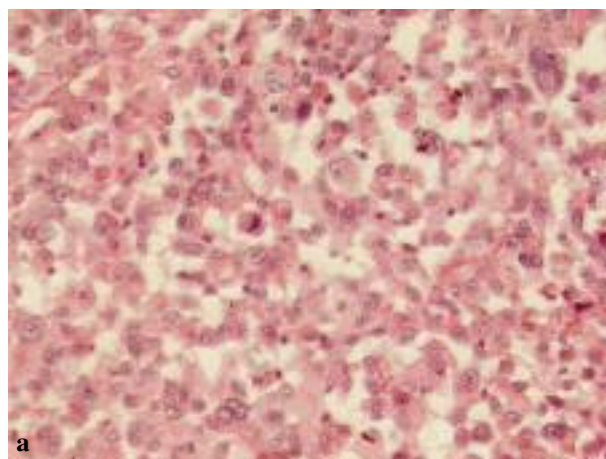


Fig. 2a,b. — Photomicrograph (haematoxylin and eosin) of a biopsy, showing the high grade haemangiosarcoma. High mitotic index, irregular size / shape of cytoplasm and nucleus are signs of malignancy (Fig 2a). The strong positivity of the majority of the neoplastic cells to CD 31 antigens confirmed the presumption of a vascular origin of the lesion (Fig 2b).

gested diagnosis was a high-grade poorly differentiated osseous epithelioid haemangiosarcoma.

The patient rapidly developed extremely painful nodular skin lesions around the scar (fig 3). Echotomography of the leg documented an infiltrative vertical bone lesion of 7 × 2 cm, unsuspected until then. Mid-thigh amputation was performed six weeks after the revision procedure. The histology and immunohistochemistry findings were similar to those previously described.

CT-scan of the thorax showed a middle lingular tumour in the left hemithorax, highly suspect for

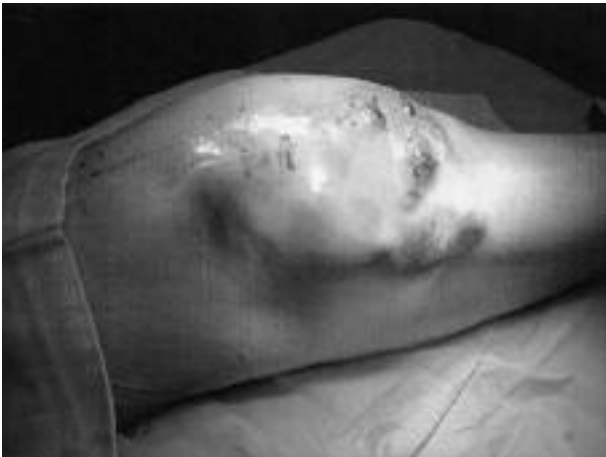

Fig. 3. — Photograph of the knee showing ulcerative nodular skin lesions, six weeks after the revision arthroplasty.

metastasis, with an associated pleural effusion, and a smaller lesion, about 1 cm in diameter, at the base of the right hemithorax. Liver echotomography, abdominal CT-scan, brain CT-scan and TC99m bone scan were negative.

Less than one month later, the patient presented with lymphadenopathies at the medial aspect of the thigh. Biopsy specimens of two lymph nodes showed cells similar to those in the primary lesion. The patient refused further extensive investigations and treatment. She died suddenly one month later.

DISCUSSION

Malignancy development around an orthopaedic implant was first reported in 1956, next to a humeral plate (13), whilst the first case reported following a hip arthroplasty was reported in 1978 (2). To our knowledge, there are now 48 (11,15,23) reported cases of malignant tumours developing in proximity to a hip arthroplasty and only 4 in proximity to a knee arthroplasty (4,7,8,24) (table I).

On the other hand two recent large cohort studies of Finnish and Swedish patients (5,20) following knee arthroplasty showed no periprosthetic malignancy, and the overall cancer risk was not found to be increased. Furthermore, the results of three meta-analyses which included patients who had undergone knee or hip arthroplasty (19,21,22) do not clearly support the existence of a significant oncogenic risk from the components of hip and knee prostheses and their degradation and wear products.

Nevertheless such cases raise the question of the possible role of the orthopaedic implant in sporadic cases of malignant tumours. Experimental studies in rats have shown that implantation of cobalt, chromium, nickel, polyethylene or methylmethacrylate can induce the development of sarcomas (3,10,14). Recently Adams *et al* (1) analysed the trace metal in a high-grade osteosarcoma developed around a total hip prosthesis. Interestingly, they measured higher amounts of vanadium in the

Table I. — Malignant tumours at the site of a knee arthroplasty

	Age (y) / gender	Preoperative diagnosis	Implant	Time interval (y)	Histopathology
Weber <i>et al</i> , 1986 (24)	76 / F	Osteoarthritis with distal femoral enchondroma or bone infarct	Vitallium (Cr/Co/Mo)	5	Epithelioid sarcoma (histiocytoma or fibrosarcoma)
Himmer <i>et al</i> , 1990 (7)	74 / F	Osteoarthritis	Guepar / unknown revision TKA	13	Angiosarcoma
Eckstein <i>et al</i> , 1992 (4)	76 / M	Osteoarthritis	Richards	4	Fibrosarcoma
Iglesias <i>et al</i> , 1994 (8)	76 / F	Rheumatoid arthritis	Unknown (Cr/Co/Mo)	10	Malignant fibrous histiocytoma
<i>current</i> , 2009	85 / F	Osteoarthritis	Insall-Burstein (Cr/Co/Mo)	10	Angiosarcoma

tumorous soft tissue and higher amounts of chromium and vanadium in the tumorous bone, compared to control tissues.

Angiosarcoma, also characterized by most of the authors as haemangiosarcoma or malignant haemangioendothelioma, is a very rare malignancy derived from blood containing vascular endothelium. It accounts for about 2% of all soft tissue sarcomas (6) and less than 1% of primary bone tumours, with a male predominance (16). In a 14 year retrospective review (6), the overall 5 year survival was only 31%. Surgical resection is the only potentially curative treatment and chemotherapy is reserved for unresectable tumours. It mostly affects soft tissues, especially at the head and face, but cases of primary bone angiosarcoma have also been described. Any part of the skeleton may be involved but it mostly affects the proximal tibia, the proximal femur, the proximal humerus and the iliac crest, in some cases around a foreign body. A recent review of the literature on angiosarcoma developed in proximity to a hip arthroplasty only reported four of those cases (11). The current case is the third reported about the knee following foreign body implantation and the second around a knee arthroplasty. The first case was 30 years after using bone wax following graft harvesting (9). The second case was in a 74-year-old lady, 13 years after primary implantation of a total knee prosthesis, which was revised after 7 years (7).

In order to be considered an implant-related malignant tumour, the tumour should occur in the direct vicinity of the implant and develop after at least two years, in absence of recognized predisposing factors such as previous irradiation or chronic infection (12). Although these criteria were met in all three cases reported so far, there is, until now, no explanation for the development of angiosarcoma in these three cases.

It is interesting to note that out of the 5 malignancies reported around a knee arthroplasty, two were angiosarcomas (table I). This relatively high incidence may be due to oncogenic factors specific to angiosarcoma, although it may as well be coincidental.

The oncogenicity of prosthetic implants and their wear particles is probably low, if it exists.

Nevertheless, such rare cases deserve attention and must be brought to the scientific community in order to improve our understanding of the underlying pathology, and to eventually be able to evaluate the possibility for an increased risk for some specific types of malignancy development.

REFERENCES

1. **Adams JE, Jaffe KA, Lemons JE, Siegal GP.** Prosthetic implant associated sarcomas : a case report emphasizing surface evaluation and spectroscopic trace metal analysis. *Ann Diagn Pathol* 2003 ; 7 : 35-36.
2. **Arden GP, Bywater EG.** Tissue reaction. In : Arden GP, Ansell BM (eds). *Surgical Management of Juvenile Chronic Polyarthrititis*. Academic Press, London, 1978, p. 269.
3. **Carter RL, Roe FJ.** Induction of sarcomas in rats by solid and fragmented polyethylene : experimental observations and clinical implications. *Br J Cancer* 1969 ; 23 : 401-407.
4. **Eckstein FS, Vogel U, Mohr W.** Fibrosarcoma in association with a total knee joint prosthesis. *Virchows Arch Pathol Anat Histopathol* 1992 ; 421 : 175-178.
5. **Fryzek JP, Ye W, Signorello LB, Lipworth L et al.** Incidence of cancer among patients with knee implants in Sweden, 1980-1994. *Cancer* 2002 ; 94 : 3057-3062.
6. **Fury MG, Antonescu CR, Van Zee KJ, Brennan MF, Maki RG.** A 14-year retrospective review of angiosarcoma : clinical characteristics, prognostic factors, and treatment outcomes with surgery and chemotherapy. *Cancer J* 2005 ; 11 : 241-247. Erratum in : *Cancer J* 2005 ; 11 : 354.
7. **Himmer O, Lootvoet L, Deprez P, Monfort L, Ghosez JP.** [Angiosarcoma after total knee prosthesis. A propos of a case.] (in French). *Rev Chir Orthop* 1991 ; 77 : 125-129.
8. **Iglesias ME, Vázquez Doval FJ, Idoate F, Valentí JR, Quintanilla E.** Malignant fibrous histiocytoma at the site of total knee replacement. *J Dermatol Surg Oncol* 1994 ; 20 : 848-849.
9. **Jennings TA, Peterson L, Axiotis CA et al.** Angiosarcoma associated with foreign body material. A report of three cases. *Cancer* 1988 ; 62 : 2436-2444.
10. **Laskin DM, Robinson IB, Weinmann JP.** Experimental production of sarcomas by methyl methacrylate implants. *Proc Soc Exp Biol Med* 1954 ; 87 : 329-332.
11. **Mallick A, Jain S, Proctor A, Pandey R.** Angiosarcoma around a revision total hip arthroplasty and review of literature. *J Arthroplasty* 2009 ; 24 : 323.e17-20.
12. **McDonald DJ, Enneking WF, Sundaram M.** Metal-associated angiosarcoma of bone : report of two cases and review of the literature. *Clin Orthop* 2002 ; 396 : 206-214.
13. **McDougall A.** Malignant tumour at site of bone plating. 1956 ; 38-B : 709-713.

14. **Memoli VA, Urban RM, Alroy J, Galante JO.** Malignant neoplasms associated with orthopedic implant materials in rats. *J Orthop Res* 1986 ; 4 : 346-355.
15. **Min WK, Kim SY, Oh CW et al.** Malignant fibrous histiocytoma arising in the area of total hip replacement. *Joint Bone Spine* 2008 ; 75 : 319-321.
16. **Mirra JM.** *Bone Tumors.* Lea and Febiger, Philadelphia, 1989, p 1384.
17. **Naka N, Ohsawa M, Tomita Y et al.** Angiosarcoma in Japan. A review of 99 cases. *Cancer* 1995 ; 75 : 989-996.
18. **Ohsawa M, Naka N, Tomita Y et al.** Use of immunohistochemical procedures in diagnosing angiosarcoma. Evaluation of 98 cases. *Cancer* 1995 ; 75 : 2867-2874.
19. **Onega T, Baron J, MacKenzie T.** Cancer after total joint arthroplasty : a meta-analysis. *Cancer Epidemiol Biomarkers Prev* 2006 ; 15 : 1532-1537.
20. **Paavolainen P, Pukkala E, Pulkkinen P, Visuri T.** Cancer incidence after total knee arthroplasty : a nationwide Finnish cohort from 1980 to 1996 involving 9,444 patients. *Acta Orthop Scand* 1999 ; 70 : 609-617.
21. **Tharani R, Dorey FJ, Schmalzried TP.** The risk of cancer following total hip or knee arthroplasty. *J Bone Joint Surg* 2001 ; 83-A : 774-780.
22. **Visuri T, Pukkala E, Pulkkinen P, Paavolainen P.** Decreased cancer risk in patients who have been operated on with total hip and knee arthroplasty for primary osteoarthritis : a meta-analysis of 6 Nordic cohorts with 73,000 patients. *Acta Orthop Scand* 2003 ; 74 : 351-360.
23. **Visuri T, Pulkkinen P, Paavolainen P.** Malignant tumors at the site of total hip prosthesis. Analytic review of 46 cases. *J Arthroplasty* 2006 ; 21 : 311-323.
24. **Weber PC.** Epithelioid sarcoma in association with total knee replacement. A case report. *J Bone Joint Surg* 1986 ; 68-B : 824-826.