



## A family with cleidocranial dysplasia and crossed ectopic kidney in one child

Saraswathivilasam S. SURESH

*From the Ibri Regional Referral Hospital, Ibri, Sultanate of Oman*

**Cleidocranial dysplasia or dysostosis (CCD) is a condition characterised by failure of membranous ossification resulting in absence or pseudarthrosis of the clavicle, open fontanelles, wormian bones and supernumerary teeth. The aetiology though not completely known is thought to be due to a CBFA1 (core binding factor activity 1) gene defect on the short arm of chromosome 6p21. CBFA1 is essential for differentiation of stem cells into osteoblasts, so any defect in this gene will cause defects in membranous and endochondral bone formation. Since the first description, over 700 cases have been reported in literature.**

**The authors report a family with mother and her four sons affected with CCD and Crossed Renal Ectopia (CRE) in one child, which has not been reported in CCD before.**

**Key words :** pseudarthrosis ; clavicle ; short stature ; congenital anomaly ; crossed renal ectopia.

### INTRODUCTION

Cleidocranial dysplasia is a condition which is diagnosed as an incidental finding by clinicians when patients present to them for unrelated symptoms. The aetiology though not completely known is thought to be due to a CBFA1 (core binding factor activity 1) gene defect on the short arm of chromosome 6p21 (2,5,10,16,22,27).

The syndrome was first named by Marie and Sinton in 1898 (2,6,8,19,22), though the first documented case was in 1765 (6,19). The condition is now recognised to have been documented even

before this as the character Thersites from Homer's Iliad has been diagnosed to have cleidocranial dysostosis (3,6). The syndrome got renamed aptly from cleidocranial dysostosis to cleidocranial dysplasia after the conference for constitutional disorders of bone held in Paris in 1969 (22). This terminology is ideal since there are defects in ossification of the endochondral bone as well, and not only of the membranous bone, as previously thought, resulting in generalised skeletal dysplasia (22).

There is a defect in membranous ossification resulting in abnormalities in the skull, agenesis or total absence of the clavicle, retention of deciduous teeth with supernumerary teeth (16,22). CCD is transmitted as an autosomal dominant condition, the patients have normal intelligence and have a normal life span. Forty percent of cases are reported to be sporadic without any genetic cause (10,27). A triad of lesions as described by Tanaka *et al* (27) including multiple supernumerary teeth, partial or complete absence of clavicles and open sagittal sutures and fontanelles makes the diagnosis easy.

---

■ Saraswathivilasam S. Suresh MS Orth, MCh Orth, Head of Department of Orthopaedics.

*Department of Orthopaedics, Ibri Regional Referral Hospital, Ibri, Sultanate of Oman.*

Correspondence : Dr Saraswathivilasam S. Suresh, Head of Department of Orthopaedics, Ibri Regional Referral Hospital, PO Box 46, Ibri 516, Sultanate of Oman.

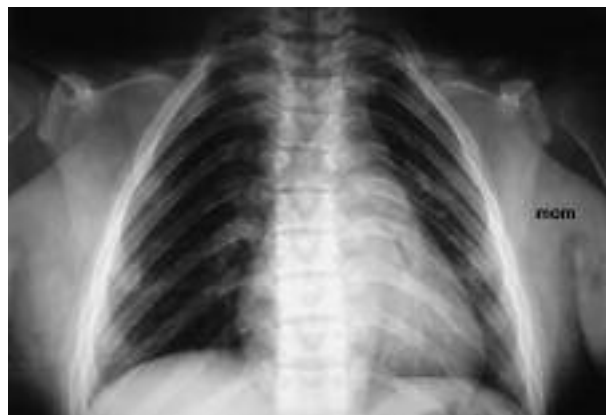
E-mail : dr.s.s.suresh@gmail.com

© 2009, Acta Orthopædica Belgica.

---



*Fig. 1.* — Clinical photograph- Mother and her 4 sons



*Fig. 2.* — Chest radiograph of the mother showing absence of the clavicle on the right and pseudarthrosis of the clavicle on the left.

This is mainly reported from societies where consanguineous marriages are a custom as in the Middle East countries. Skeletal anomalies are common in children born to consanguineous parents (24).

### CLINICAL CASES

A family of five patients (mother and four of her sons) with cleidocranial dysostosis born to normal consanguineous parents is being reported by the authors, due to the rarity of the condition (fig 1).

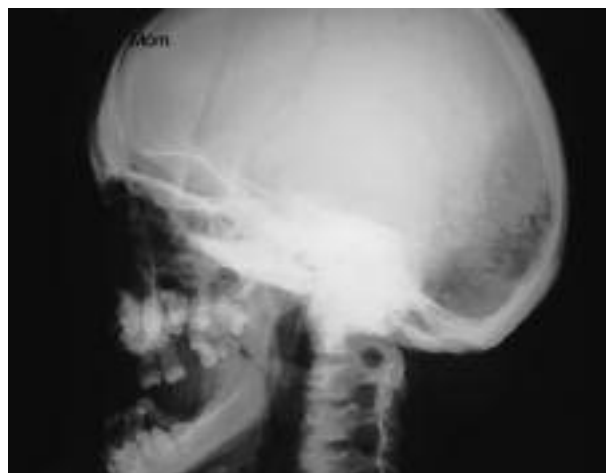The 38-year-old mother has a short stature, and a wide transverse diameter of the skull with prognathism due to maxillary hypoplasia. She has aplasia of the lateral end of the right clavicle and a pseudarthrosis of the left clavicle (figs 2-4).

She has hypertelorism and a high arched palate. The pelvis shows absent flaring of the iliac bones. Her spine radiographs revealed a spina bifida and spondylolysis of L5.

Hearing is normal and all her deliveries were normal.

Her first son is not affected by the syndrome. The second son, 17 years old, has a clavicular hypoplasia with bilateral pseudarthrosis. His hearing is normal (figs 5 & 6).

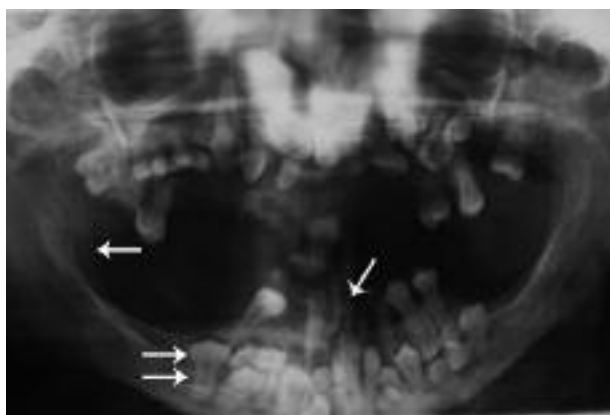
He has a Trendelenburg gait and radiographs reveal a bilateral coxa vara with overgrowth of the greater trochanters and absent flaring of the iliac wings. Radiographs of the spine show a mild mid-thoracic scoliosis.



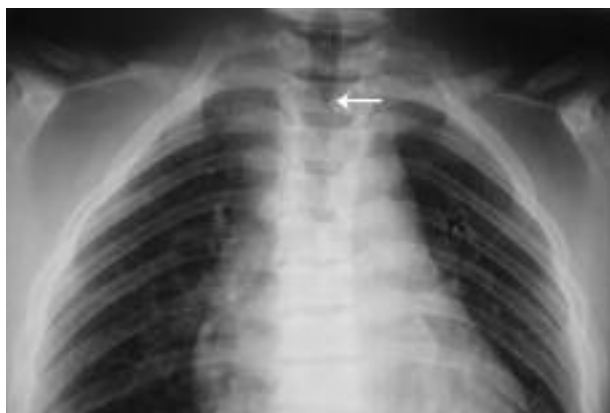*Fig. 3.* — Lateral view of the skull of the mother showing pseudoprognathism and hypoplasia of the maxilla.

The third son is now 14 years old and presents with facial asymmetry, congenital divergent squint and has bilateral conductive deafness with type B curves in the tympanogram. His response to spoken commands is good but a pure tone audiogram (PTA) shows typical elements of bilateral severe conductive hearing loss. He gets recurrent episodes of otitis media. Again clavicular hypoplasia is the most significant finding with an absent clavicle on the right and an absent lateral end on the left.

The fourth son (aged 11) has an absent clavicle on the right and an absent lateral end on the left. He



**Fig. 4.** — OPG of the mother showing unerupted permanent teeth, impacted supernumerary teeth in the upper and lower jaws (single arrow :parallel inner border of the ramus of the mandible, double arrow : unerupted permanent tooth, broken arrow : retained deciduous teeth).

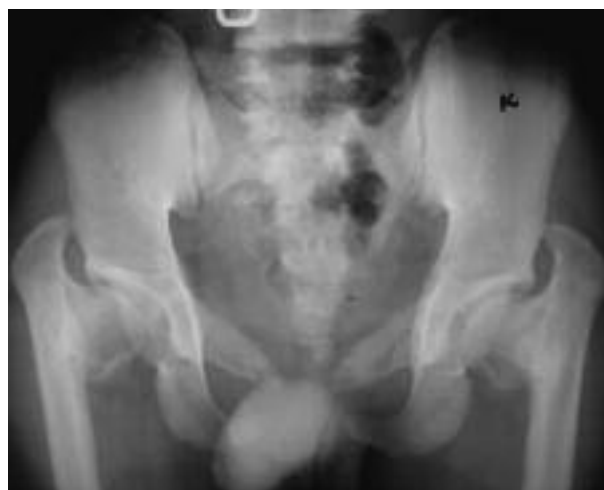

**Fig. 5.** — Chest radiograph of the second son showing a pseudarthrosis of the clavicle (arrow : defect in the posterior elements of the spine).

has a high arched palate similar to the other patients in this family. He has a wide symphysis pubis and vertical iliac wings. He also has dental caries and multiple decayed teeth.

The fifth and sixth siblings (boy and girl) are normal.

The most severely affected sibling is the youngest son, now 4 years old. He was born prematurely with a low birth weight and presented with Respiratory Distress Syndrome, requiring prolonged mechanical ventilation in the neonatal period.



**Fig. 6.** — Radiograph of the pelvis of the second son showing a coxa vara, trochanteric overgrowth and a vertical orientation of the iliac wings.

His chest radiographs revealed a clavicular hypoplasia, with an absent clavicle on the right and a pseudarthrosis of the clavicle on the left.

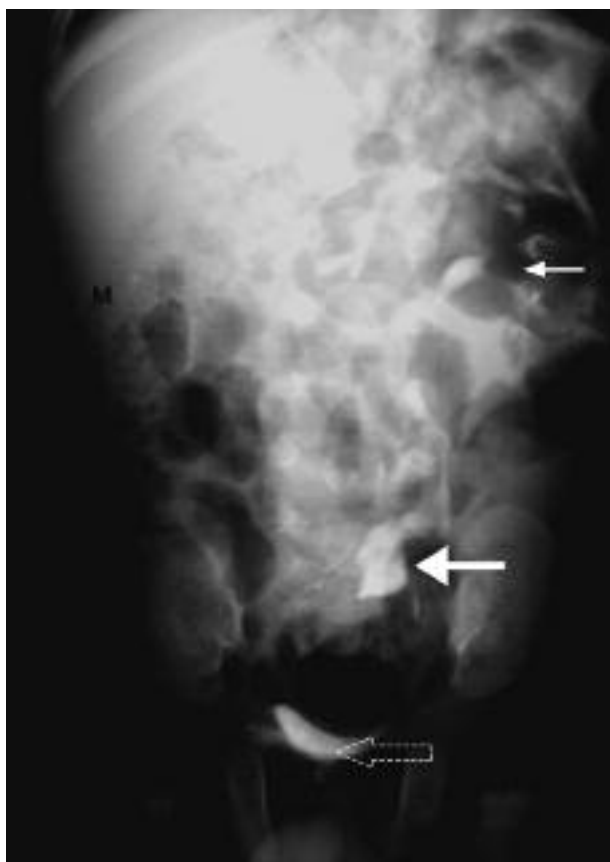The patient was investigated for a recurrent urinary tract infection with *Proteus*, and an initial ultrasound scan of the abdomen failed to reveal the kidney in the right renal fossa.

A CT intravenous urogram showed a right kidney posterior to the bladder measuring 36 mm by 18 mm with good function. The left kidney was found in the normal location (figs 7 & 8).

The bladder was normal. The child recovered with appropriate antibiotic therapy and hence no further intervention was done for the renal ectopia.

All patients also had other features of CCD in the form of wide anterior fontanelle, frontal bossing, hypertelorism, low set ears, and prominent raised coronal sutures.

Genitalia of all patients were normal. Their skull radiographs revealed multiple wormian bones. A panoramic view of their teeth showed supernumerary teeth, multiple retained deciduous and multiple unerupted teeth. Another feature noticed was the almost parallel anterior and posterior border of the ramus of the mandible. The second metacarpal was found to be long in all patients with an accessory epiphysis at the base of the second and fifth metacarpal.



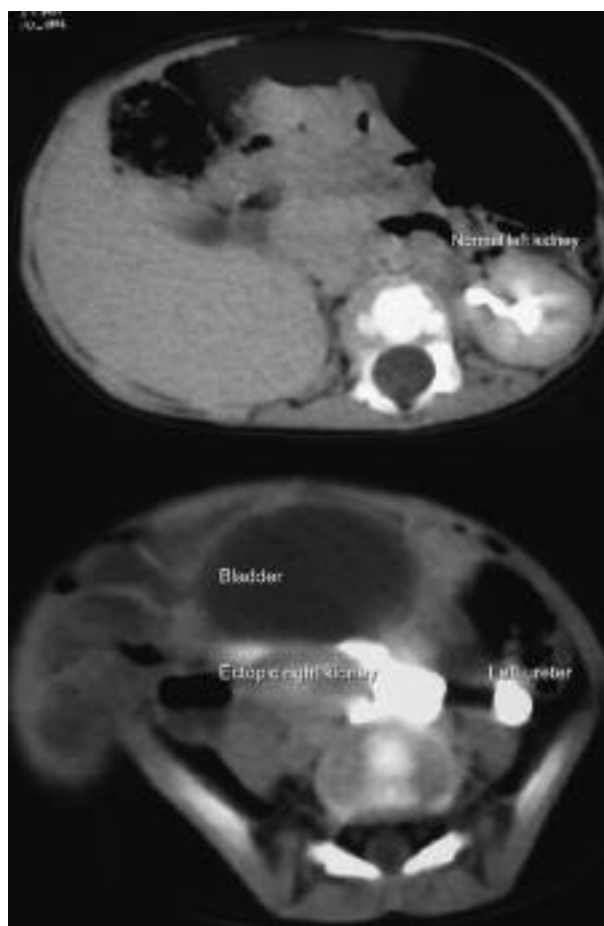
**Fig. 7.** — Intravenous pyelogram of the youngest son showing an ectopic kidney (small arrow : left normal kidney, broad arrow : ectopic kidney, broken arrow : bladder).

Though short statured, these patients cannot not be labelled as dwarfs. Their intelligence is normal. In all five cases a defect in the clavicle can be palpated.

### DISCUSSION

CCD is a condition characterised by moderately short stature, facial abnormalities and abnormalities affecting the skull and clavicle (21,22,26). Over 700 cases have been reported in the literature with an incidence of one in 1 million (5). The incidence may be higher and unreported as most of the patients do not seek medical advice (5).

There are many reports in the literature of CCD in families (8,12,25).



**Fig. 8.** — CT scan of the youngest son showing the ectopic kidney posterior to the bladder and the normal left kidney.

The aetiology though not completely known is thought to be due to a CBFA1 (core binding factor activity 1) gene defect on the short arm of chromosome 6p21 (5,10,16,22). CBFA1 is essential for differentiation of stem cells into osteoblasts, so any defect in this gene will cause defects in the membranous and endochondral bone formation (6,22). It affects bones of intramembranous origin and endochondral bone formation of long bones, there is also failure of midline ossification. Involvement of non membranous bones is also well recognised (12,22). Keats (15) in 1967 reported the involvement of long bones, the spine and the base of the skull. Subsequently Jarvis and Keats (12) extensively reviewed the skeletal anomalies in CCD.

The characteristic feature of the disease is partial absence of one or both clavicles or in 10% of cases its total absence (6,7,26). The midclavicular portion is usually absent due to failure of coalescence of the two primary ossification centers of the clavicle (7). The clavicular abnormality is usually bilateral, but if unilateral the right side is more affected (6,12,27).

A pseudarthrosis occurs between the enlarged ends of the clavicle slightly lateral to the midpoint (12,21,25) with rudimentary sternal and acromial ends (12,26). Some authors have mentioned that complete absence of the clavicle is rare (21,22). There are also reports about absence of the sternal end with presence of the acromial end (22). There are few reports with normal clavicles (6,8,22). The clavicular defect in CCD is proposed to be due to the abnormal elevation of the first ribs and the pressure upon the developing clavicles by the subclavian artery (25). Due to the absence of the clavicle the thorax is barrel shaped (12). This also results in hyper mobility of the shoulders which most of the patients can approximate in the midline anteriorly. The conical shape of the thorax which is present at birth persists throughout adult life (12). Due to absence of the clavicle the muscles which originate from it are also maldeveloped.

The diagnostic triad of clavicular aplasia, multiple supernumerary teeth and open sagittal sutures and fontanelles makes the diagnosis of this condition easy even before a radiographic examination (27).

Patients have brachycephaly, hypertelorism, open fontanelle and suture, multiple wormian bones and delayed suture closure (27). There is segmental thickening of the supra orbital part of the frontal and temporal bone. There is pseudopognathism due to an underdeveloped maxilla (22,27). Most of the patients present with dental anomalies. There is delayed eruption or failure of eruption of permanent teeth, with presence of supernumerary teeth due to retention of deciduous teeth (5,22,27).

The presence of multiple supernumerary teeth may be the cause of impaction of permanent teeth (5,27).

Multiple supernumerary teeth and midfacial deformity can cause malocclusion (5,6,12,13,22). It is possible for dental surgeons to predict the time of

formation of supernumerary teeth and their location and initiate early treatment (13,16,27).

Conductive deafness may be present with frequent episodes of otitis media (5,6). One of the five patients in this report has bilateral severe conductive hearing loss as demonstrated by PTA. He has also been treated for frequent attacks of otitis media. Predominant middle ear hearing loss is reported to be due to structural changes in the small middle ear bones and structural abnormalities in the temporal bones make corrective surgery difficult (5,11).

The maxilla and paranasal sinuses are underdeveloped, resulting in prognathism (22,27). Absence of nasal bones is another feature of the syndrome (22,27).

Parietal foramina (symmetrical oval defects in the parietal bones) with clavicular hypoplasia is named and listed in the London Dysmorphology Database as Parietal Foramina with CCD (PFCCD) (21).

More than 700 cases have been reported in the literature but association with crossed ectopic kidney has not been reported before. Crossed renal ectopia is a rare congenital condition where one kidney is transposed to the side opposite to its normal location.

Malrotation of the ectopic kidney is the rule (18,23).

Many skeletal anomalies have been reported with renal ectopia like Holt Oran syndrome, Fanconi's syndrome, TAR syndrome, VATER association (1,23). Spina bifida, scoliosis, and developmental dysplasia of the hip are also reported with crossed renal aplasia (7,10,17,18,23).

The incidence of crossed renal ectopia (CRE) reported is 1:7000 (4,18,23). The incidence of unfused crossed renal ectopia is reported to be 1:75,000 autopsies (23).

A congenital pelvic kidney is common on the left side (4,9). There are reports of crossed renal ectopia without fusion more common on the right side (18,23). Ectopic kidneys are dysplastic and usually non functional but in our case, though the size was small, the kidney was functioning well. CRE is usually diagnosed while an investigation is done for some other symptomatology (23). In our case the child was investigated for a recurrent urinary tract

infection with *Proteus*, and during the initial ultrasound scan the right kidney was not detected. The child subsequently underwent a contrast CT scan which demonstrated the ectopic pelvic kidney. Treatment was not done as the kidney was found to be functional and the child responded to antibiotic therapy (18,23).

A high proportion of children with renal ectopia have vesico-ureteric reflux, and when present with decreased function of the ectopic kidney it predisposes these children to recurrent urinary tract infections (9,17,18,23).

MacEwen *et al* (17) found an incidence of 2.5% renal ectopia in an analysis of congenital scoliosis, and they mention the ectopia as a cause of infection and calculus.

The fingers are short and tapered, and the second metacarpal is found to be long (6,12,22).

The distal and middle phalanges of the second and fifth fingers are short (6,22). This can produce tapering of the digit, due to poor development of the terminal phalanx (12).

Jarvis and Keats (12) reported lateral notching of the proximal femoral ossification centre, with femoral head and neck widening. Aktas *et al* (2) reported that the cbfA1 (core binding factor activity 1) gene defect on the short arm of chromosome 6 may be a factor in the unusual development of the proximal femur. The authors reported association of CCD with a "chef's hat" appearance of the head of the femur, where the height of the epiphysis is greater than the width (2,12).

One of the patients in this report had coxa vara with trochanteric overgrowth. There is widening of the symphysis pubis due to delay in its ossification. Other associations are widening of the sacro iliac joints, hypoplasia and anterior rotation of the iliac wings (12,22). These pelvic abnormalities can lead to cephalo pelvic disproportion (CPD) and increased incidence of caesarian sections (5,7,10,12). The pelvis is involved in most of the patients and hence some authors describe this condition as Pelvico-Cleido-Cranial dysplasia (12). Ischio vertebral dysplasia is reported in a family with CCD by Kaissi *et al* (14). In an analysis of this family of CCD defects in ossification of the pubic bone was seen in all cases (14).

A high incidence of spondylolysis of the lumbar vertebrae has been documented by Jarvis and Keats (6,10,12). The mother in this series had spondylolysis of the L5 vertebra.

Neurological and vascular problems also can develop in CCD. Medhi *et al* (20) reported a case with progressive spasticity of all four limbs due to bilateral parieto-occipital white matter lesions with atrophy. MR of the spine showed a large subarachnoid space with a small cord suggesting cord atrophy (20). Association with syringomyelia has also been reported (6,7,26).

Though CCD is categorised as a dwarfing condition the dwarfism is moderate and short stature is not severe enough to categorise CCD as a dwarfing condition (5).

## CONCLUSION

The typical clinical appearance of this condition should alert the physician about the diagnosis before performing radiographic examination. The predominant feature in every case is aplasia of the clavicle. It is easily differentiated from similar conditions of hypoplasia of the clavicles like congenital pseudarthrosis, pyknodysostosis, mandibulo-acral dysplasia and Yunis-Varon syndrome.

The author reports a family with cleidocranial dysostosis, with a mother and four of her seven children affected and a crossed ectopic kidney in one of the siblings. This is the first report of crossed renal ectopia in a patient with cleidocranial dysplasia.

## REFERENCES

1. Afzal K, Najmussaib M. Familial Radial Dysplasia with renal ectopia, *Indian Pediatr* 2006 ; 43 : 76-77.
2. Aktas S, Wheeler D, Sussman MD. The 'Chef's hat' appearance of the femoral head in cleidocranial dysplasia. *J Bone Joint Surg* 2000 ; 82-B : 404-408.
3. Altschuler EL. Cleidocranial dysostosis and the unity of the Homeric Epics : An essay, *Clin Orthop Relat Res* 2001 ; 383 : 286-292.
4. Belsare SM, Chimmalgi M, Vaidya SA, Sant SM. Ectopic kidney and associated anomalies : A case report. *J Anat Soc of India* 2002 ; 51 : 236-238.
5. Cooper SC, Flaitz CM, Johnston DA *et al*. A natural history of cleidocranial dysplasia. *Am J Med Genet* 2001 ; 104 : 1-6.

6. **Currall V, Clancy R, Diamond D et al.** Cleidocranial dysplasia. *Curr Orthop* 2007 ; 21 : 159-162.
7. **Dore DD, McEwen GD, Boulous MI.** Cleidocranial dysostosis and syringomyelia : Review of the literature and case report. *Clin Orthop* 1987 ; 214 : 229-234.
8. **Flynn DM.** Family with cleido-cranial dysostosis showing normal and abnormal clavicles, *Proc R Soc Med* 1966 ; 59 : 491-492.
9. **Guarino N, Tadini B, Camardi P et al.** The incidence of associated urological abnormalities in children with renal ectopia. *J Urology* 2004 ; 172 : 1757-1759.
10. **Gulati S, Kabra M.** Cleidocranial dysplasia. *J Postgrad Med* 2001 ; 47 : 204-205.
11. **Hawkins HB, Shapiro R, Petrillo CJ.** The association of cleidocranial dysostosis with hearing loss. *Am J Roentgenol* 1975 ; 125 : 944-947.
12. **Jarvis JL, Keats TE.** Cleidocranial dysostosis- A review of 40 new cases. *Am J Roentgenol* 1974 ; 121 : 5-16.
13. **Jensen BL, Keiborg S.** Dental treatment strategies in cleidocranial dysplasia. *Br Dent J* 1992 ; 172 : 243-247.
14. **Kaissi A, Chehida FB, Safi H, Ben M.** Massive spinal-ischial dysplasia and extensive spinal dyssegmentation in a Tunisian child with severe form of Cleido cranial dysplasia. *Afr J Biomed Res* 2005 ; 8 : 127-129.
15. **Keats TE.** Cleidocranial dysostosis- some atypical roentgen manifestations, *Am J Roentgenol* 1967 ; 100 : 71-74.
16. **Lopez BS, Solalinde CO, Ito TK et al.** Cleido cranial dysplasia : report of a family. *J Oral Sci* 2004 ; 46 : 259-266.
17. **MacEwen GD, Winter RB, Hardy JH, Sherk HH.** The classic : Evaluation of kidney anomalies in congenital scoliosis. *Clin Orthop Relat Res* 2005 ; 434 : 4-7.
18. **Mansberg VJ, Rossleigh MA, Farsworth RH, Rooijen MV.** Unfused crossed renal ectopia with ectopic left ureter inserting into a prostatic utricle diverticulum. *Am J Roentgenol* 1999 ; 172 : 455-456.
19. **McBride ED.** Congenital deficiency of the clavicle-hereditary cleidocranial dysostosis. *J Bone Joint Surg* 1927 ; 9 : 545-552.
20. **Medhi N, Saharia B, Handique SK.** Progressive paraparesis with cleidocranial dysostosis. *Ind J Radiol Imag* 1999 ; 9 : 141-143.
21. **Minaur SG, Mavrogiannis LA, Rannan-Eliya SV et al.** Parietal foramina with cleidocranial dysplasia is caused by mutation in MSX2. *Eur J Human Genet* 2003 ; 11 : 892-895.
22. **Mundlos S.** Cleidocranial dysplasia : clinical and molecular genetics. *J Med Genet* 1999 ; 36 : 177-182.
23. **Nursal GN, Buyukdereli G.** Unfused renal ectopia : a rare form of congenital anomaly. *Ann Nucl Med* 2005 ; 19 : 507-510.
24. **Patel PK.** Profile of major congenital anomalies in the Dhahira region, Oman. *Ann Saudi Med* 2007 ; 27 : 106-111.
25. **Roberts GC, Apley AG, Owen R.** Reflections upon the aetiology of congenital pseudarthrosis of the clavicle with a note on cranio-cleido dysostosis. *J Bone Joint Surg* 1975 ; 57 B : 24-29.
26. **Sharma A, Yadav R, Ahlawat K.** Cleidocranial dysplasia. *Indian Pediatr* 1995 ; 32 : 588-592.
27. **Tanaka JL, Ono E, Filho EM et al.** Cleidocranial dysplasia : importance of radiographic images in diagnosis of the condition. *J Oral Sci* 2006 ; 48 : 161-166.