

Pseudoaneurysm complicating knee arthroscopy A case report

Emmanuel AUDENAERT, Marc VUYLSTEKE, Peter LISSENS, Michiel VERHELST, René VERDONK

Pseudoaneurysm formation is a rare complication after knee arthroscopy. Most pseudoaneurysms complicating knee arthroscopy develop on the popliteal and geniculate arteries. We report a case of a pseudoaneurysm developed on an arterial branch to the medial gastrocnemius muscle, as a complication of an arthroscopic meniscectomy in a 66-year-old patient. The patient was treated successfully by resection of the pseudoaneurysm and ligation of the injured artery.

Arthroscopy of the knee is a common and safe procedure, with relatively few complications. The reported incidence of nerve and vessel injuries following knee arthroscopy in large series ranges from 0.56% (3) to 0.80% (7). This low incidence may be a reason why vascular complications are often misdiagnosed and improperly treated. Arterial injuries demand an early diagnosis and appropriate treatment to avoid further progression of the lesion as it can be limb threatening.

Pseudoaneurysms in the knee region have been reported as a complication after arthroscopy, ligament repair, penetrating trauma, synovectomy, total knee arthroplasty, proximal tibial osteosynthesis and tibial nailing (2, 5). They normally present as a recurrent haemarthrosis and a pulsatile mass within two or three weeks after the procedure. The popliteal and superior and inferior geniculate arteries are most often affected. We report a pseudoaneurysm of an arterial branch to the gastrocnemius muscle, an unusual location for a pseudoaneurysm after knee arthroscopy.

CASE REPORT

A 66-year-old lady presented with clinical signs of a left medial meniscal lesion after minor trauma. Magnetic resonance imaging showed a lesion of the left medial meniscus. Partial meniscectomy was performed using an arthroscopic technique. A pneumatic tourniquet was left inflated over the distal part of the thigh throughout the procedure. The patient left the hospital one day after surgery, without any signs of a complication and without a haemarthrosis. Over a period of two weeks post-operatively, she developed significant pain and swelling of the calf. Her general practitioner diagnosed a deep venous thrombosis and treated her with a low molecular weight heparin. The patient presented three weeks postoperatively at the hospital with massive oedema, ecchymosis, calf pain and

From St-Andries Hospital, Tielt, Belgium.

Emmanuel Audenaert, Registrar.

Marc Vuylsteke, Consultant Surgeon.

Peter Lissens, Consultant Surgeon.

Department of General Surgery, St-Andries Hospital, 8700 Tielt, Belgium.

Michiel Verhelst, Consultant Orthopaedic Surgeon.

Department of Orthopaedic Surgery, St-Andries Hospital, 8700 Tielt, Belgium.

René Verdonk, Professor and Chairman.

Department of Orthopaedic Surgery, University Hospital, Ghent, Belgium.

Correspondence and reprints : Marc Vuylsteke, Department of General Surgery, St-Andries Hospital, Krommewal 9-11, 8700 Tielt, Belgium.

© 2003, Acta Orthopædica Belgica.

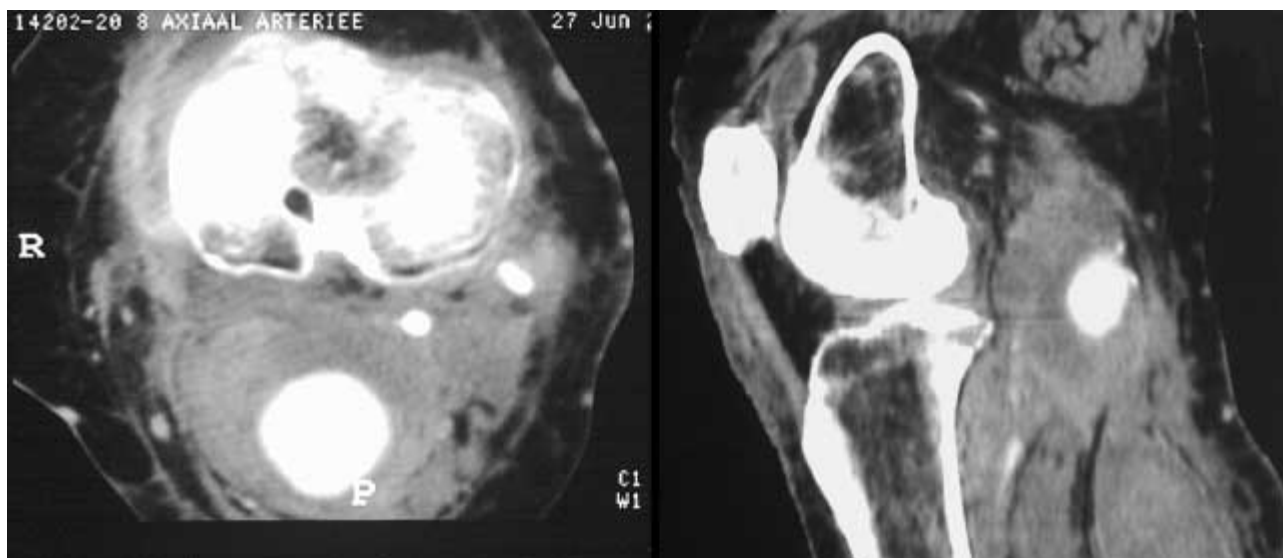


Fig. 1. — Axial and sagittal CT-angiography of the pseudoaneurysm complicating partial arthroscopic medial meniscectomy. The popliteal artery, geniculate branches and the pseudoaneurysm are well visible and are not connected.

a voluminous mass in the popliteal fossa. She had palpable pulsations of the dorsal pedis and posterior tibialis artery. Echography and CT-angiography of the lower limb showed a calf haematoma and a voluminous pseudoaneurysm with a diameter of 5 centimetres in the popliteal fossa (fig 1). Surgical exploration was done through a medial incision over the proximal part of the calf, using a pneumatic thigh tourniquet. The haematoma, deep to the calf muscles, was evacuated. The haematoma communicated with the pseudoaneurysm through a 3-mm opening. The pseudoaneurysm arose from a narrow-necked filiform muscular arterial branch to the gastrocnemius muscle. Resection of the pseudoaneurysm, with ligation of the distal branches and drainage of the haematoma was performed. A good distal flow was noted after surgery and a compressive bandage was placed. Further rehabilitation was uneventful and the patient was discharged from hospital two days after surgery.

DISCUSSION

Pseudoaneurysm formation is a rare complication of knee arthroscopy considering the large number of arthroscopic operations performed. It

can present as a pulsatile mass, a haemarthrosis or a large haematoma. As the false aneurysm grows, space-occupying effects such as neurological compression and neuralgia or venous compression and thrombosis can occur. The delay between surgery or trauma and diagnosis ranges from one week to three months (1). Delay of diagnosis can lead to amputation if the aneurysm involves the popliteal artery.

Pseudoaneurysms in the knee region have been reported after arthroscopy, arthroplasty, ligament repair, synovectomy, penetrating knee trauma and intramedullary nailing of the tibia (2, 6). The popliteal artery is most frequently affected, but cases have also been reported involving the geniculate and the anterior tibial artery. We only found one case describing a pseudoaneurysm located on a muscular branch of the popliteal artery. In that specific case, as in ours, a muscular branch to the vastus medialis was affected (4). The real incidence of this rare entity is not known. The Arthroscopy Association of North America reported 6 cases out of 118 590 arthroscopies (3). Four of these patients ended up with a below-knee amputation of the affected limb. In a retrospective study of Small *et al*, nine patients out of 375.000 developed a pseudoaneurysm after knee arthroscopy (7).

The risk to develop an arterial injury during knee surgery is associated with the close anatomic relation of the vessels and the knee joint capsule. During knee flexion, the arterial structures are moved forward towards the posterior capsule and the popliteal artery is then only separated from the capsule by a small layer of fat. As the posterior part of the knee is not quite visible during arthroscopy and a tourniquet is often used, these lesions are not directly diagnosed during arthroscopy. For this reason, one should carefully check the circulation of the limb after surgery before applying a pressure bandage.

Theoretically a disruption of the arterial wall seems necessary to develop a false aneurysm. The aneurysm wall is then formed by the surrounding tissue. Pseudoaneurysm formation after knee arthroscopy can also appear without a history of penetration of the knee capsule or vessel wall. One of the hypotheses explaining this phenomenon is the shear stress on the knee structures and arteries during surgery and specifically during arthroscopy (6).

An arterial duplex study is the diagnostic imaging modality of choice, as it is an easily available, relatively inexpensive and non-invasive procedure. Conventional arteriography, or digital subtraction angiography, remains the decisive investigation for accurate demonstration of the vascular anatomy before surgery.

Spontaneous thrombosis can occur or can be induced by compression by the echography probe

in aneurysms smaller than 2 cm. For aneurysms less than 5 cm, ligation of the defect in the arterial wall or percutaneous injection of thrombin into the aneurysmal sac and therapeutic embolisation by means of coils or prothrombine can be sufficient. For bigger lesions, surgical exclusion of the aneurysm and restoration of blood flow with bypass surgery should be accomplished (4). In some specific cases exclusion of the aneurysm can be performed by using a vascular endoprosthesis.

REFERENCES

1. **Aldrich D, Anschuetz R, Lopresti C et al.** Pseudoaneurysm complicating knee arthroscopy. *Arthroscopy* 1995 ; 11 : 229-230.
2. **Bennet F, Born C, Alexander J, Crinolcoli M.** False aneurysm of the medial inferior genicular artery after intramedullary nailing of the tibia. *J Orthop Trauma* 1994 ; 8 : 73-75.
3. **DeLee LC.** Complications of arthroscopy and arthroscopic surgery : Results of a national survey. *Arthroscopy* 1985 ; 1 : 214-220.
4. **Hilborn M, Munk PL, Miniaci A et al.** Pseudoaneurysm after therapeutic knee arthroscopy : Imaging findings. *Am J Roentgenol* 1994 ; 163 : 637-639.
5. **Karkos CD, Thomson GJ, D'Souza SP, Prasa V.** False aneurysm of the popliteal artery : a rare complication of total knee replacement. *Knee Surgery, Sports Traumatology, Arthroscopy* 2000 ; 8 : 53-55.
6. **Lantis JC, Weiner R.** Pseudoaneurysm etiology and management, with a case presenting as a pulsatile popliteal mass. *Contemp Surg* 2000 ; 56 : 686-690.
7. **Small NC.** Complications in arthroscopy : The knee and other joints. *Arthroscopy* 1986 ; 2 : 253-258.