



## Spontaneous resolution of a massive pseudomeningocele

Andrew CLARKE, Michael HUTTON

*From Princess Elizabeth Orthopaedic Centre, Royal Devon and Exeter Hospital, Exeter, Devon, United Kingdom*

**A pseudomeningocele is an extradural collection of cerebrospinal fluid which results from a dural or arachnoid tear. The fluid is not contained within a protrusion of the meninges, which is typical for a real meningocele. Although most pseudomeningoceles probably go unrecognised, due to lack of symptoms, surgeons should maintain an index of suspicion when reviewing postoperative patients. Symptomatic pseudomeningoceles warrant intervention, as the patients do not tolerate the symptoms. However, the literature neither suggests a trial of watching and waiting nor a suitable time frame for such a trial. The authors report the spontaneous resolution of a massive symptomatic pseudomeningocele after 11 months. There is only one previous report of a similar case, where the pseudomeningocele disappeared in three months.**

**Keywords :** pseudomeningocele ; symptomatic ; spontaneous resolution.

### INTRODUCTION

A pseudomeningocele is an extradural collection of cerebrospinal fluid which results from a dural or arachnoid tear (2). The exact incidence is unknown. The vast majority are iatrogenic (1), following inadvertent durotomy during spinal surgery. Most pseudomeningoceles become embedded in the paraspinous soft tissue and frequently are asymptomatic (5). The authors report a massive symptomatic postoperative lumbar pseudomeningocele, which resolved spontaneously over an 11-month period.

### CASE REPORT

A 57-year-old male fish and chips shop owner presented to the spinal service with a two-year history of low back pain and bilateral leg pain, suggestive of spinal stenosis. He had been treated conservatively with physiotherapy and epidural injections at the referring hospital. Imaging revealed widespread degenerative changes from L3 to S1, with severe stenosis at L4/L5. He was offered spinal decompression after suitable counseling.

The operative findings were marked facet joint hypertrophy and calcified ligamentum flavum adherent to the dura. A wide decompression was performed. Unfortunately, on freeing the adhesions, the dura was violated. This was repaired in a watertight fashion with 6/0 prolene, and confirmed with a Valsalva manoeuvre. The postoperative course was uneventful.

---

■ Andrew Clarke, FRCS (Orth), Specialist Registrar, Trauma and Orthopaedics.

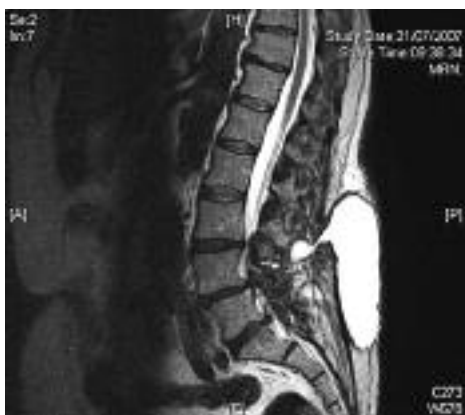■ Michael Hutton, FRCS (Orth), Consultant Spinal Surgeon.

*The Exeter Spinal Unit, Princess Elizabeth Orthopaedic Centre, Royal Devon and Exeter Hospital, Exeter, Devon, UK.*

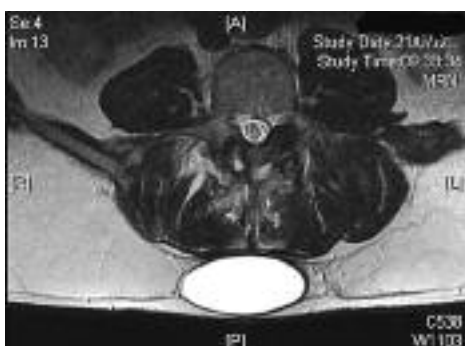
Correspondence : Mr Andrew Clarke, The Spinal Unit, Princess Elizabeth Orthopaedic Centre, Royal Devon and Exeter Hospital, Barrack Road, Exeter, Devon, EX2 5DW, United Kingdom. E-mail : kluver\_bucy@hotmail.com

© 2009, Acta Orthopædica Belgica.

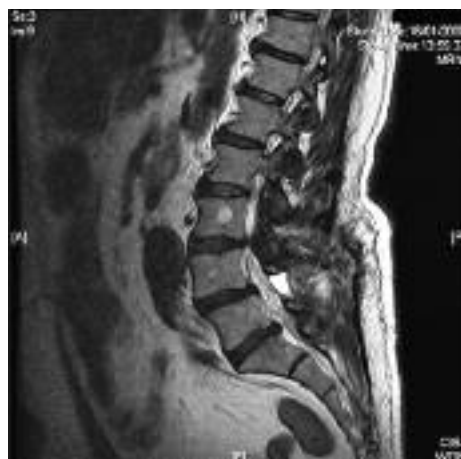---



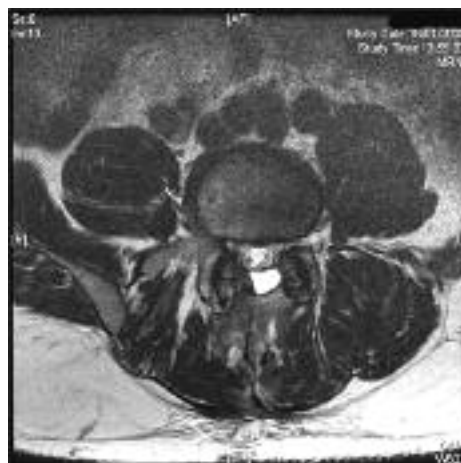*Fig. 1a.* — Sagittal MRI of pseudomeningocele



*Fig. 1b.* — Axial MRI of pseudomeningocele



*Fig. 2a.* — Sagittal MRI of resolved pseudomeningocele



*Fig. 2b.* — Axial MRI of resolved pseudomeningocele

Six weeks after surgery the patient complained about a large boggy swelling at the wound site together with headaches, made worse by sitting for long periods or walking. He did not have any focal neurological symptoms. A diagnosis of pseudomeningocele was made. An MRI scan (fig 1a & 1b), 5 months post operation, revealed a pseudomeningocele, lying in the subcutaneous tissues. It measured 11 cm × 3 cm × 6 cm. It was seen to be tracking down to the L4/L5 level. The patient was referred to the neurosurgical unit for surgical repair. Here a wait and see policy was followed, and during the ensuing six months the symptoms resolved. The patient returned for review to the spinal service. The swelling had disappeared, along with the headaches. A repeat MRI (fig 2a & 2b) demonstrated spontaneous resolution of the massive pseudo-

meningocele, leaving a small, asymptomatic fluid collection posterior to the dural sac.

## DISCUSSION

There is only one previous report of a symptomatic pseudomeningocele resolving spontaneously after 3 months (3). Whilst the vast majority probably go unrecognised due to lack of symptoms, surgeons should maintain an index of suspicion when reviewing postoperative patients. Symptoms can include headache, back pain and radicular pain (5).

The literature supports conservative management initially (2,5). Such regimes include bed rest, epidural blood patch and CSF diversion. Symptomatic pseudomeningoceles are an indication for operative intervention. In the current case the headache and the massive volume of the pseudomeningocele (4) pleaded for surgical repair. However, the neurosurgical unit assumed an attitude of expectation, and spontaneous resolution occurred.

Surgical intervention is not without morbidity. The aim is to close the dura, without causing an iatrogenic stenosis of the dural tube. This can be achieved by various techniques involving auto- or allograft fascia, fibrin sealants and, if required, myofascial flaps (5).

In conclusion, massive symptomatic pseudomeningoceles can spontaneously resolve. Hence, if symptoms permit, a reasonable period of conser-

vative management (here 11 months) may result in resolution without intervention.

## REFERENCES

1. **Couture D, Branch CL Jr.** Spinal pseudomeningoceles and cerebrospinal fluid fistulas. *Neurosurg Focus* 2003 ; 15(6) : E6.
2. **Hawk MW, Kim KD.** Review of spinal pseudomeningoceles and cerebrospinal fluid fistulas. *Neurosurg Focus* 2000 ; 9(1) : E5.
3. **Kumar AJ, Nambiar CS, Kanse P.** Spontaneous resolution of lumbar pseudomeningocele. *Spinal Cord* 2003 ; 41 : 470-472.
4. **Misra SN, Morgan HW, Sedler R.** Lumbar myofascial flap for pseudomeningocele repair. *Neurosurg Focus* 2003 ; 15(3) : E13.
5. **Paolini S, Ciappetta P, Piattella MC.** Intraspinal post-laminectomy pseudomeningocele. *Eur Spine J* 2003 ; 12 : 325-327.