



Deformity correction during growth after partial physal arrest

Joachim HORN, Leif Pål KRISTIANSEN, Harald STEEN

From the Department of Orthopaedics, University Hospital Rikshospitalet Oslo, Norway

The purpose of this study was to evaluate our treatment protocol for certain physal injuries requiring complete epiphysiodesis of an injured physis, angular correction and lengthening with the Ilizarov method and overcorrection of length according to calculated loss of remaining growth.

Five patients (age : 12 to 14 years) were operated with angular correction and lengthening in combination with complete epiphysiodesis. Angular deformities measured 12° to 24° and limb length discrepancies (LLD's) 15 to 60 mm. Mean overcorrection of length according to remaining growth of the affected physis was 12 mm (range : 7 to 15).

All deformity parameters were fully corrected in all patients. Mechanical axis deviation (MAD) was within ± 5 mm compared to the healthy side in 4 patients, 20 mm in one patient. Median LLD at maturity was 8 mm (range : 3 to 13).

In cases of partial physal arrest with severe symptomatic deformities, complete epiphysiodesis of the injured physis, angular correction and lengthening with the Ilizarov method with overcorrection of length according to estimated loss of remaining growth of the affected physis is a suitable method.

Keywords : epiphysiodesis ; physal arrest ; Ilizarov method ; deformity correction ; leg length discrepancy.

INTRODUCTION

Fractures of the long bones in the lower extremity with involvement of the physis are common injuries in children and adolescents (25). According

to Salter (27) approximately 15% of all long bone injuries during childhood involve the physal plate. Fortunately, most of the physal injuries are not associated with any disturbance of growth. If the entire physal plate ceases to grow, the result is progressive shortening without angulation (27). However, peripheral partial growth arrest may result in significant angular deformity and leg-length discrepancy, dependent upon the localisation and magnitude of the injury, the age of the patient and the anticipated remaining growth (3,8,19). Treatment is indicated in patients with existing or developing deformities and a significant amount of remaining growth (17). Treatment options are : resection of the physal bridge, physal distraction, acute corrective osteotomy or gradual correction using the Ilizarov method with callotaxis and complete epiphysiodesis of the affected physis. These

-
- Joachim Horn, MD, Orthopaedic Surgeon.
 - Leif Pål Kristiansen, MD, Orthopaedic Surgeon.
 - Harald Steen, MD, PhD, Orthopaedic Surgeon.

Department of Orthopaedics, University Hospital Rikshospitalet, Oslo, Norway.

Correspondence : Joachim Horn, MD, Department of Orthopaedics, University Hospital Rikshospitalet, Sognsvannsveien 20, N 0027 Oslo, Norway.

E-mail : joachim.horn@rikshospitalet.no

© 2009, Acta Orthopædica Belgica.

procedures can be used in combination with contralateral shortening or epiphysiodesis. In cases where the size of the physal bridge, the amount of angular deformity, the shortening and the limited remaining growth potential make it unlikely to expect an acceptable degree of spontaneous correction after physal bridge resection, corrective osteotomy or gradual correction with the Ilizarov method may be required. When the deformity is symptomatic and a risk for secondary structural changes in the adjacent joints exists, a correction before skeletal maturity is indicated. In this regard complete epiphysiodesis of the affected physis will be necessary to prevent recurrent deformity after correction. Either acute or gradual correction with the Ilizarov method is used. The remaining growth potential of the involved physis has to be considered in order to prevent leg length discrepancy at skeletal maturity. The aim of the current study was to present and evaluate our treatment protocol including : complete epiphysiodesis of the injured physis, combined with angular correction and lengthening with the Ilizarov method and overcorrection of length according to the estimated loss of remaining growth of the affected physis. To our knowledge there are no former studies describing this topic.

PATIENTS AND METHODS

From February 2001 until November 2005 five patients were operated at our institution by angular correction and lengthening in combination with complete epiphysiodesis after partial physal arrest of a growth plate. Three were boys and two girls with a mean age of 13 years (range : 12 to 14) at the time of surgery. Three patients had a partial physal arrest in the distal femoral physis, 2 in the proximal tibial physis. All patients were evaluated clinically and radiographically with standard 2-plane standing radiographs using long cassettes, orthoroentgenograms for measurement of leg length inequalities and left hand radiographs for assessing skeletal age (12). If there were clinical signs of rotational deformity, measurement of rotation was performed with a CT scan. The mechanical axis was drawn on the standing full-leg frontal radiograph as a straight line from the center of the hip joint to the center of the ankle joint, and the mechanical axis deviation (MAD) was assessed by comparing the injured side with the normal limb. Based on the malalignment- and malorientation-tests, as

described by Paley (23), the deformity parameters were measured on the radiographs and the CORA (center of rotation of angulation) determined. As a result of the physal injury with partial arrest, the CORA was located in the injured physis in all our patients. The remaining longitudinal growth potential of the affected physis was quantified based on skeletal age (12) and the Green-Anderson remaining growth chart (2).

Epiphysiodesis of the intact part of the injured growth plates was performed with a percutaneous technique as described by Bowen and Johnson (6). Preoperatively planned and fitted configurations of the Ilizarov or Taylor Spatial Frame (TSF) were applied. In order to avoid translation of the fragments the osteotomies were performed as close as possible to the CORA. After 7 days of latency gradual correction was initiated with a lengthening rate of 1 mm/day in the femur and 0.75 mm/day in the tibia. All patients were overcorrected in lengthening distance according to the estimated LLD at maturity.

RESULTS

All deformity parameters were fully corrected in all patients and the frames were removed after bony consolidation. The median time in the frame was 6.5 months (range : 4 to 8), resulting in a lengthening index of 1.6 months/cm (range : 0.9 to 2.0). In some of the patients oral antibiotics were indicated in short periods due to pin-track infection. One patient developed a valgus deformity in the proximal tibial lengthening zone, because of failure in frame stability, probably due to pin track infection. This patient was later corrected by an additional TSF procedure. One patient was operated for a knee extension contracture a few months after frame removal. Another patient underwent a triple-arthrodesis due to a posttraumatic foot deformity on the same side where lengthening of the femur was performed. This procedure might have influenced final leg length in some degree. No other complications were observed. The patients were followed until skeletal maturity and full-leg standing radiographs and orthoroentgenograms for measurement of leg lengths and inequalities were obtained. All patients had regained a normal functional level. They had no clinical or radiological signs of angular deformity in the affected limb. At skeletal

Table I. — Deformity parameters at the time of surgery, estimated LLD at maturity, amount of overcorrection and LLD at maturity for all patients. Age and skeletal age are given in years/month. Numbers for varus, valgus, procurvatum, recurvatum, internal and external rotation are given in degrees (°). LLD and amount of overcorrection are given in mm. Numbers for LLD at maturity refer to the operated extremity. (+) operated side is longer than contralateral side, (–) operated side is shorter than contralateral side at maturity

Pat. nr.	Age (yrs)/ Gender	Skel. age		Deformity parameters							LLD	Estimated LLD at maturity	Over-correction	LLD at maturity
				Varus	Valgus	Pro.	Rec.	Int. rot	Ext. rot					
1	14/0 m	14/2	femur		11	20					43	69	12	+9
2	12/9 m	13/4	tibia	18							40	55	15	+8
3	13/4 f	13/0	tibia		5		28	14			18	25	7	–4
4	14/1 m	14/0	femur		24	4					60	75	15	+3
5	11/9 f	12/4	femur		20		20				30	45	15	–13

maturity four patients had less than 10 mm (range : 3 to 9) of LLD, whereas one patient had a LLD of 13 mm (table I). All deformity parameters were fully corrected in all patients. MAD was within ± 5 mm compared to the healthy side in 4 patients, whereas one patient had a medial mechanical axis deviation of 20 mm. Figures 1-5 show the patients' standing full-leg radiographs before and after correction.

DISCUSSION

Deformities in the lower limb might cause secondary compartmental osteoarthritis in adjacent joints due to deviation of the mechanical axis, and leg length discrepancy can lead to spinal disorders and gait abnormalities (4,14,16,30). The risk of compartmental osteoarthritis is more present in the knee joint than in the hip or ankle joint. The knee joint is a hinge joint with limited ability to compensate for deformities and deviation of the mechanical axis, whereas the hip joint as a ball in socket joint and the ankle joint with its underlying subtalar joints have greater abilities for compensation. Physeal injuries in the lower extremity are most frequent in the proximal tibia and the distal femur (8,22) ; resulting deformities affect the mechanical axis more than deformities close to the ankle or hip joint.

From our point of view, the nature of the deformities in this study with severe angulation and shortening required a combined reconstructive

procedure including both angular correction and adjustment of bone length. Acute corrective osteotomy on the affected side combined with epiphysiodesis or acute shortening on the contralateral side to gain leg length equality was not considered to be appropriate. The high degree of valgus both in the femoral and tibial deformities limited the possibility of acute correction due to possible traction injury to the peroneal nerve. Secondly, a shortening procedure would affect standing height at maturity and was therefore considered to be unfavourable by our patients. Resection of the physeal bridges only was not indicated due to the high degree of angular deformity. Spontaneous correction of the deformities after bridge resection was unlikely. In some cases resection of physeal bridges might be beneficial, but it remains unpredictable, with poor and fair results ranging from 15% to 38% success rate (13,15,17). Physeal distraction shows controversial results both experimentally and clinically with frequent premature complete physeal closure after distraction of the physis (5,7,18).

We considered epiphysiodesis of the remaining part of the injured physis in combination with gradual deformity correction with axial lengthening as the most appropriate treatment option. In the past similar cases were frequently treated using the Ilizarov device (1,11,29). Several recent reports show the use of the distraction method with TSF (9,10,21, 26,28). However, there are no reports describing the use of the Ilizarov method in combination with

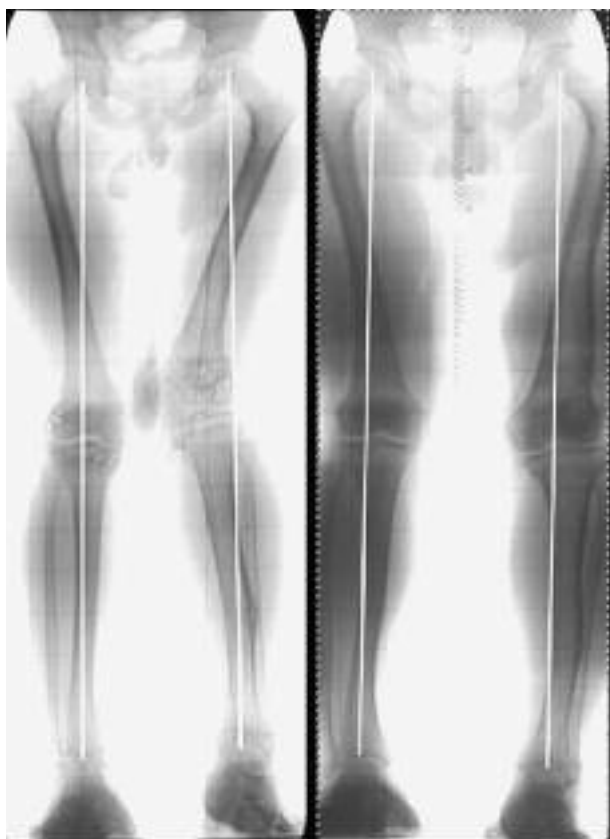

Fig. 1. — Patient with partial physeal arrest in the distal lateral femoral physis after a car accident. Left : Preoperatively. Right : After correction, at skeletal maturity.

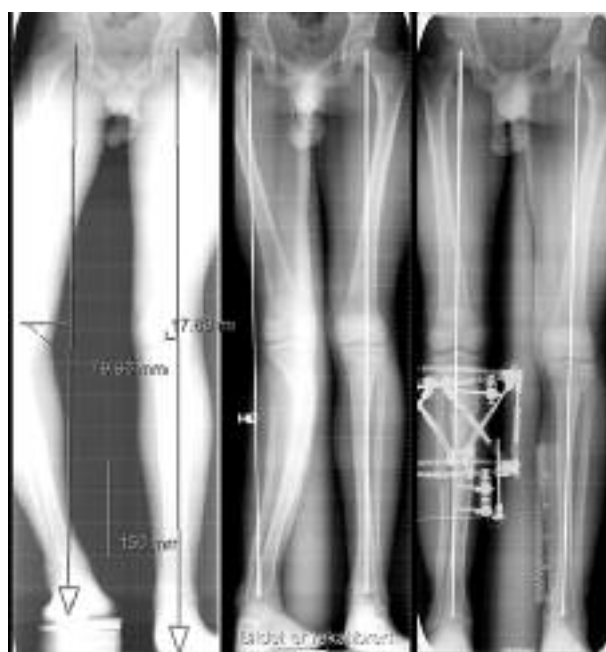


Fig. 2. — Patient with partial physeal arrest at the proximal tibial physis after osteomyelitis (left). First operation resulted in an overcorrection into valgus due to failure of the external fixator (middle). A second correction with TSF was performed in order to achieve correct alignment of the extremity (right).

epiphysiodesis and corrective lengthening osteotomy in patients with deformities due to partial physeal arrest and a significant amount of remaining growth. All our patients had symptomatic deformities with knee pain and a significantly reduced activity level. Without surgical intervention the remaining growth potential in the injured physis would have resulted in exacerbation of symptoms and deformity until skeletal maturity. We considered therefore that correction was indicated before skeletal maturity, although this required complete epiphysiodesis of the injured physis and an appropriate overcorrection of the length. Four out of five patients showed a LLD below 10 mm at maturity and do not need any form of compensation, whereas one patient had a LLD of 13 mm and might need an adjustment by use of an insole.

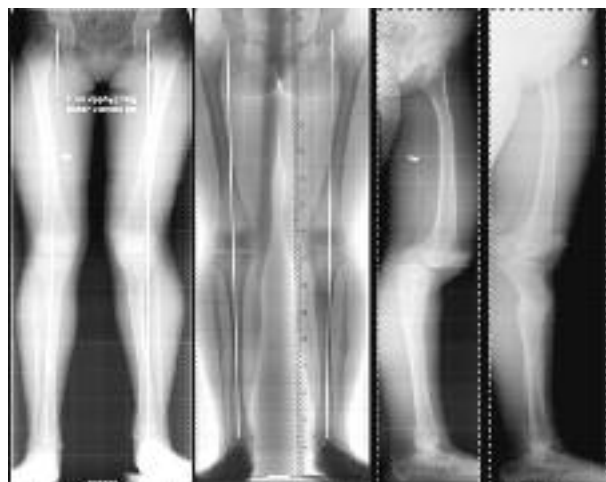


Fig. 3. — Patient with partial physeal arrest anteriorly in the proximal tibial physis after a traumatic knee dislocation. Left : Preoperative frontal view. Middle : Frontal view after the correction. Right : Sideview before and after the correction.

Nevertheless, our investigation showed some clear limitations. One patient (fig 1) underwent a triple arthrodesis on the lengthened extremity ; this

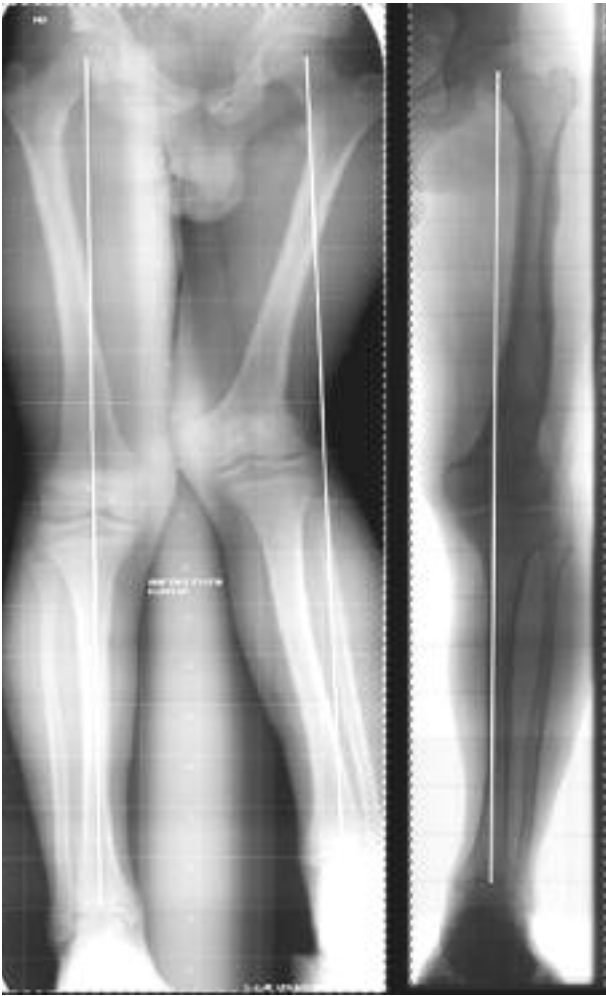

Fig. 4. — Patient with lateral partial physeal arrest after distal femoral fracture. Left : Preoperatively. Right : After the correction, at skeletal maturity.

might have influenced final leg length to some degree. Furthermore, our report is based on five patients only. However, patients with partial physeal arrest and such advanced stages of deformities when treatment is initiated are rare. Predictions of remaining growth were made based on Green and Anderson's growth chart. Other, more sophisticated, methods for leg length prediction like Moseley's (20) or Paley's method (24) might have given more accurate results.

However, our study shows that in cases of partial physeal arrest with severe symptomatic deformities,

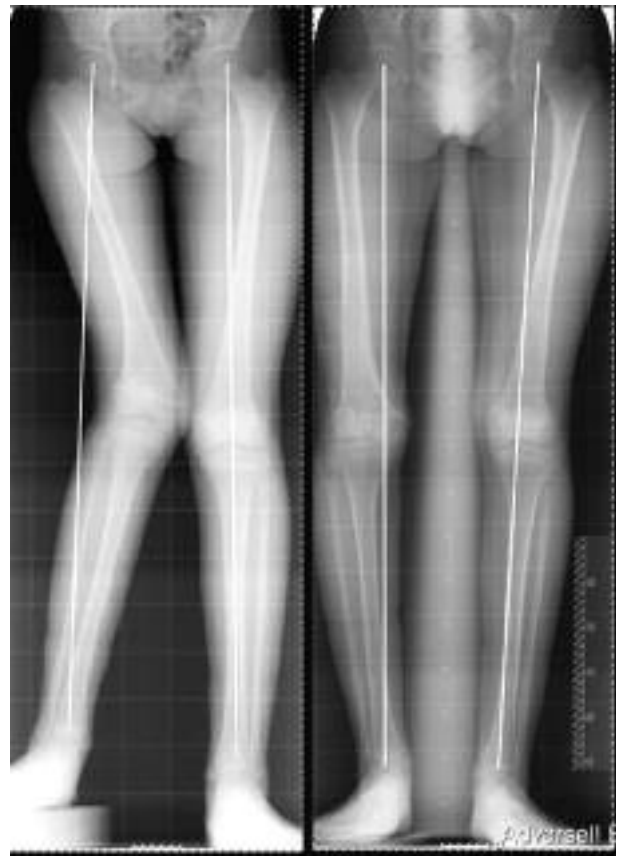

Fig. 5. — Patient with partial physeal arrest at lateral and anterior part of the right distal femoral physis. Left : Preoperative full-leg standing radiograph with severe valgus deformity and shortening. Right : After correction, with slight overcorrection into varus angulation.

complete epiphysiodesis of the injured physis, angular correction and lengthening with the Ilizarov method with overcorrection of length according to estimated loss of remaining growth of the affected physis is a suitable method. Worsening of symptoms and deformity during growth can be prevented, and existing deformity can be fully corrected.

REFERENCES

1. Aaron AD, Eilert RE. Results of the Wagner and Ilizarov methods of limb-lengthening. *J Bone Joint Surg* 1996 ; 78-A : 20-29.
2. Anderson M, Green WT, Messner MB. Growth and predictions of growth in the lower extremities. *J Bone Joint Surg* 1963 ; 45-A : 1-14.

3. **Beck A, Kinzl L, Ruter A et al.** [Fractures involving the distal femoral epiphysis. Long-term outcome after completion of growth in primary surgical management.] (in German). *Unfallchirurg* 2001 ; 104 : 611-616.
4. **Bhave A, Paley D, Herzenberg JE.** Improvement in gait parameters after lengthening for the treatment of limb-length discrepancy. *J Bone Joint Surg* 1999 ; 81-A : 529-534.
5. **Bjerkreim I.** Limb lengthening by physal distraction. *Acta Orthop Scand* 1989 ; 60 : 140-142.
6. **Bowen JR, Johnson WJ.** Percutaneous epiphysiodesis. *Clin Orthop* 1984 ; 190 : 170-173.
7. **de Pablos J, Villas C, Canadell J.** Bone lengthening by physal distraction. An experimental study. *Int Orthop* 1986 ; 10 : 163-170.
8. **Eid AM, Hafez MA.** Traumatic injuries of the distal femoral physis. Retrospective study on 151 cases. *Injury* 2002 ; 33 : 251-255.
9. **Fadel M, Hosny G.** The Taylor spatial frame for deformity correction in the lower limbs. *Int Orthop* 2005 ; 29 : 125-129.
10. **Feldman DS, Madan SS, Koval KJ et al.** Correction of tibia vara with six-axis deformity analysis and the Taylor Spatial Frame. *J Pediatr Orthop* 2003 ; 23 : 387-391.
11. **Ghoneem HF, Wright JG, Cole WG et al.** The Ilizarov method for correction of complex deformities. Psychological and functional outcomes. *J Bone Joint Surg* 1996 ; 78-A : 1480-1485.
12. **Greulich WW, Pyle SI.** *Radiographic Atlas of Skeletal Development of the Hand and Wrist.* Stanford University Press, 1959.
13. **Hasler CC, Foster BK.** Secondary tethers after physal bar resection : a common source of failure ? *Clin Orthop* 2002 ; 405 : 242-249.
14. **Kakushima M, Miyamoto K, Shimizu K.** The effect of leg length discrepancy on spinal motion during gait : three-dimensional analysis in healthy volunteers. *Spine* 2003 ; 28 : 2472-2476.
15. **Kasser JR.** Physal bar resections after growth arrest about the knee. *Clin Orthop* 1990 ; 255 : 68-74.
16. **Kettelkamp DB, Hillberry BM, Murrish DE et al.** Degenerative arthritis of the knee secondary to fracture malunion. *Clin Orthop* 1988 ; 234 : 159-169.
17. **Khosshal KI, Kiefer GN.** Physal bridge resection. *J Am Acad Orthop Surg* 2005 ; 13 : 47-58.
18. **Langlois V, Laville JM.** [Physal distraction for limb length discrepancy and angular deformity.] (in French). *Rev Chir Orthop* 2005 ; 91 : 199-207.
19. **Makela EA, Vainionpaa S, Vihtonen K et al.** The effect of trauma to the lower femoral epiphyseal plate. An experimental study in rabbits. *J Bone Joint Surg* 1988 ; 70-B : 187-191.
20. **Moseley CF.** A straight-line graph for leg-length discrepancies. *J Bone Joint Surg* 1977 ; 59-A : 174-179.
21. **Nakase T, Ohzono K, Shimizu N et al.** Correction of severe post-traumatic deformities in the distal femur by distraction osteogenesis using Taylor Spatial Frame : a case report. *Arch Orthop Trauma Surg* 2006 ; 126 : 66-69.
22. **Ogden JA.** Skeletal growth mechanism injury patterns. *J Pediatr Orthop* 1982 ; 2 : 371-377.
23. **Paley D.** *Principles of Deformity Correction.* Springer, Berlin Heidelberg New York, 2005.
24. **Paley D, Bhave A, Herzenberg JE et al.** Multiplier method for predicting limb-length discrepancy. *J Bone Joint Surg* 2000 ; 82-A : 1432-1446.
25. **Peterson HA, Madhok R, Benson JT et al.** Physal fractures : Part 1. Epidemiology in Olmsted County, Minnesota, 1979-1988. *J Pediatr Orthop* 1994 ; 14 : 423-430.
26. **Rozbruch SR, Helfet DL, Blyakher A.** Distraction of hypertrophic nonunion of tibia with deformity using Ilizarov/Taylor Spatial Frame. Report of two cases. *Arch Orthop Trauma Surg* 2002 ; 122 : 295-298.
27. **Salter RB.** Injuries of the epiphyseal plate. *Instr Course Lect* 1992 ; 41 : 351-359.
28. **Sluga M, Pfeiffer M, Kotz R et al.** Lower limb deformities in children : two-stage correction using the Taylor spatial frame. *J Pediatr Orthop B* 2003 ; 12 : 123-128.
29. **Stanitski DF, Bullard M, Armstrong P et al.** Results of femoral lengthening using the Ilizarov technique. *J Pediatr Orthop* 1995 ; 15 : 224-231.
30. **Tetsworth K, Paley D.** Malalignment and degenerative arthropathy. *Orthop Clin North Am* 1994 ; 25 : 367-377.