

MEDIAN AND ULNAR NERVE COMPRESSION AT THE WRIST CAUSED BY ANOMALOUS MUSCLES

L. DE SMET¹

Compression of the median and ulnar nerves at the wrist is frequently encountered. Carpal tunnel syndrome usually occurs without any obvious extrinsic cause ; several cases have however been reported caused by anomalous or hypertrophic muscles. A survey of the literature shows that compression neuropathy of the median nerve has been reported in relation with anomalies affecting three muscles : the first (or second) lumbrical, the palmaris longus and its anatomic variants and the superficial flexor of the index finger. In the ulnar tunnel the situation is thoroughly different : so-called idiopathic ulnar tunnel syndrome is rare and an extrinsic compressing structure can usually be disclosed. Anomalous muscles belong to the palmaris longus/abductor digiti minimi group ; the flexor carpi ulnaris is sometimes involved.

One can suspect the presence of such an anomalous muscle when the compression syndrome concerns a patient who is not within the “usual” age group with symptoms initiated or aggravated by physical exercise.

Keywords : median nerve ; ulnar nerve ; carpal tunnel ; muscle ; neurocompression.

Mots-clés : nerf médian ; nerf cubital ; canal carpien ; muscle ; compression nerveuse.

and become more vulnerable. At the wrist level the carpal tunnel and Guyon’s canal are such localisations. All structures narrowing the canal or occupying some space within these canals can cause compression neuropathy of the median or ulnar nerve.

Carpal canal syndrome is a frequently encountered condition in middle-aged women ; it is in most cases idiopathic. In all other “atypical” carpal tunnel syndromes, a more extensive search for external causes of the compression is necessary. Ulnar tunnel syndrome is far less frequent. An extrinsic structure is usually responsible for the compression and a systematic search for compressing structures is required (34)

The editor of *Acta Orthopaedica Belgica* receives on a regular basis, case reports describing anomalous muscles in the carpal or ulnar tunnel. Although these observations must not be underestimated, publication is not always possible or recommended, as the existing literature is already extensive, with predominantly case reports published in various journals. The true incidence of muscles anomalies responsible for neurocompression is not known.

INTRODUCTION

Compression neuropathy is a common finding in the upper limb. Persisting compression interferes with the microcirculation and eventually results in fibrosis of the epineurium. There are several areas where nerves pass through unyielding surroundings

¹ Hand Unit, Orthopaedic Department, U.Z. Pellenberg, Weligerveld 1, 3212 Lubbeek, Belgium.

Correspondence and reprints : Luc De Smet, Hand Unit, Orthopaedic Department, U.Z. Pellenberg, Weligerveld 1, 3212 Lubbeek, Belgium. E-mail : luc.desmet@uz.kuleuven.ac.be.

We organized a search within the index of several classical handbooks, the MEDLINE files and the reference list of each retrieved article ; the different anomalous muscles described were grouped with respect to the nerve involved. Each muscle description and photograph was studied and we listed most of the reported muscle anomalies which were found responsible for neurocompression at the wrist level. We may have missed occasional cases hidden in review articles or reported in non-referred journals ; anatomical studies without clinical relevance were not included in this survey.

Still and Kleinert (59) reported a series of 9 cases of which 8 presented with a neurocompression : a carpal tunnel syndrome in 6 cases, an ulnar tunnel syndrome in one and compression of both nerves in another ; the anomalies involved the palmaris longus in 4 cases, the flexor digitorum superficialis in two and abnormal lumbricals in another two cases.

Brown *et al.* (10) found an intriguing correlation between muscle anomalies and rheumatoid arthritis : 6 of 11 rheumatoid arthritis patients with carpal tunnel syndrome had muscular anomalies involving the palmaris longus in 4 cases and the flexor digitorum superficialis in two. No such anomalies were found in 150 so-called idiopathic carpal tunnel syndromes.

The purpose of this review is to survey the most frequently described muscular anomalies causing carpal and/or ulnar tunnel syndrome.

Carpal tunnel

The pathogenesis of carpal tunnel syndrome is varied. In most cases no specific cause can be disclosed ; these cases are usually termed "idiopathic" or "primary". Secondary carpal tunnel syndrome can be caused by various conditions (table I). Abnormal or aberrant muscles have been well described, particularly in manual workers. These anomalous muscles may be hypertrophic or abnormal lumbricals, a hypertrophic flexor digitorum superficialis or an abnormal palmaris longus (profundus or reversed). All these muscles compromise the available space in the carpal canal, resulting in compression of the median nerve.

Table 1. — Overview of causes of carpal tunnel syndrome

Anatomy	
Decreased size	Structural small-sized carpal tunnel
	Abnormalities of carpal bones
	Acromegaly
	Extension/flexion of the wrist
Increased content	Fractures wrist (& forearm)
	(Sub)luxation of carpal bones
	Osteoarthritis (osteophytes)
	Musculotendinous variants
	Anomalous muscles
	Persistent median artery
	Hematoma
	Hypertrophied synovium
Physiology	
Neuropathic conditions	
	Diabetes
	Alcoholism
	Double crush
	Industrial solvents
	Medication
Inflammatory pathology	
	Rheumatoid arthritis
	Gout
	Nonspecific
	Infectious synovitis
	Overuse
Alteration of fluid balance	
	Pregnancy
	Menopause
	Eclampsy
	Contraceptive medication
	Thyroid disorders
	Renal failure
	Hemodialysis
	Obesity
	Raynaud
	Lupus erythematosus
	Sclerodermia
	Amyloidosis
	Paget
External forces	
	Vibration
	Direct pressure

Lumbrical muscle(s)

We found 10 papers (4, 8, 11, 18, 25, 45, 54, 59, 63, 67) describing 13 patients with carpal tunnel syndrome probably caused by hypertrophic or abnormal lumbrical muscles. Most of these patients

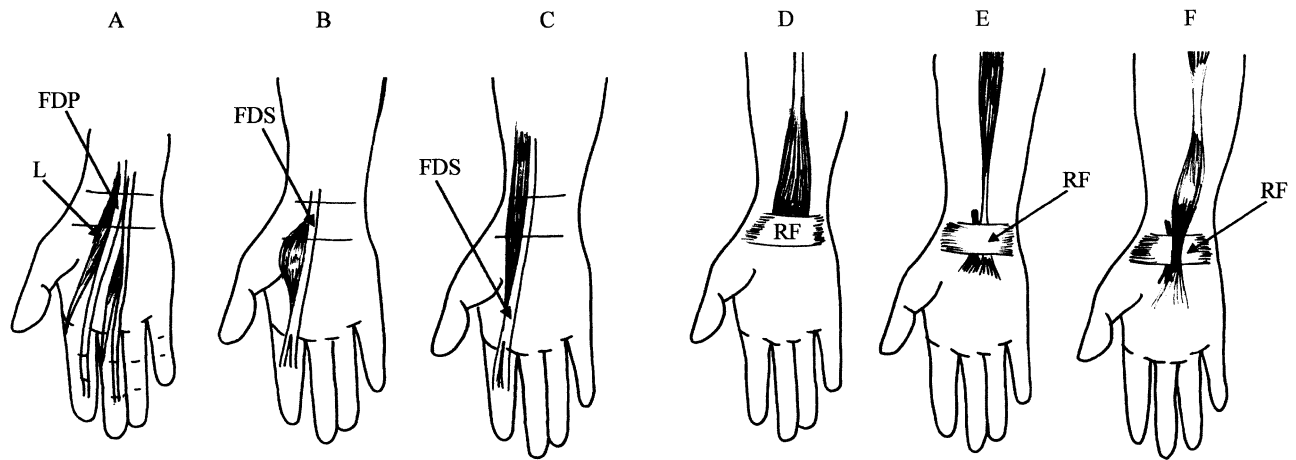


Fig. 1a. — Hypertrophic lumbrical muscle (L) originating from the tendon of the deep flexor of the index (FDP).
1b. — Abnormal muscle belly of the superficial flexor (FDS) of the index.
1c. — Hypertrophic FDS of the index.
1d. — Reversed palmaris longus : origin on the proximal border of the retinaculum flexorum (RF) and a tendon inserting on the medial epicondyle.
1e. — Palmaris profundus : origin from the deep fibro-osseous structures at the proximal third of the palmar surface of the radius. Insertion into the undersurface of the palmar aponeurosis.
1f. — Palmaris longus digastricus : a muscle-tendon-muscle-tendon unit.

however fall into the “classical” age group, except the cases of Robinson *et al.* (45) which were all in male and manually active individuals and the case of Asai *et al.* (4) which was in a child with a very bizarre configuration of the origin of the lumbrical muscles and cystic degeneration of the tenosynovium. The first or second lumbrical muscle is usually held responsible for the compression.(fig. 1a).

The relationship of the lumbrical muscles and the carpal tunnel was investigated by Cobb *et al.* (13). They found on cadavers that incursion of the lumbricals into the carpal canal during flexion of the fingers is a normal occurrence. It may be a possible cause of occupation-related carpal tunnel syndrome.

This finding explains the majority of the above mentioned cases : anomalous muscles may be an accidental finding during routine carpal tunnel decompression, but it may be a causative factor in manual workers.

M.flexor digitorum superficialis (fig. 1b, 1c)

Anomalies of the muscle belly of the flexor digitorum superficialis of the index as a cause for com-

pression of the median nerve were reported and well described in 9 patients, 8 females and one male, all between 22 and 29 years of age except one 52-year-old female (1, 3, 22, 23, 28, 29, 30, 41, 57). In two of them the muscle belly was hypertrophic (fig. 1c) and engaged into the carpal canal, compressing the median nerve (1, 22) ; in the others an abnormal muscle belly originated in the palm and inserted onto the superficial flexor tendon of the index (fig. 1b). Resection of this muscle belly seems to be necessary in such cases.

Abnormal palmaris longus tendon (fig. 1d, 1e, 1f)

The palmaris longus muscle is without any doubt the most variable muscle in the forearm. It can be absent (15% of all patients, more on the left side and in women), hypertrophic, reversed (muscle belly distal rather than proximal), centrally placed, digastric, duplicated or bifid. It can be located deep to the transverse ligament (palmaris profundus). Anomalies in origin and insertion have been described and particular accessory insertion slips are well recognized (palmaris accessorius). The palmaris longus is in the superficial layer of the flexor-pronator muscle mass originating from

the medial humeral epicondyle ; it may be connected with the abductor digiti minimi (and flexor digiti minimi ?) which is in the superficial layer of the hypothenar muscles. The connection between palmaris longus and hypothenar muscles is the palmaris accessorius which enters Guyon's tunnel and may compress the ulnar nerve (fig. 2). In other species with weightbearing forelimbs, the palmaris longus has an important role, but with evolution it regressed to the usual slim and predominantly tendinous unit found in the human forearm. The numerous anatomical variants of the palmaris longus are probably related to this evolution.

We retrieved 6 papers reporting presence of a palmaris profundus (fig. 1e) (9, 17, 19, 21, 35, 53) in 11 patients. The largest series consisted of 5 patients (53). The question arises whether the palmaris profundus is a substitute for the normal palmaris longus tendon in cases where a palmaris profundus was present, but recent papers found both tendons present in the same wrists (17, 19, 21).

The reversed palmaris longus muscle originates from the proximal border of the retinaculum flexorum and runs proximally towards the medial epicondyle (fig. 1d). Its muscle belly may impinge on the median nerve proximal to the carpal canal. Nine publications reporting 17 cases were retrieved (5, 6, 10, 14, 16, 28, 37, 50, 51, 52, 59).

The case described by Carroll and Montero (12) is even more peculiar and consists of a reversed palmaris profundus.

According to Still and Kleinert (59) and Depuydt *et al.* (14) the diagnosis can be suspected when the patients are not in the classical age group for carpal tunnel syndrome, when soft tissue swelling proximal to the carpal canal is present and mostly when the symptoms are induced or aggravated by manual labour, sports and exercises.

Sophisticated imaging has been suggested for diagnosis but in the case of Depuydt *et al.* the abnormal muscle was only identified intra-operatively.

A recent report however provides a nice illustration of an abnormal palmaris longus muscle, compressing both median and ulnar nerve on MRI (69)

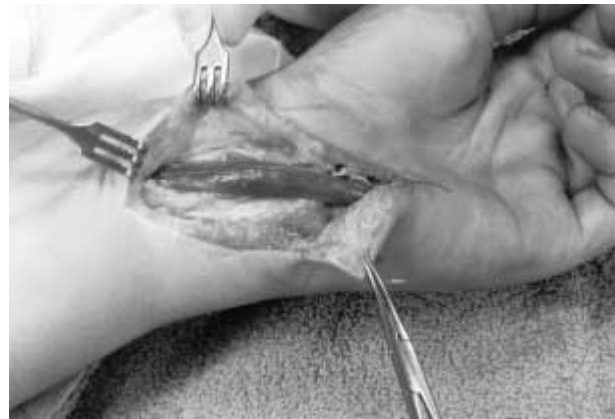

Fig. 2. — A palmaris accessorius muscle crossing Guyon's canal.

Ulnar tunnel

Symptoms due to compression of the median nerve are mostly due to entrapment at the wrist level. Compression of the ulnar nerve is far more frequent at the cervical spine and elbow level than at the wrist. Contrary to the carpal tunnel syndrome, an extrinsic cause is usually responsible for the pathology. Trauma, repetitive stress and synovial cysts are the most frequent causes but anomalous muscles may also be found on exploration of the ulnar nerve in Guyon's canal. These may be an abnormal palmaris longus (reversed or accessory), abnormal hypothenar muscles (duplication or abnormal insertion) and an aberrant flexor carpi ulnaris.

The palmaris longus-abductor digiti minimi complex (fig. 3)

The anatomy of Guyon's canal and the incidence of variants has been studied by Dodds *et al.* in 1990 (15). Based on 58 dissections they found anomalous muscles in 13 (a 22.4% incidence). These were often present bilaterally. They all inserted on the ulnar side of the fifth finger and followed the course of the abductor digiti minimi. Their origin however was variable, mostly the antebrachial fascia. The author called these muscles accessory abductor digiti minimi. The relationship between

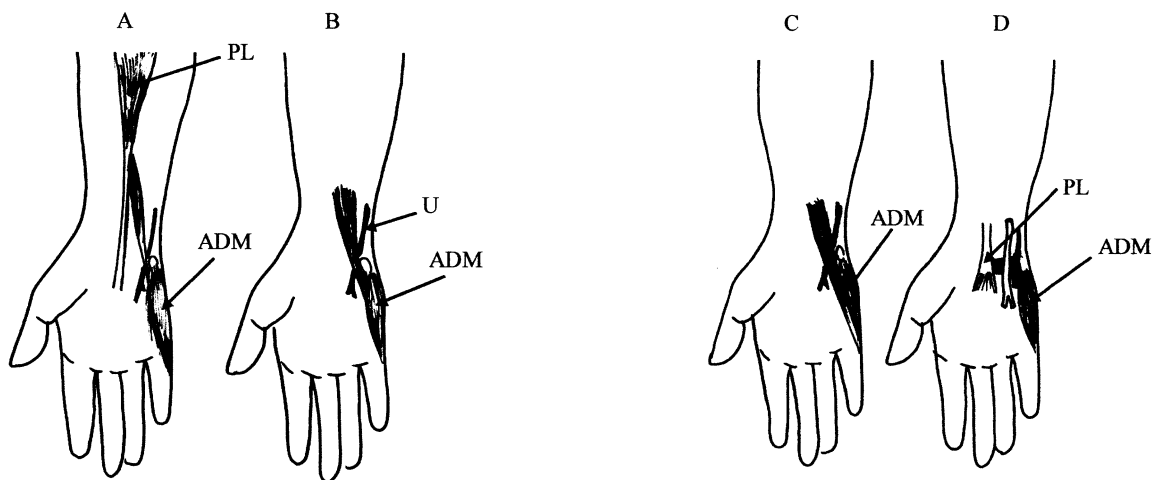


Fig. 3a. — Palmaris accessorius. Origin from the tendon of the palmaris longus ; Insertion into the muscle mass of the abductor digiti minimi.

3b. — Abductor digiti minimi longus : origin from the antebrachial fascia ; Insertion in the muscle mass of the abductor digiti minimi.

3c. — Flexor digiti minimi brevis profundus : origin on the antebrachial fascia ; Insertion on the lateral side of the fifth finger.

3d. — Palmaris brevis profundus. Muscle belly parallel to the palmaris brevis but deep of the ulnar artery and/or ulnar nerve or even between the deep and superficial branch of the ulnar nerve.

the palmaris longus and the abductor digiti minimi is clear : both belong to the superficial layer of the pronator/flexor group and it is obvious that the abnormal connections are either an anomalous palmaris longus or an anomalous abductor digiti minimi ; the distinction between both is not always clear without extensive dissection. Out of the 11 clinical cases of proven ulnar tunnel syndrome in the series of Netscher and Cohen (40), 3 had an anomalous muscle, in all cases an accessory abductor digiti minimi. Although numerous cases have been reported, not all however have been adequately described (2, 26, 38, 55).

Several case reports were critically analyzed. Based on the photographs and the description in the texts we found muscles originating from the antebrachial fascia, at different levels – the accessory abductor digiti minimi or the abductor digiti minimi longus (fig. 3b) (3, 31, 36, 39, 56, 60, 64, 67), the accessory flexor digiti minimi (fig. 3c) (49, 65) – or from the (deep side of) the palmaris longus – the accessory palmaris longus (fig. 2, 3a) (24, 43, 46, 50, 61) – or even from the flexor carpi radialis tendon (68).

In the same area and probably from the same developmental origin is the M. palmaris brevis profundus : a muscle crossing transversally Guyon’s canal, separating the ulnar nerve and artery (fig. 3d) (19, 39, 48, 62, 64).

One case report describes a palmaris profundus (see above) (44).

Flexor carpi ulnaris

Despite the close relationship of M. flexor carpi ulnaris with the ulnar neurovascular bundle, this muscle does not seem to be frequently involved in ulnar tunnel syndrome : hypertrophy was reported once (27) and perforation of (a branch of) the ulnar nerve through the flexor carpi ulnaris was reported in 3 cases (32, 42, 70).

Other muscles

We found one case report of an anomalous flexor digitorum superficialis muscle-tendon unit with ulnar nerve compression (47).

All of these muscle anomalies were mostly incidental findings during surgical exploration.

CONCLUSIONS

All space-occupying lesions can compromise the free course of a nerve in an anatomically limited tunnel. So do anomalous, aberrant or hypertrophied muscles. In patients not belonging to the so-called typical population for carpal tunnel syndrome, in patients with an ulnar tunnel or (younger) patients with a neurocompression syndrome related to physical activity, the treating physician should be aware of the possibility of such a pathology. On the other hand general treatment principles remain applicable, but a more scrupulous dissection of the involved tunnel and sometimes an extended approach is required. The systematic use of sophisticated imaging techniques is however mostly overshooting and not relevant.

REFERENCES

1. Aghasi M., Rzetelny V., Axer A. The flexor digitorum superficialis as a cause of bilateral carpal tunnel syndrome and trigger wrist. *J. Bone Joint Surg.*, 1980, 62-A, 134-135.
2. Al Qattan M. Accessory abductor digiti minimi muscle originating proximal to the wrist causing symptomatic ulnar nerve compression. *Ann. Plast. Surg.*, 1993, 30, 480.
3. Ametewee K., Harris A., Samuel M. Acute carpal tunnel syndrome produced by anomalous flexor digitorum superficialis indicis muscle. *J. Hand Surg.*, 1985, 10-B, 83-84.
4. Asai M., Wong A., Matsunaga T., Akahoshi Y. Carpal tunnel caused by an aberrant lumbrical muscle associated with cystic degeneration of the tenosynovium. *J. Hand Surg.*, 1986, 11-A, 218-221.
5. Ashby B. Hypertrophy of the palmaris longus muscle. *J. Bone Joint Surg.*, 1964, 46-B, 230-232.
6. Backhouse K., Churchill-Davidson D. Anomalous palmaris longus muscle producing carpal tunnel like compression. *Hand*, 1975, 7, 22-24.
7. Banther B., Bigley E. Aberrant index first lumbrical associated with carpal tunnel syndrome. *J. Bone Joint Surg.*, 1971, 53-A, 160.
8. Barton N. Another cause of median nerve compression by a lumbrical muscle in the carpal canal. *J. Hand Surg.*, 1979, 4, 189-191.
9. Brones M., Wilgis E. Anatomical variations of the palmaris longus causing carpal tunnel syndrome. *Plast. Reconstr. Surg.*, 1978, 62, 798-800.
10. Brown F., Morgan G., Taylor T., O'Connors G. Coexistence of muscle anomalies and rheumatoid arthritis in patients with carpal tunnel syndrome. *Clin. Experim. Rheumatol.*, 1984, 2, 297-302.
11. Butler B., Bigley E. Aberrant index lumbrical tendinous origin associated with carpal canal syndrome. *J. Bone Joint Surg.*, 1971, 53-A, 160-162.
12. Carroll M., Montero C. Rare anomalous muscle cause of carpal tunnel syndrome. *Orthop. Rev.*, 1980, 9, 83-85.
13. Cobb T., An K., Cooney W., Berger R. Lumbrical muscle incursion into the carpal tunnel during finger flexion. *J. Hand Surg.*, 1994, 19-B, 434-438.
14. Depuydt K., Schuurman A., Kon M. Reversed palmaris longus muscle causing effort-related median nerve compression. *J. Hand Surg.*, 1998, 23-B, 117-119.
15. Dodds A., Hale D., Jackson T. Incidence of anatomic variants in Guyon's canal. *J. Hand Surg.*, 1990, 15-A, 352-355.
16. Dorin D., Mann R. Carpal tunnel syndrome associated with abnormal palmaris longus muscle. *South Med. J.*, 1984, 77, 1210-1211.
17. Dyreby J., Engber W. Palmaris profundus – rare anomalous muscle. *J. Hand Surg.*, 1982, 7, 513-514.
18. Eriksen J. A case of carpal tunnel syndrome on the basis of an abnormally long lumbrical muscle. *Acta Orthop. Scand.*, 1973, 44, 275-277.
19. Faher M., Millroy P. Ulnar compression neuropathy due to an anomalous abductor digiti minimi. *J. Hand Surg.*, 1981, 6, 266-268.
20. Fatah M. Palmaris profundus of Frohse and Frankel in association with carpal tunnel syndrome. *J. Hand Surg.*, 1984, 9-B, 142-144.
21. Floyd T., Burger R., Sciaroni C. Bilateral palmaris profundus causing bilateral carpal tunnel syndrome. *J. Hand Surg.*, 1990, 15-A, 364-366.
22. Gardner R. Confirmed case and diagnosis of pseudocarpal-tunnel (sublimis) syndrome. *New Eng. J. Med.*, 1970, 282, 858.
23. Gleasson T., Abrham E. Bilateral carpal tunnel syndrome associated with unilateral duplication of the flexor digitorum superficialis muscle. *Hand*, 1982, 14, 48.
24. Gloobe H., Pecket P. An anomalous muscle in the canal of Guyon (a possible ulnar nerve compression). *Anat. Anz.*, 1973, 477-479.
25. Goto S., Kojima T. An anomalous lumbrical muscle with independent muscle belly associated with carpal tunnel syndrome. *Handchir. Mikrochir. Plast. chir.*, 1993, 25, 72-74.
26. Haferkamp H. Ulnariskompression in bereich der Handwurzel. *Langenbecks Arch. Chir. Suppl. Kongressbd.*, 1998, 115, 635-640.
27. Harrelson J., Newman M. Hypertrophy of the flexor carpi ulnaris as a cause of ulnar nerve compression in the distal part of the forearm ? *J. Bone Joint Surg.*, 1975, 57-A, 554-555.
28. Harwin S., Stern R. Carpal tunnel syndrome caused by an anomalous muscle belly. *Orthop. Rev.* 1980, 9, 97-98.
29. Hayes C. Anomalous flexor sublimis muscle with incipient carpal tunnel syndrome. *Plast. Reconstr. Surg.*, 1974, 53, 479-483.

30. Hutton P., Kernohan J., Birch R. An anomalous flexor digitorum superficialis indicis muscle presenting as carpal tunnel syndrome. *Hand*, 1981, 13, 115-118.
31. Jeffrey A. Compression of the deep palmar branch of the ulnar nerve by an anomalous muscle. *J. Bone Joint Surg.*, 1971, 53-B, 718-723.
32. Kang H., Yoo J., Kang E. Ulnar nerve compression due to an anomalous arch of the ulnar nerve piercing the flexor carpi ulnaris. *J. Hand Surg.*, 1996, 21-A, 277-278.
33. Kosta K., Steen M. Der M.abductor digiti minimi longus als Ursache eines distalen Ulnariskompressionsyndroms. *Handchir., Mikrochir. Plast. Chir.*, 1990, 22, 53-54.
34. Lister G. *The Hand : Diagnosis and Indications*. Churchill Livingstone, Edinburgh, 1993, p. 283-323.
35. Lorenzo J., Canada M., Diaz L., Sarasna G. Compression of the median nerve by an anomalous palmaris tendon : A case report. *J. Hand Surg.*, 1996, 21-A, 858-860.
36. Luethke R., Dellon A. Accessory abductor digiti minimi muscle originating proximal to the wrist causing symptomatic ulnar nerve compression. *Ann. Plast. Surg.*, 1992, 28, 307-308.
37. Meyer F., Pflaum B. Median nerve compression at the wrist caused by a reversed palmaris longus muscle. *J. Hand Surg.*, 1987, 12-A, 369-371.
38. Muller L. Anatomical abnormalities in the hand causing ulnar nerve compression. *J. Bone joint Surg.*, 1963, 45-B, 431.
39. Netcher D., Cohen V. Ulnar nerve compression at the wrist secondary to anomalous muscles. *Ann. Plast. Surg.*, 1997, 39, 647-651.
40. Netcher D., Cohen V. Ulnar nerve entrapment at the wrist : cases from a hand surgery practice. *South Med. J.*, 1998, 91, 451-456.
41. Neviasser R. Flexor digitorum superficialis indicis and carpal tunnel syndrome. *Hand*, 1974, 6, 155-156.
42. O'Hara J., Stone J. Ulnar neuropathy at the wrist associated with aberrant flexor carpi ulnaris insertion. *J. Hand Surg.*, 1988, 13-A, 370-372.
43. Regan P., Feldberg L., Bailey B. Accessory palmaris longus muscle causing ulnar nerve compression at the wrist. *J. Hand Surg.*, 1991, 16-A, 736-738.
44. Regan P., Roberts J., Bailey B. Ulnar nerve compression caused by a reversed palmaris longus muscle. *J. Hand Surg.*, 1988, 13B, 406-407.
45. Robinson D., Aghasi M., Halperin N. The treatment of carpal tunnel syndrome caused by hypertrophied lumbrical muscles. *Scand. J. Plast. Reconstr. Surg. Hand Surg.*, 1989, 23, 149-151.
46. Robinson D., Aghasi M., Halperin N. Ulnar tunnel syndrome caused by an accessory palmaris muscle. *Orthop. Rev.*, 1989, 18, 345-347.
47. Robinson S. An anomalous flexor digitorum superficialis muscle-tendon unit associated with ulnar neuropathy. *Clin. Orthop.*, 1985, 194, 169-171.
48. Ruocco M., Walsh J., Jackson J. MR imaging of ulnar nerve entrapment secondary to an anomalous wrist muscle. *Skeletal Radiol.*, 1998, 27, 218-221.
49. Salgeback S. Ulnar tunnel syndrome caused by anomalous muscles. *Scand. J. Plast. Reconstr. Surg.*, 1977, 11, 255-258.
50. Santoro T., Matloub H., Gosain A. Ulnar nerve compression by an anomalous muscle following carpal tunnel release. *J. Hand Surg.*, 2000, 25, 740-744.
51. Saraf S. Tuli S. Anomalous m.palmaris longus producing carpal tunnel like syndrome. *Arch. Orthop. Trauma Surg.*, 1991, 110, 173-174.
52. Schlafly B., Lister G. Median nerve compression secondary to bifid reversed palmaris longus. *J. Hand Surg.*, 1987, 12-A, 371-373.
53. Schuhl J. Compression du n.médian au carpe par un petit palmaire intra-canalair. *Ann. Chir. Main*, 1991, 10, 171-174.
54. Schultz R., Endler P., Huddleston H. Anomalous median nerve and an anomalous muscle belly of the first lumbrical associated with carpal tunnel syndrome. *J. Bone Joint Surg.*, 1973, 55-A, 1744-1746.
55. Sejhelderup H. Aberrant muscle in the hand causing ulnar nerve compression. *J. Bone Joint Surg.*, 1964, 46-B, 361.
56. Sheppard J., Prebble T., Rahn K. Ulnar neuropathy caused by an accessory abductor digiti minimi muscle. *Wisconsin Med. J.*, 1991, 90, 628- 631.
57. Smith R. Anomalous muscle belly of the flexor digitorum superficialis causing carpal tunnel syndrome. *J. Bone Joint Surg.*, 1971, 53-A, 1215-1216.
58. Spritzendorfer E. An anatomical variation as an unusual cause of ulnar compression syndrome. *Handchirurgie*, 1979, 11, 177-179.
59. Still J., Kleinert H. Anomalous muscles and nerve entrapment in the wrist and hand. *Plast. Reconstr. Surg.*, 1973, 52, 394-400.
60. Swansson A., Biddulph S., Baugman F., De Groot G. Ulnar nerve compression due to an anomalous muscle in the canal of Guyon. *Clin. Orthop.*, 1972, 83, 64-69.
61. Thomas C. Clinical manifestations of an accessory palmaris muscle. *J. Bone Joint Surg.*, 1958, 40-A, 929-930.
62. Tonkin M., Lister G. The palmaris brevis profundus : an anomalous muscle associated with ulnar nerve compression at the wrist. *J. Hand Surg.*, 1985, 10-A, 862-864.
63. Touborg-Jensen A. Carpal tunnel syndrome caused by an abnormal distribution of lumbrical muscles. *Scand. J. Plast. Reconstr. Surg.*, 1970, 4, 72-74.
64. Turner M., Caird D. Anomalous muscles and ulnar nerve compression at the wrist. *Hand*, 1977, 9, 140-141.
65. Whaba M., Singh G., Lozanoff. An anomalous accessory flexor digiti minimi. *Clin. Anatomy*, 1998, 11, 55-59.
66. Weeks P., Young V. Ulnar artery thrombosis and ulnar nerve compression associated with an anomalous hypothenar muscle. *Plast. Reconstr. Surg.*, 1982, 69, 130-131.

67. Wiss D., Weinert C. Imbriglia J. Aberrant lumbrical muscles causing carpal tunnel syndrome. *Orthopedics*, 1979, 2, 357-358.
68. Zeine G., Aubart F. Compression du nerf ulnaire au poignet par un muscle surnuméraire. *Chir. Main*, 1998, 17, 334-337.
69. Zeiss J., Jakab E. MR demonstration of an anomalous muscle in a patient with coexistent carpal and ulnar tunnel syndrome. *Clin. Imaging*, 1995, 19, 102-105.
70. Zook E., Kucan J., Guy R. Palmar wrist pain caused by ulnar nerve entrapment in the flexor carpi ulnaris tendon. *J. Hand Surg.*, 1988, 13-A, 732-735.

SAMENVATTING

L. DE SMET. Abnormale spieren als oorzaak van compressie van de n.medianus en ulnaris thv de pols.

Neurocompressie van de n.medianus en n.ulnaris thv de pols is vaak voorkomend. Terwijl van de carpaal tunnel syndroom er meestal geen uitwendige oorzaak kan worden gevonden is dit voor de ulnar tunnel syndroom in het kanaal van Guyon helemaal verschillend.

Voor het carpaal tunnel syndroom moet men erop verdacht zijn wanneer de patiënt niet tot de klassieke leeftijdsgroep behoort en/of wanneer de klachten worden uitgelokt of verergerd door fysieke inspanning. Wij vonden drie groepen spieren als oorzaak voor neurocompressie van de n.medianus: lumbricalen, palmaris

longus en zijn varianten en de flexor superficialis van de index.

Voor neurocompressie van de n.ulnaris in het kanaal van Guyon komt vnl de spiergroep palmaris longus/abductor digiti minimi in aanmerking.

RÉSUMÉ

L. DE SMET. Compressions nerveuses au niveau du poignet en rapport avec des muscles anormaux.

On rencontre souvent des compressions nerveuses au niveau du poignet, portant sur le nerf médian ou le nerf cubital. Le syndrome du canal carpien n'est habituellement pas en rapport avec une cause extrinsèque ; cependant, plusieurs cas ont été rapportés en rapport avec des muscles anormaux ou hypertrophiques. La synthèse des cas rapportés dans la littérature permet de mettre en rapport ces neuropathies par compression du nerf médian avec des anomalies portant sur trois muscles : le premier lombrical, le long palmaire et le fléchisseur propre de l'index. La situation se présente différemment au niveau du canal de Guyon : les formes "idiopathiques" sont rares et c'est habituellement une compression extrinsèque qui est en cause. Parmi elles, on peut rencontrer des muscles anormaux qui font partie de l'ensemble long palmaire court abducteur du petit doigt ; le fléchisseur ulnaire du carpe peut aussi être impliqué.