



Deformity correction and massive lengthening on a centralized fibula with the Ilizarov technique

Altaf A. KAWOOSA, Mohammad F. BUTT, Manzoor A. HALWAI

From the Hospital for Bone and Joint Surgery Barzulla Srinagar, India

Lengthening beyond 25% of the original segment length is an orthopaedic challenge. Substantial lengthening is fraught with complications such as joint contractures, refractures, nerve injuries and prolonged periods of consolidation. We report a case of massive lengthening in a 17-year-old boy in whom a 20 cm lengthening (57% lengthening) and complex deformity correction was performed on a centralized fibula using the Ilizarov technique, with an excellent result. A total of 17 months were taken to complete the process of lengthening and consolidation at a healing index of 0.85 months/cm. Besides a minor pin tract infection, there were no major complications. We believe that with meticulous pre operative planning and follow-up the extent of lengthening can be extended in cases of severe limb length discrepancy.

Keywords : osteomyelitis ; limb lengthening ; Ilizarov technique.

INTRODUCTION

In countries where osteomyelitis is still a common disease, it is not uncommon to find limbs with complex deformities and major length discrepancies. Major defects in the tibia have traditionally been salvaged by Huntington's procedure of fibular centralization. The procedure however does not address the problems of limb length discrepancy, as a result of which the final limb function may be well short of the optimum goal. Ilizarov's technique has produced satisfactory results by not only cen-

tralizing the fibula but also taking care of the limb length discrepancy and associated deformities. Attempts made at substantial lengthening have produced a number of complications (3). While most authors agree that the goals of lengthening should be restricted to 20 to 25% of the initial segment length (6,10,13,14), there are reports of satisfactory results achieved in cases of lengthening beyond 20% also (9,16,17). In some patients the desired length gain needed to maximize the limb function may be substantial. We report such a substantial lengthening and multi-planar deformity correction in a centralized fibula using Ilizarov's technique, with an excellent result.

CASE REPORT

A 17-year-old student consulted for treatment of a severely deformed right leg with major shortening. The patient had an attack of multi-focal

■ Altaf Ahmad Kawoosa, MS Ortho, Lecturer.

■ Mohammad Farooq Butt, MS Ortho, Registrar Orthopaedics.

■ Manzoor Ahmad Halwai, MS Ortho, Associate Professor.
Department of Orthopaedics, Hospital for Bone and Joint Surgery, Barzulla Srinagar Government Medical College Srinagar, India.

Correspondence : Dr. Altaf Ahmad Kawoosa, "Bazaz Manzil" Near Old Post Office Nowshehra, Srinagar, J&K 190011, India. E-mail : draltafk@yahoo.com

© 2008, Acta Orthopædica Belgica.

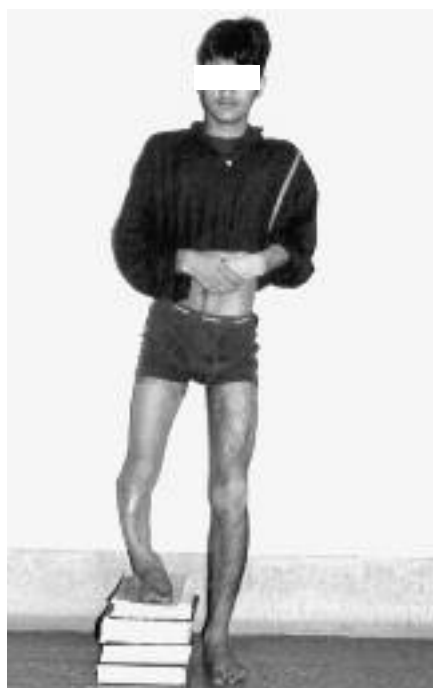

Fig. 1. — Preoperative photograph of the patient showing shortening of his right leg.

osteomyelitis at the age of 9 years. Over the years he had multiple abscess drainages, and was left with a stiff left hip and a severely deformed right leg. Huntington's procedure for centralization of the right fibula had been performed at the age of 11 years. At the time of presentation to our clinic, the patient had an ankylosed left hip and a deformed right leg. On examination a total shortening of 22 cm was calculated with a contribution of 4 cm and 18 cm respectively for the femur and tibia (fig 1). There was a full range of motion at the right hip and knee with no movements at the ankle. The radiograph of the right leg revealed a well-hypertrophied tibialized fibula, however with multi-planar deformities comprising of varus, procurvatum, internal rotation at the proximal end, and the ankle was fused with a varus deformity at the distal end of the centralized fibula (fig 2).

Pre-operative assessment and Planning

Radiographs of the whole limb were taken to assess the deformities and the deranged mechanical

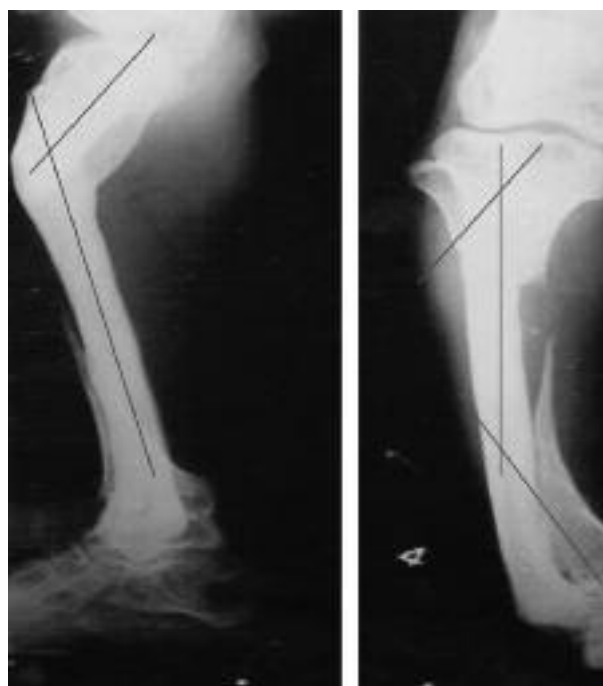


Fig. 2. — Preoperative radiograph of the patient showing deformity and two centers of rotation of angulations (CORA).

axis. An oblique plane deformity at the proximal end comprised of a 45° procurvatum and 30° varus. At the distal end a varus deformity of 20° was found with a fused ankle. The centres of angulations of the deformities were identified in the tibialised fibula (CORA) (fig 2). Osteotomy and hinge construction was planned in such a way as to achieve correction of the deformity and translation to realign the mechanical axis.

Surgery was performed under spinal anaesthesia. After fixing the frame to the centralised fibula using olive wires appropriately, two low-energy corticotomies were performed at the proposed sites already identified (fig 3). The patient was ambulated on the first postoperative day and distraction started on the 5th postoperative day. Once the desired deformity correction was achieved, the hinged rods were replaced by straight graduated rods and lengthening started at both sites at the rate of 0.25 mm four times a day (fig 4). The lengthening procedure was completed in five months. At this time a de-rotation assembly was added to the frame to correct the internal rotation deformity between the distal rings.

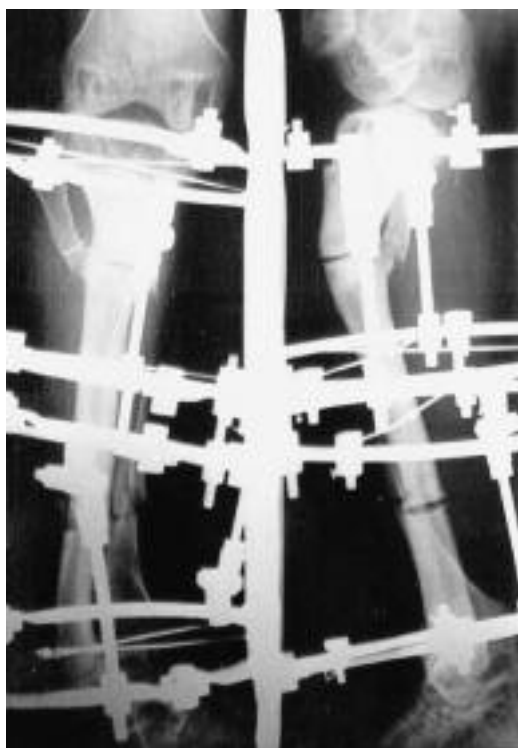

Fig. 3. — Postoperative radiograph : corticotomy performed at two proposed sites.

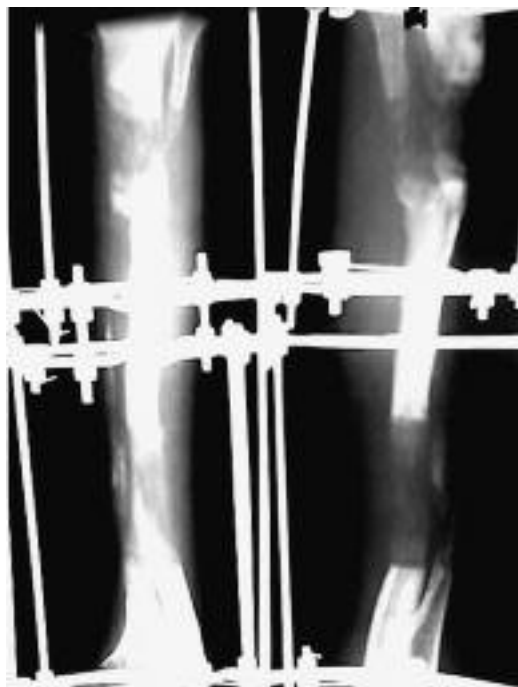

Fig. 4. — Radiograph during lengthening at two sites. Deformity corrected.

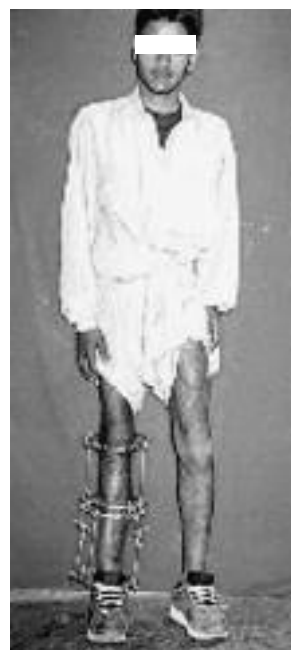

Fig. 5. — Clinical photograph during the period of consolidation.

After length equalization and deformity correction the frame was left in place till consolidation of the regenerate (fig 5). During the whole process of treatment the patient was encouraged to do physiotherapy and weight bearing as tolerated. A total of 20 cm length was achieved in the centralized fibula (fig 6). The patient retained excellent range of motion of the ipsilateral knee (fig 7). It took a total of 17 months for the consolidation of the regenerate and removal of the fixator (fig 8). At the fourth year of follow-up the patient is very happy with the end result of the procedure. Apart from minor pin tract infection, there were no major complications.

DISCUSSION

The deformity in our patient was rated as type 5 according to the classification of Dahl *et al* (2), with one associated greater risk factor of multi site deformity and many complications were therefore anticipated. However the lengthening and deformity correction was achieved without any major complication. The achievement of the desired lengthen-



Fig. 6. — Limb length discrepancy corrected within two cm



Fig. 7. — Clinical photograph showing range of motion of ipsilateral knee.

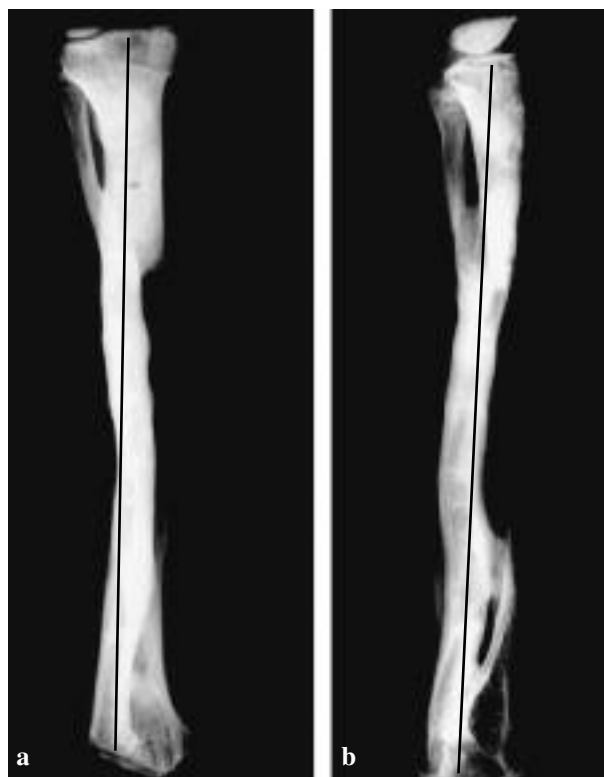


Fig. 8a & b. — Final radiographs showing lengthened centralized fibula.

ing of 20 cm (57% of the original segment length) and simultaneous multiple deformity correction at a healing index of 0.85 months/cm in this patient was remarkable. Most studies in the literature and our own experience reveal modest gains in length (1,4,5, 8,11,12,15). Attempts at more substantial lengthening are associated with a number of complications such as joint contractures, nerve palsies, regenerate fractures and long periods of consolidation. Hantes *et al* (7) observed serious complications in lengthening beyond 30%. To avoid serious complications, Danziger *et al* (3) suggested simultaneous tibial and femoral lengthening for patients requiring extensive lengthening. However Dahl *et al* (2) found the complication rate to drop significantly with increasing experience of lengthening. There are reports of substantial length gains also. Using Ilizarov's technique Javid *et al* (9) achieved an excellent result in lengthening a centralised fibula in congenital tibial hemimelia. A total of 15 cm length was achieved at

a healing index of 0.87 months/cm. The better healing index in our case as well as that of Javid *et al* (10) could be debated on the basis of the high osteogenic potential of the fibula and bifocal lengthening in our patient. The simultaneous deformity correction is a definite advantage with the Ilizarov technique. The ring fixator allows deformity correction in multiple planes. We believe that a meticulous pre operative planning and a keen and watchful follow-up were responsible for the excellent result in our patient. We agree with Yun *et al* (17) that the accepted limits of lengthening can be extended in patients with severe deformities.

REFERENCES

1. **Bonard C, Favard L, Sollogoub I, Glorion B.** Limb lengthening in children using Ilizarov technique. *Clin Orthop* 1993 ; 293 : 83-88.
2. **Dahl MT, Gulli B, Berg T.** Complications of limb lengthening ; a learning curve. *Clin Orthop* 1994 ; 301 ; 10-18.
3. **Danziger MB, Kumar A, DeWeese J.** Fractures after femoral lengthening using Ilizarov method. *J Pediatr Orthop* 1995 ; 15 : 220-223.
4. **Garcia-Cimbrelo E, Olsen B, Ruiz-Yague M, Fernandez-Baillo N, Munuera-Martinez L.** Ilizarov technique : results and difficulties. *Clin Orthop* 1992 ; 283 : 116-123.
5. **Glorion C, Pouliquen JC, Langlais J, Ceolin JL, Kassis B.** Femoral lengthening using callotasis method ; a study of complications in a series of 70 cases in children and adolescents. *J Pediatr Orthop* 1996 ; 16 : 161-167.
6. **Hang YS, Shih JS.** Tibial lengthening ; a preliminary report. *Clin Orthop* 1977 ; 125 : 94-99.
7. **Hantes ME, Malizos KN, Xenakis TA et al.** Complications in limb-lengthening procedures : a review of 49 cases. *Am J Orthop* 2001 ; 30 : 479-483.
8. **Hrutkay JM, Eilert RE.** Operative lengthening of the lower extremity and associated psychological aspects ; the Children's hospital experience. *J Pediatr Orthop* 1990 ; 10 : 373-377.
9. **Javid M, Shahcheraghi H, Noorai H.** Ilizarov lengthening in centralized fibula : *J Pediatr Orthop* 2000 ; 20 : 160-162.
10. **Karger C, Guille JT, Bowen JR.** Lengthening of congenital lower limb deficiencies. *Clin Orthop* 1993 ; 291 : 236-245.
11. **Kawoosa AA, Majid S, Mir MR, Mir GR.** Results of tibial lengthening by Ilizarov technique. *Indian J Orthop* 2003 ; 37 : 164-167.
12. **Kawoosa AA, Majid S, Halwai MA, Mir MR, Mir GR.** Femoral lengthening by Ilizarov technique : results and complications. *JK Science (Jammu, India)* 2004 ; 6 : 163-167.
13. **Macnicol MF, Catto AM.** Twenty-year review of tibial lengthening for poliomyelitis. *J Bone Joint Surg* 1982 ; 65-B : 607-611.
14. **Maffulli N, Lombardi C, Matarazzo L et al.** A review of 240 patients undergoing distraction osteogenesis for post traumatic or post infective lower limb length discrepancy. *J Am Coll Surg* 1996 ; 182 : 394-402.
15. **Malhis TM, Bowen JR.** Tibial and femoral lengthening : a report of 54 cases. *J Pediatr Orthop* 1982 ; 2 : 487-491.
16. **Stanitski DF, Shahcheragi H, Niker DA, Armstrong PF.** Results of tibial lengthening by Ilizarov technique. *J Pediatr Orthop* 1996 ; 16 : 168-172.
17. **Yun AG, Severino R, Reinkeer K.** Attempted limb lengthening beyond twenty percent of the initial bone length : results and complications. *J Pediatr Orthop* 2000 ; 20 : 151-159.