



## Lengthener loosening in a reversed shoulder prosthesis : A case report

Harm W. BOONS, Corne J. VAN LOON, Willard J. RIJNBERG

*From the Rijnstate Hospital, Arnhem, The Netherlands*

**The reverse shoulder prosthesis is designed for the treatment of glenohumeral arthritis with irreparable cuff arthropathy. Although it has given good short term results the prosthesis is not free of complications. In this case report we describe an implant-related complication.**

**Keywords :** reversed shoulder prosthesis ; complications.

### INTRODUCTION

The Delta III reverse shoulder prosthesis (DePuy, Leeds, UK) is used for the treatment of painful glenohumeral arthritis associated with irreparable rotator cuff tears. Glenoidal and humeral components of the prosthesis are reversed to medialise the centre of rotation. This increases the lever arm of the deltoid muscle, making the abduction movement stronger, and stabilises the prosthesis in absence of the rotator cuff (7). Good short and mid-term results for pain relief, function improvement and patient satisfaction have been reported (2,3,5). Nevertheless, there is concern for inferior impingement with inferior glenoidal bone loss, and early glenoidal loosening (4,12,13). Instability with dislocation and stress fractures of the acromion and scapular spine have also been reported (9,10,12). In this case report we describe a patient who sustained a lengthener loosening of a Delta III prosthesis after a fall and underwent revision surgery.

### CASE REPORT

A 67-year-old woman with bilateral irreparable cuff arthropathy and glenohumeral arthritis was operated with a Delta III reverse total shoulder prosthesis on the right dominant arm, which was most painful. Besides mild osteoporosis there was no other co-morbidity. To obtain sufficient joint stability during operation a lateralised retentive 36-mm humeral cup with 9-mm lengthener was placed. Postoperatively the patient did well, there were no complications. After a 12 months period of good functioning of the right shoulder she returned with increased pain and decreased motion. Three months earlier she had fallen from her bicycle on the right arm. Since then she experienced increased pain and a snapping sensation in her right shoulder. Examination revealed a decreased range of motion : active abduction was 30°, compared with 90° nine months postoperatively. During passive abduction a snapping sensation was noted at 60° abduction.

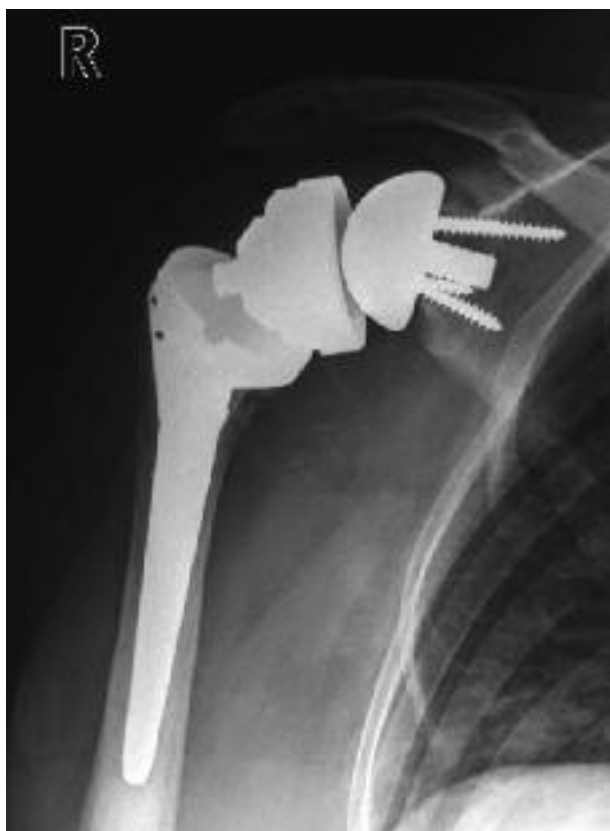- 
- Harm W. Boons, MD, Resident.
  - Corne J. van Loon, MD, PhD, Staff surgeon.
  - Willard J. Rijnberg, MD, PhD, Staff surgeon.

*Orthopaedic department Rijnstate Hospital, Arnhem, The Netherlands.*

Correspondence : Harm W. Boons, MD, Department of orthopaedics, Rijnstate Hospital, P.O. Box 9555, 6800 TA Arnhem, The Netherlands. E-mail : hwboons@hotmail.com

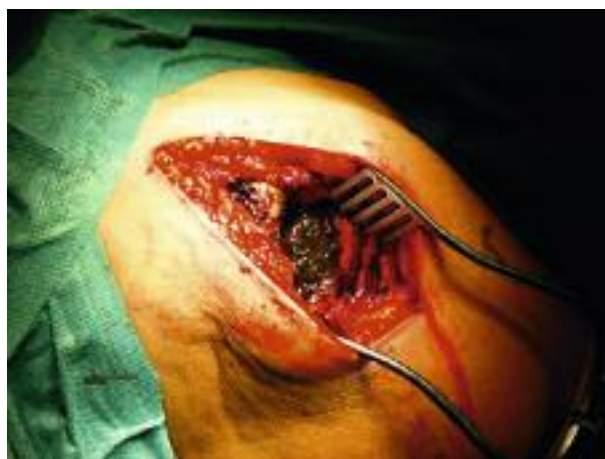© 2008, Acta Orthopædica Belgica.

---



**Fig. 1.** — Loosening of the humeral 9-mm lengthener. Note inferior osteolysis due to impingement of the retentive cup.

Radiography showed loosening of the 9-mm lengthener from the humeral stem (fig 1). The polyethylene insert was still articulating with the glenoid component. During revision operation a severe grey-coloured synovitis was noted (fig 2). A synovectomy was performed and pathological investigation showed severe metallosis and fibrosis. The loose 9-mm lengthener with the retentive polyethylene insert was removed. When inspecting the insert the articulating polyethylene surface was found to have severe wear, and the screw thread of the lengthener was badly damaged (fig 3a, b). The cemented humeral stem and the non-cemented glenoid components were neither damaged nor loose. We noted significant signs of inferior impingement which radiographically could be classified as a grade II notching according to the radiographic scoring system proposed by Valentini *et al* (13). The




**Fig. 2.** — Severe metallosis of the joint synovium


screw thread of the humeral stem was inspected ; it was not grossly damaged. A new 9-mm lengthener and a new lateralised 36-mm retentive humeral cup were inserted. To avoid future re-loosening we added cement during lengthener fixation. Upon testing, the lengthener could not be loosened by manual force. Three months postoperatively the patient did well with VAS scores of 3 for function and 2 for pain (respectively 6 and 7 preoperatively). Average abduction force was 108% compared with the non-operated left side. (28N, MecMesin® myoabduction gauge). Radiographs showed no prosthesis related problems or progress in inferior notching.

## DISCUSSION

The treatment of concomitant irreparable rotator cuff tears and glenohumeral osteoarthritis with a Delta III reversed shoulder prosthesis improves the patients' condition, although serious complications have been reported in literature (5,7,8). Complication rates up to 50% have been reported (14). Prosthesis-related complications most often described affect the glenoid component. In case of an increased lateral offset, greater loads are transferred through the prosthesis bone interface, leading to earlier component loosening (1,8). The 9-mm humeral lengthener is only used in about 10% of all Delta III prosthesis



**Fig. 3a.** — Damaged screw thread of the 9 mm lengthener



**Fig. 3b.** — Anterior inferior damaged polyethylene insert of the lateralised retentive humeral cup.

implantations (De Puy sales information). Use of the 9-mm lengthener is advised in cases with insufficient stability, to increase soft tissue tension, and it is most often used in revision cases. The cause of loosening of the lengthener in our patient is unsure, and unwinding of the humeral lengthener has been reported in one case before (6). Inadequate implantation or insufficient torque by the hexagonal screwdriver during implantation is possible. Loosening may also have been induced by the inferior impingement of the retentive cup or due to the fall on the outstretched arm. The relatively cranial placement of the glenoid component could have increased the inferior notching (11). It is unlikely that the lengthener unwound out of the humeral stem, because of the damage noted on the 9-mm screw thread. A traumatic event is most likely to be the cause of loosening after possible subclinical damage to the screw thread. Forces applied to the prosthesis components during the fall are likely to exceed physiological conditions. We believe that every extra connexion in a Delta III prosthesis hides a potential cause for complications, although there are many benefits to modularity. We advise to pay attention during implantation, that every connection is tightened firmly, especially when there is no torque gauge. Proper mechanical testing will have to tell if this case stands alone, or is an illustration of a problem in the design of the component.

## REFERENCES

1. **Anglin C, Wyss UP, Pichora DR.** Mechanical testing of shoulder prostheses and recommendation for glenoid design. *J Shoulder Elbow Surg* 2000 ; 9 : 323-331.
2. **Baulot E, Chabernaud D, Grammont PM.** Result of Grammont's inverted prosthesis in omarthritis associated with major cuff destruction : a propos of 16 cases. *Acta Orthop Belg* 1995 ; 61 (suppl 1) : 112-119.
3. **Baulot E, Garron E, Grammont E.** Grammont prosthesis in humeral head osteonecrosis : indications – results. *Acta Orthop Belg* 1999 ; 65 (suppl 1) : 109-115.
4. **Boulahia A, Edwards TB, Walch G, Baretta RCV.** Early results of a reverse design prosthesis in the treatment of arthritis of the shoulder in elderly patients with a large rotator cuff tear. *Orthopedics* 2002 ; 25 : 129-133.
5. **Debeer P, Robyns F.** Fracture of the scapular spine in a patient with a Delta III prosthesis. *Acta Orthop Belg* 2005 ; 71 : 612-614.
6. **De Wilde L, Walch G.** Humeral prosthetic failure of reversed total shoulder arthroplasty : a report of three cases. *J Shoulder Elbow Surg* 2006 ; 15 : 260-264.
7. **Grammont PM, Baulot E.** Delta shoulder prosthesis for rotator cuff rupture. *Orthopedics* 1993 ; 16 : 65-68.
8. **Harman M, Frankle M, Vasey M, Banks S.** Initial glenoid component fixation in "reversed" total shoulder arthroplasty : a biomechanical evaluation. *J Shoulder Elbow Surg* 2005 ; 14 Suppl S : 162s-167s.
9. **Jacobs R, Debeer P, De Smet L.** Treatment of rotator cuff arthropathy with a reversed Delta shoulder prosthesis. *Acta Orthop Belg* 2001 ; 67 : 433-437.
10. **Nyffeler RW, Werner CM, Simmen BR, Gerber C.** Analysis of a retrieved Delta III total shoulder prosthesis. *J Bone Joint Surg* 2004 ; 86-B : 1187-1191.

11. **Simovitch RW, Zumstein MA, Lohri E et al.** Predictors of scapular notching in patients managed with the Delta III reverse total shoulder replacement. *J Bone Joint Surg* 2007 ; 89-A : 588-600.
12. **Sirveaux F, Favard L, Oudet D et al.** Grammont inverted total shoulder arthroplasty in the treatment of glenohumoral osteoarthritis with massive and non-repairable cuff rupture. In : Walch G, Boileau P, Mole D. (eds). *2000 Shoulder Prostheses : Two to Ten Year Follow-up*. Sauramps Medical, Montpellier, 2001, pp 247-251.
13. **Valenti P, Boutens D, Nerot C.** Delta 3 reversed prosthesis for osteoarthritis with massive rotator cuff tear : long term results (> 5 years). In : Walch G, Boileau P, Mole D. (eds). *2000 Shoulder Prostheses : Two to Ten Year Follow-up*. Sauramps Medical, Montpellier, 2001, pp 253-259.
14. **Werner CM, Steinmann PA, Gilbert M, Gerber C.** Treatment of painful pseudoparesis due to irreparable rotator cuff dysfunction with the Delta III reversed-ball-and-socket total shoulder prosthesis. *J Bone Joint Surg* 2005 ; 87-A : 1476-1486.