



The Fish Hook Technique of extracting broken intramedullary nails

Mehool ACHARYA, Asef ALANI, Sami ALMEDGHIO

From Leicester Royal Infirmary, Leicester UK

Removal of hardware in orthopaedic surgery is usually encountered in revision fracture surgery for non union, mal union, infection and peri-implant failure. If the hardware has broken this can make revision surgery even more demanding. Numerous techniques have been described to facilitate implant removal. A broken femoral nail is not an uncommon presentation of a delayed union or a non union. We describe a simple and innovative technique to remove the distal portion of broken intramedullary nails without causing any further trauma. This technique can be extended to include most hollow intramedullary nails.

Keywords : broken intramedullary nail ; hardware removal.

It is sometimes very difficult to remove the distal portion of a broken intra-medullary fixation device. Various methods have been described ranging from modified Kuntscher reaming guides (3) to screws (4) or guide wires wedged into the nail cavity (5). In our hospital we have devised a simple, safe and cheap method for extracting the broken distal portion of femoral intramedullary nails.

Technique

The operation is carried out with the patient lying supine on a fracture table under fluoroscopic control. The previous skin incision is utilised whenever possible. The proximal locking screw(s) and the proximal portion of the nail are removed using standard extraction instrumentation.

The distal locking screws are then removed and a 2 mm guide wire is fashioned to form a “fish-hook” using standard wire benders. The “fish hook” is then introduced via the greater trochanter into the medullary canal. The fish hook can then be passed either inside the nail (fig 1) or outside it in the metaphyseal region (fig 2). The fish hook is then engaged into the tip of the distal portion of the nail and pulled out in a retrograde manner. The distal portion of the broken femoral nail is removed together with the fish hook guide wire. The femoral canal can then be over-reamed if necessary and a larger diameter nail inserted as required.

ILLUSTRATIVE CASES

Between December 2003 and June 2004, 2 broken femoral intramedullary nails were removed using the “Fish-Hook” technique. Both of them had delayed union and secondary fatigue fracture of the

■ Mehool Acharya, MBBS, MRCS, Specialist Registrar in Trauma & Orthopaedics.

■ Asef Alani, MBBCh, MRCS- Trauma Fellow Registrar.

■ Sami Almedghio, MBBCh MRCS, Clinical Fellow Trauma & Orthopaedics.

Leicester Royal Infirmary, University Hospitals of Leicester NHS Trust, Leicester UK.

Correspondence : Mehool Acharya, University Hospitals of Leicester NHS Trust, Leicester Royal Infirmary, Infirmary Square, Leicester. E-mail : mez001@hotmail.com

© 2008, Acta Orthopædica Belgica.

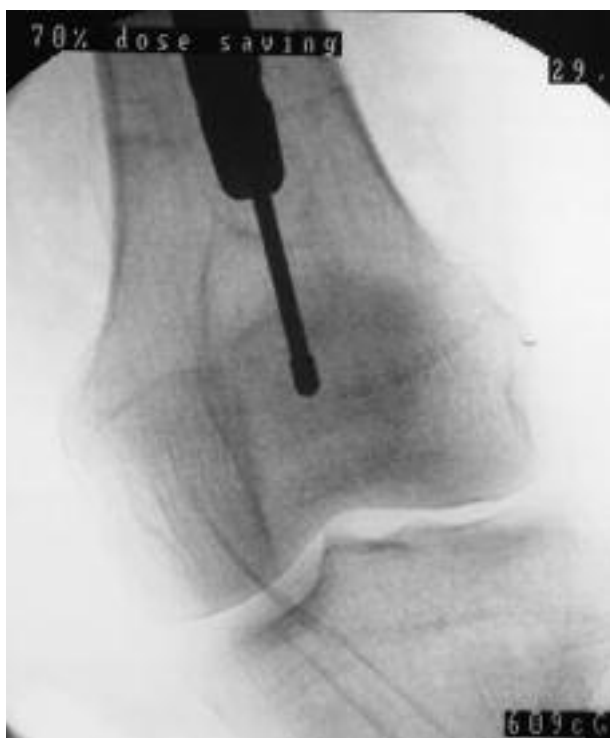

Fig. 1. — Intra-operative fluoroscopic image showing introduction of fish hook wire into the distal part of a broken intramedullary femoral nail.

nail. Both nails were Smith & Nephew's standard femoral locking intramedullary nails.

Case 1

The first case was a 62-year-old female, who first presented with pain in her left femur without any history of trauma. Upon assessing the patient and obtaining radiographs of her left femur, it was found out that she had a subtrochanteric fracture of her left femur. Full assessment was performed and malignancy was excluded; she was treated with intramedullary nailing. The patient continued to suffer from pain in her left femur and after 8 months a diagnosis of non union was made, she was listed to have exchange nailing. On pre-operative screening under radiographic control it was found that the nail was broken through the proximal screw hole. The proximal part of the nail was extracted using standard femoral nail removal instrumenta-

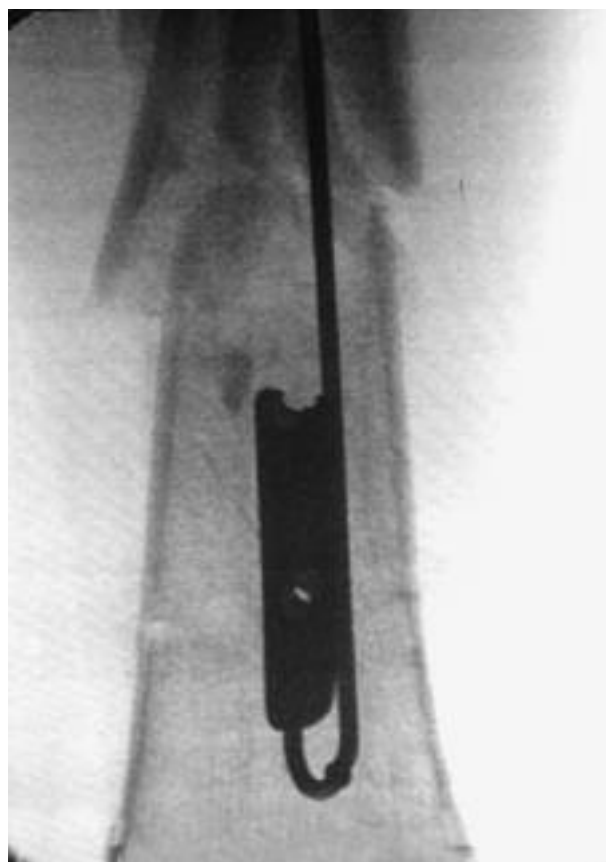


Fig. 2. — Intra-operative fluoroscopic image showing placement of fish hook wire in the medullary canal, outside the distal part of a broken IM femoral nail.

tion and the distal portion was extracted using the intra medullary/ intra prosthetic "Fish-Hook" technique. The patient underwent exchange nailing and the fracture went on to satisfactory clinical and radiological union at 6 months.

Case 2

A 48-year-old male was involved in a road traffic accident leading to an open fracture of the mid shaft of his left femur. The fracture was treated with debridement and intramedullary nailing. Two months after the injury the patient was allowed to partially bear weight on his left femur. One month later he started experiencing pain in his left femur and upon assessing him he was found to have local tenderness over the previous fracture site. Radio-

graphs confirmed that the femoral nail had broken through the proximal of the two distal locking screw holes. During exchange nailing, the proximal part of the nail was removed using standard removal instrumentation. The distal portion was extracted using an intramedullary/extra prosthetic "Fish-Hook" technique following which re-nailing was performed. The fracture went on to satisfactory union at 8 months.

DISCUSSION

The use of intramedullary nails has helped in minimising the operative trauma to the fracture site and soft tissues. The soft tissue envelope around the fracture is maintained by placing incisions proximal and distal to the fracture site. The biomechanical advantage of an intramedullary device is that it decreases the lever arm moment on the internal fixation device.

Metal implants usually fail by fatigue fracture secondary to cyclical loading which leads to crack initiation and propagation and eventually failure. In both our cases there was delayed union at the fracture site which led to cyclical loading and failure.

Extracting the distal fragment of a broken intramedullary nail can be very difficult and many techniques have been described for retrieving this fragment. These include making a bone window and pushing the nail (2), guide wire impaction (5), the use of a grasping sleeve (1) and jamming a nail

of smaller diameter into the broken segment (5). Some of these techniques involve creating more localised trauma which may have its own complications and may delay union even further and others require specialised instrumentation.

Our Fish-Hook technique is simple, safe, cheap, and does not require specialist instrumentation. In both cases the extraction was performed with ease and the average operating time including subsequent reaming and re-nailing was 60 minutes. Fracture union occurred within 6-8 months in both cases without any complications. The technique could be extended to include most hollow nails.

REFERENCES

1. **Dawson GR, Stadler RO.** Extractor for removing broken stuck intramedullary nail. *Am J Orthop Surg* 1986 ; 10 : 150-151.
2. **Franklin JL, Winquist RA, Benirsche SK, Hansen ST.** Broken intramedullary nails. *J Bone Joint Surg* 1988 ; 70-A : 1463-1471.
3. **Khan FA.** Retrieval of a broken intra-medullary femoral nail. *Injury* 1992 ; 23 : 129.
4. **Mooney J, Chabon SJ, Poehling GG.** Removal of a fractured intra-medullary nail. *Orthop Rev* 1991 ; 20 : 923-924.
5. **Steinberg EL, Luger E, Menahem A, Helfet DL.** Removal of a broken distal closed section intramedullary nail : Report of a case using a simple method. *J Orthop Trauma* 2004 ; 18 : 233-235.
6. **Yoslow W, LaMont Jg.** Alternative method for removing an impacted AO intra-medullary nail. *Clin Orthop* 1986 ; 202 : 237-238.