



The natural history of a mistreated ipsilateral Galeazzi and Monteggia lesion : Report of a case 39 years post-injury

George M. KONTAKIS, Dritan PASKU, Joseph PAGKALOS, Pavlos G. KATONIS

University Hospital of Heraklion, Crete, Greece

Galeazzi injury combined with ipsilateral Monteggia lesion is extremely rare. A 45-year-old male patient with a mistreated Galeazzi lesion combined with an ipsilateral Monteggia fracture at the age of 6 is presented. Thirty-nine years post-injury his elbow was asymptomatic and stable and his distal radioulnar and radiocarpal joints were also asymptomatic. The strength of the limb was equal to the unaffected contralateral upper limb and he was able to work manually as a waiter for the last 20 years without any problem. The only obvious defect was a 30° lack of elbow flexion and a 10° lack of forearm pronation in comparison to the normal side.

Keywords : Galeazzi ; Monteggia ; long-term result.

Both Galeazzi and Monteggia fracture dislocations are double injuries, which represent 3-6% and 1-2% respectively of forearm fractures (3). When these injuries are misdiagnosed or are not properly treated, this may dramatically affect the function of the upper extremity resulting in wrist, forearm or elbow disability. Ipsilateral combination of these injuries is extremely rare (3,16).

We present a case of ipsilateral combined Galeazzi and Monteggia lesions in a 45-year-old adult, which had been misdiagnosed and mistreated 39 years earlier.

CASE REPORT

A 45-year-old man presented to our clinic for pain in the posterior aspect of his left elbow. This

was actually an overuse lesion (tendonitis) in the triceps insertion on the proximal ulna. During examination it was realized that his right elbow had a flexion loss, and a lump was evident during inspection of the dorsal aspect of the wrist, representing the distal end of his right ulna. He reported a dorsally displaced distal radius fracture at the age of six, after a fall with his bicycle. Initially, his fracture was managed by a "bone setter" because of absence of specialized doctors in his community, with forced manipulation, correction of the wrist deformity and immobilization in a long cast for 6 weeks. One year later (according to his parents' descriptions) a physician diagnosed his complex injury but no treatment was suggested as he had a functional and asymptomatic elbow. He could recall that there was some loss of his elbow range of motion from childhood but this remained

■ George M. Kontakis, MD, Assistant Professor of Orthopaedics-Traumatology.

■ Dritan Pasku, MD, Resident in Orthopaedics.

■ Joseph Pagkalos, MD, Fellow.

■ Pavlos G. Katonis, Assistant Professor of Orthopaedics-Traumatology.

University Hospital of Heraklion, Crete, Greece.

Correspondence : George M. Kontakis, MD, 1 Pindarou street, 71305 Heraklion, Crete, Greece.

E-mail : kontak@med.uoc.gr

© 2008, Acta Orthopædica Belgica.

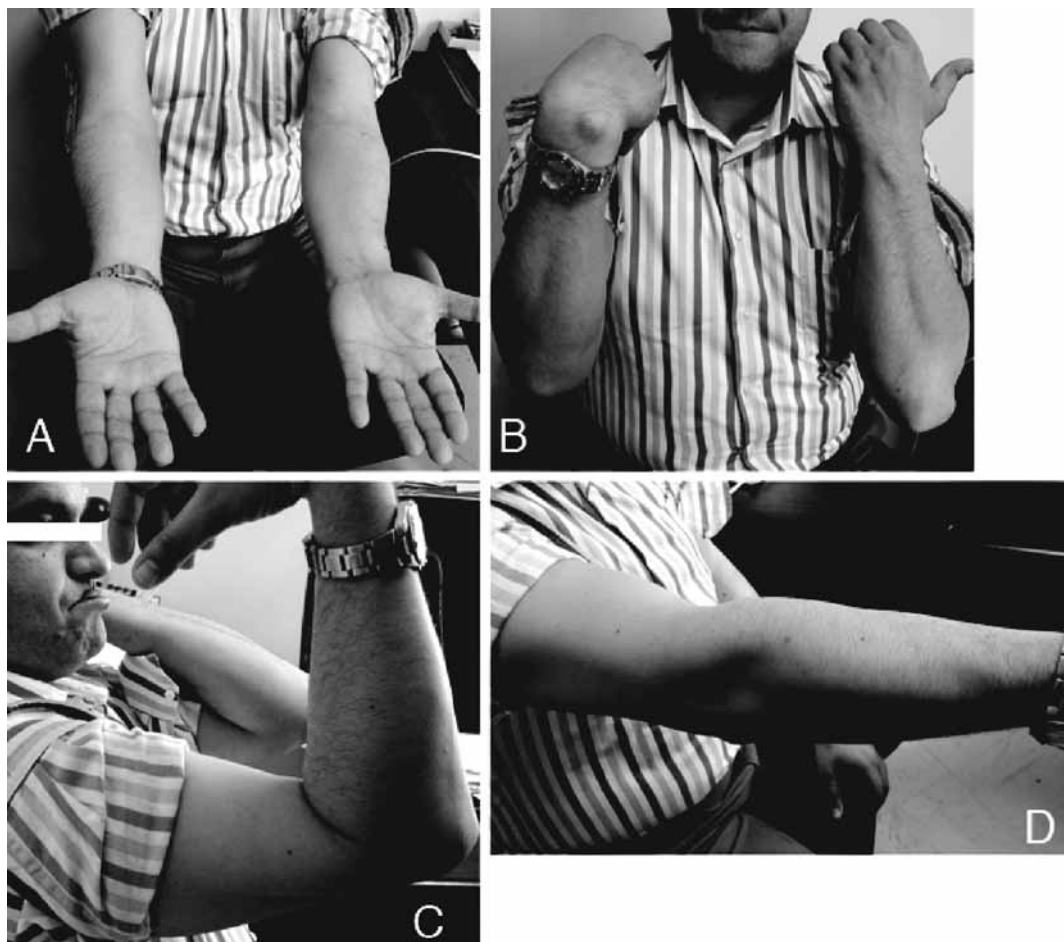

Fig. 1. — Photographs showing the right forearm and the elbow of the patient in extension and flexion

unchanged thereafter. During examination, the right elbow was pain free and stable (in extension and in flexion) and the distal radio-ulnar and radiocarpal joints were also asymptomatic. The strength of the limb was equal to the unaffected contralateral upper limb and the patient was able to work manually as a waiter (using mainly his right limb) for the last 20 years without any problems. The only obvious defect was a 30° lack of flexion and a 10° lack of pronation as compared with the normal side. The carrying angle was equal to the contralateral uninjured side (fig 1). We asked the patient to allow us to check his right elbow and forearm radiographically in order to see the condition of the joints and the bone morphology 39 years post-injury. He had not kept any post-injury radiograph. Antero-posterior

or (AP) forearm radiograph (fig 2A) showed lateral bowing of the upper 1/3 of the ulna. The radius was seen to be over-developed. The radial head was dislocated laterally to the humeral condyle. The distal radioulnar joint was also dislocated, and no signs of arthritis or disorganisation were seen in the radiocarpal joint. In the lateral radiographic view, the radial head was noted to be deformed and dislocated anterior to the humeral condyle. Slight anterior bowing of the ulna was also noted. Minor degenerative changes (small anterior and posterior osteophytes) existed in the ulno-humeral joint. Focusing on the elbow (fig 3A), the radial head was seen “articulated” with the humerus laterally to the condyle with no signs of degeneration of the “neoarthrosis”. The humero-ulnar joint space was

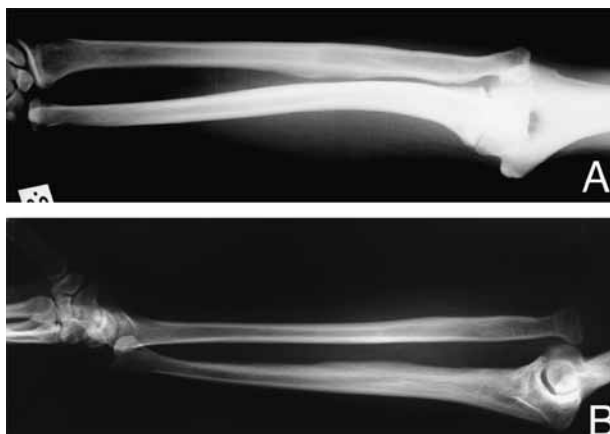


Fig. 2. — Anteroposterior (A) and lateral (B) views of the forearm showing proximal and distal radioulnar dislocations, and bowing of the ulna.

normal. The lateral elbow radiograph with the elbow flexed over 90° confirmed the anterolateral displaced position of the radial head (fig 3B). Despite the chronic dislocation of the distal radioulnar joint no arthritic changes were noted in the radiocarpal joint.

DISCUSSION

The question that arises with this case is to know what was the primary lesion. The lateral and slight anterior bowing of the ulna in this patient as they were revealed in the AP and lateral forearm radiographs presumably represent a remodeled displaced old fracture of the upper ulnar metaphysis. Having in mind that the position of the dislocated radial head indicates the angulation of the ulna fracture (11), we may speculate that this angulation was antero-lateral. Combined with the clear information from the patient's history that he was treated for a distal radius fracture, this leads to the conclusion that this case probably represents the sequelae of a mistreated Galeazzi fracture associated with a Monteggia type III injury according to the Bado classification (lateral or anterolateral dislocation of the radial head combined with a fracture of the ulnar metaphysis). If there was not such a clear description of the initial injury, this case should be

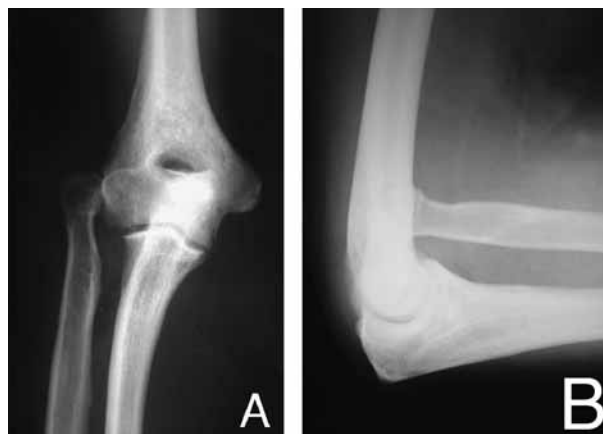

Fig. 3. — Radiographic views focusing on the elbow (A, B).

considered only as a sequel of a Monteggia lesion, with the derangement of the distal radioulnar joint appearing as a long-term complication of the chronic posttraumatic radial head dislocation (17).

There is scarce information in the literature about the natural history of untreated or mistreated Monteggia fracture. Lloyd-Roberts and Binknill (15) presented the case of a 59-year-old patient who had an untreated Monteggia I lesion 50 years earlier. This patient had a painful shoulder over the last 5 years, but he had only $80\text{--}110^\circ$ range of flexion and a 30° unstable valgus deformity of the elbow. There was no information regarding either the duration of the fixed flexion contracture or the valgus deformity, but this case was enough for the authors to conclude that the outcome was unsatisfactory and a reliable treatment method of early correction should be needed in similar cases.

An isolated radial head dislocation may represent either a congenital anomaly or a residual deformity from a missed Monteggia lesion. Congenital dislocation is usually bilateral (1). Lincoln and Mubarak described the ulnar bow sign as a very helpful sign to diagnose subtle previous ulnar injuries (14). Other authors support the idea that an isolated traumatic radial head dislocation may actually occur without an associated bone injury. Kadic and Bloem reported a case of isolated radial head dislocation with

good results after 32 years of follow-up (10). Recently, Levy and Owens published a case of asymptomatic chronic radial head dislocation in a 58-year-old man, diagnosed 27 years after an elbow injury (13). Chronic radial head dislocations have been reported to cause elbow instability and pain, loss of motion, progressive valgus deformity and arthrosis of the elbow (6,8,12,14,18). Untreated or mistreated Galeazzi fractures may lead to limitation of supination and pronation, chronic wrist pain and loss of strength (11).

It is well known that Galeazzi as well as Monteggia lesions warrant treatment. In the past, some authors advised no treatment in chronic radial head dislocations, believing that surgery may limit function more than the persistent radial head dislocation (5,9). In recent literature, the most common treatment for "chronic" dislocation has been open reduction of the radial head with reconstruction of the annular ligament using the triceps tendon, osteotomy of the deformed proximal ulna or their combination with or without concurrent temporary transcapitellar-radial transarticular pin fixation (2,4,7).

A combination of Galeazzi and Monteggia lesions in the same forearm is very unusual with only 10 cases reported in the literature (16). All the cases were fresh injuries and were managed properly either by surgical or by closed means. No untreated or mistreated case with a long follow-up, as in our case, has been reported previously. The almost normal range of supination-pronation could be explained by the fact that the complete disruption of both proximal and distal radio-ulnar joints permitted unrestricted and asymptomatic rotation between the radius and the ulna. The stability of the elbow in extension and in flexion could be explained by the lateral position of the radial head in relation to the humerus, which acted as a restraint to valgus stress. The radial head dislocation can also explain the limitation of elbow flexion. Although the elbow and wrist of this patient do not have the benefits of normal physiologic joints, and although he may still develop symptoms later on, it is impressive to see how nature can accommodate some anatomical defects for such a long time.

REFERENCES

1. **Agnew DK, Davis RJ.** Congenital unilateral dislocation of the radial head. *J Pediatr Orthop* 1993 ; 13 : 526-528.
2. **Best TN.** Management of old unreduced Monteggia fracture dislocation of the elbow in children. *J Pediatr Orthop* 1994 ; 14 : 193-199.
3. **Clare DJ, Corley FG, Wirth MA.** Ipsilateral combination Monteggia and Galeazzi injuries in an adult patient : A case report. *J Orthop Trauma* 2002 ; 16 : 130-134.
4. **Devnani AS.** Missed Monteggia fracture dislocation in children. *Injury* 1997 ; 28 : 131-133.
5. **Freedman L, Luk K, Leong LCY.** The radial head reduction after a missed Monteggia fracture : brief report. *J Bone Joint Surg* 1988 ; 70-B : 846-847.
6. **Givon U, Pritsch M, Levy O, Yosepovich A, Amit Y, Horoszowski H.** Monteggia and equivalent lesions. *Clin Orthop* 1997 ; 337 : 208-215.
7. **Horii E, Nakamura R, Koh S, Inagaki H, Yajima H, Nakao E.** Surgical treatment for chronic radial head dislocation. *J Bone Joint Surg* 2002 ; 84-A : 1183-1188.
8. **Hume AC.** Anterior dislocation of the head of the radius associated with undisplaced fracture of the olecranon in children. *J Bone Joint Surg* 1957 ; 39B : 508-512.
9. **Hurst LC, Dubrow EN.** Surgical treatment of the symptomatic chronic radial head dislocation : a neglected Monteggia fracture. *J Pediatr Orthop* 1983 ; 3 : 227-230.
10. **Kadic AC, Bloem RM.** Traumatic isolated anterior dislocation of the radial head. *Acta Orthop Scand* 1991 ; 62 : 288-289.
11. **King RE.** Fractures of the radius and ulna. In : Rockwood CA, Wilkins KE, King R (eds). *Fractures in Children*, 3rd edition, Lippincott, Philadelphia 1991 ; pp 415-508.
12. **Letts M, Loch R, Wiens J.** Monteggia fracture-dislocations in children. *J Bone Joint Surg* 1985 ; 67-B : 724-727
13. **Levy JC, Owens P.** Asymptomatic chronic radial head dislocation after traumatic dislocation. *Orthopedics* 2007 ; 30 : 235-236.
14. **Lincoln TL, Mubarak SJ.** "Isolated" traumatic radial-head dislocation. *J Pediatr Orthop* 1994 ; 14 : 454-457.
15. **Lloyd-Roberts GC, Bucknill TM.** Anterior dislocation of the radial head in children : aetiology, natural history and management. *J Bone Joint Surg* 1977 ; 59-B : 402-407.
16. **Maeda H, Yoshida K, Doi R, Omori O.** Combined Monteggia and Galeazzi fractures in a child : a case report and review of the literature. *J Orthop Trauma* 2003 ; 17 : 128-131.
17. **Seel MJ, Peterson HA.** Management of chronic posttraumatic radial head dislocation in children. *J Pediatr Orthop* 1999 ; 19 : 306-312.
18. **Theodorou SD, Ierodiaconou MD, Rousis N.** Fracture of the upper end of the ulna associated with dislocation of the head of the radius in the children. *Clin Orthop* 1988 ; 228 : 240-249.