



## Correction of adolescent hallux valgus by proximal crescentic osteotomy of the first metatarsal

Dimitrios V. PETRATOS, John N. ANASTASOPOULOS, Christos V. PLAKOGIANNIS, George S. MATSINOS

*From Aghia Sophia Children's Hospital, Athens, Greece*

Thirty nine surgical hallux valgus corrections in 32 adolescents (7 bilateral) performed between 1994 and 2001 were retrospectively studied. The mean age at the time of surgery was 14.2 years. The operation consisted of a proximal dome osteotomy of the first metatarsal, excision of the medial protuberance, lateral capsular and adductor release, and distal medial soft tissue plication. The patients were followed for an average of 42 months (range 32 to 62). Post-operative evaluation was based on the duPont bunion rating score. The result was excellent in 11 feet, good in 22 cases, fair in 5 and poor in 1 case. Using subjective criteria of the duPont score, such as cosmesis and discomfort, a satisfactory result was achieved in 35 feet (90%). Our opinion is that correction of the angle between the 1<sup>st</sup> and 2<sup>nd</sup> metatarsal as well as preservation of the length of the first metatarsal are of crucial importance in the surgical treatment of adolescent hallux valgus.

**Keywords:** adolescents ; hallux valgus ; dome osteotomy ; proximal 1<sup>st</sup> metatarsal.

### INTRODUCTION

Adolescent hallux valgus is a relatively common deformity (22-36% of children and adolescents) with a predominance in female individuals. The origin of this deformity has been attributed to hyperlaxity of the first metatarsophalangeal (MTP) joint and to an oblique first metatarsal epiphysis. The primordial aetiological factor of the deformity

is however metatarsus primus varus, a congenital deformity often first detected in infancy (10).

Most of the children with hallux valgus are asymptomatic and may be treated conservatively with shoe wear modifications and orthoses (5,6). Operative correction has been suggested for patients with chronic severe pain, difficulty with shoe wear and cosmetic dissatisfaction (3,23). Tachdjian categorized the innumerable surgical options in five basic categories : first metatarsal osteotomy, soft tissue procedures at the first MTP joint, adductor hallucis transfer, excision of the metatarsal prominence and proximal phalangeal resections (10).

The purpose of this retrospective study was to evaluate the management of adolescent hallux valgus with a dome osteotomy of the proximal

---

■ Dimitrios V. Petratos, MD, Consultant Orthopaedic Surgeon.

■ John N. Anastasopoulos, MD, PhD, Consultant Orthopaedic Surgeon.

■ Christos V. Plakogiannis, MD, Orthopaedic resident.

■ George S. Matsinos, MD, Consultant Orthopaedic Surgeon.

*2<sup>nd</sup> Orthopaedic Department, Aghia Sophia Children's Hospital, Athens, Greece.*

Correspondence : D.V. Petratos, 2<sup>nd</sup> Orthopaedic Department, Aghia Sophia Children's hospital Thivon kai Mikras Asias, Athens 11527 Greece. E-mail : dimpetr70@hotmail.com

© 2008, Acta Orthopædica Belgica.

---

metatarsal combined with a distal soft tissue procedure.

**PATIENTS AND METHODS**

From January 1994 to March of 2001 32 adolescents (27 girls, 5 boys) were treated for hallux valgus using a proximal osteotomy of the first metatarsal. The deformity was bilateral in 7 children (5 females and 2 males). At the time of surgery the mean age was 14.2 years (range : 11.8 to 15.3). Patients with underlying neuromuscular or connective tissue disorders were excluded from the study. The chief complaints leading to operative intervention are shown in table I.

**Surgical procedure**

All the operations were performed under general anaesthesia with the patient in supine position by two certified orthopaedic surgeons with the assistance of a resident surgeon in orthopaedics. A pneumatic tourniquet was used. Bilateral deformity surgery was done in two sessions (the average interval between procedures was 11 months).

The skin incision, at the dorsomedial aspect of the first metatarsal and first MTP joint, extended from the base of the first phalanx to the base of the metatarsal. The medial eminence with its overlying capsule was identified. A V-shaped capsular incision was performed with its broad base located at the level of the MTP joint. The dorsal and plantar limbs of the incision were located on the dorsomedial and plantarmedial aspects of the bunion. The two limbs ended up at a point in the midmedial line of the metatarsal shaft, 1 cm proximal to the eminence. The capsular flap, which was raised by sharp dissection, was based on the base of the proximal phalanx. Excision of the medial protuberance was then performed using a power saw. The lateral part of the capsule of the first MTP joint was subsequently incised and the tendon of the adductor hallucis was routinely released from its

insertion into the fibular sesamoid and the base of the first phalanx.

A crescentic osteotomy at the base of the first metatarsal, 1.5 cm distal to the metatarsocuneiform joint, was then performed, by connecting multiple drill holes with a small osteotome. Following Mann's technique, the concave surface was on the proximal fragment and the dome on the distal fragment (13). We believe that, with this type of osteotomy, slight proximal correction ensures a great correction of the deformity. The metatarsus primus varus was corrected with manual displacement of the fragments ; the distal fragment was moved laterally and the proximal fragment medially (fig 1). The osteotomy was stabilised with a 2 mm Steinmann pin transfixing the osteotomy site and the 1<sup>st</sup> tarsometatarsal joint (medial cuneiform – 1<sup>st</sup> metatarsal). The insertion point of the pin was on the midmedial aspect of the distal metaphysis, 1 cm proximal to the articular surface of the metatarsal head. The pin was manually passed through the medullary canal of the 1<sup>st</sup> metatarsal, ending in the medial cuneiform.

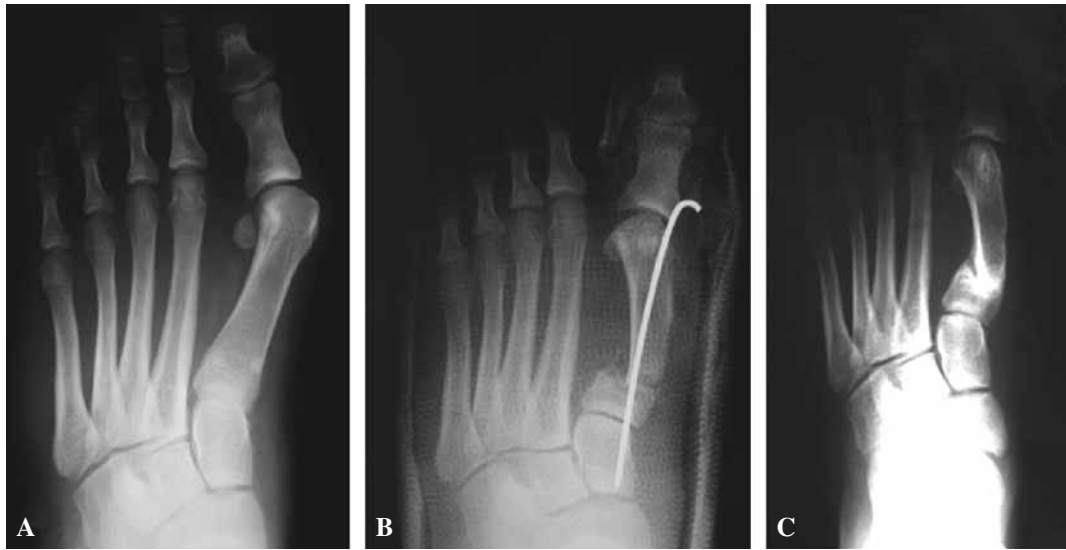Finally the distally based V-shaped flap that was created from the medial part of the capsule of the MTP joint was moved proximally. With the toe in slight varus angulation and in neutral position in the sagittal plane, the flap was sutured onto the bone, using an absorbable suture that was passed through an anteroposterior hole created in the shaft of the metatarsal. At the same time the toe was held in slight supination to correct the pre-operative pronation. The skin was closed and a below knee cast was applied with the great toe kept in the corrected position. The Steinmann pin was removed without anaesthesia at the outpatient clinic at the time of cast removal, six weeks after the operation.

The average follow-up of our cases was 42 months (range 32 to 62 months).

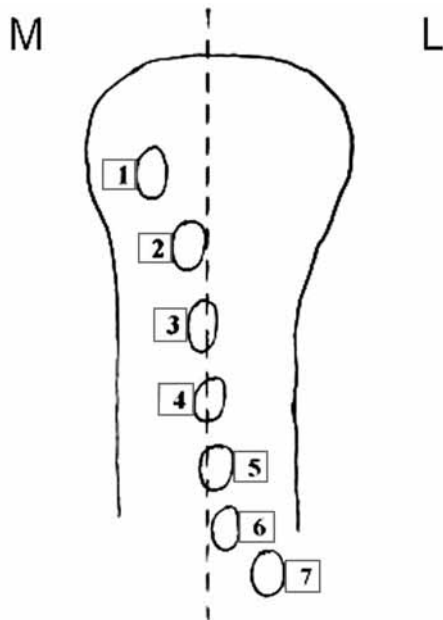
Anteroposterior and lateral radiographs were taken pre-operatively, post-operatively and at final follow-up with the patient standing. The hallux valgus angle (HVA), the angle between the first and second metatarsals (IMA) and the first – second metatarsal length ratio (MLR) were measured. The status of the first metatarsal physis was also evaluated. In addition tibial sesamoid position, according to the description by Hardy *et al* (7), was recorded to evaluate if the intraoperative rotation of the great toe into supination was sufficient to correct the preoperative pronation (fig 2). Physical examination assessed the range of motion of the first MTP joint pre- and post-operatively. The overall results were analysed using the duPont bunion rating score (5) (DPS), a 25-point rating scale that incorporates 15 points for

Table I. – Main complaints of patients

COMPLAINT	Primary complaint n (%)	Secondary complaint n (%)
Pain	27 (69)	3 (8)
Progressive deformity	8 (21)	9 (23)
Shoe wear problems	4 (10)	7 (18)
TOTAL	39 (100)	19 (48)



**Fig. 1.** — A 14.9 year-old girl had pain for 1.5 years at the site of the bunion before undergoing a metatarsal osteotomy. **A** : Preoperative A/P standing radiograph of the left foot. **B** : Manipulation of the distal fragment laterally and translation of the proximal fragment medially followed by transfixion of the concave osteotomy. The Steinman pin penetrates the 1st tarsometatarsal joint. **C** : A/P radiograph of the left foot with the patient standing, 35 months after the operation.



**Fig. 2.** — The position of the tibial sesamoid as described by Hardy *et al.* Supination of the great toe is performed in order to correct the preoperative pronation and is checked by the degree of reduction of the tibial sesamoid into a more anatomical position under the medial part of the 1<sup>st</sup> metatarsal head (M : medial, L : lateral).

objective and 10 points for subjective criteria (table II). A DPS of 16 or less was defined as a poor result, 17 to 19 points a fair result, 20 to 22 points a good result and 23 to 25 an excellent result.

The subjective result was defined as satisfactory when the patient was pleased with the cosmetic correction and expressed good relief of symptoms at final follow-up.

## RESULTS

All osteotomies united at an average of 6 weeks (range 4 to 9). Nonunion at the osteotomy site or avascular necrosis of the metatarsal head was not seen.

Preoperatively the average IM angle was 15.3° and the average MTP angle was 36°. Postoperatively the average IM angle was 8° and the average MTP angle was 22°.

Following the duPont scoring system the result was good or excellent in 33 cases (84.6%) : excellent in 11, good in 22 and fair in 5. Patients were satisfied with the result achieved in 35 feet (89.7%).

One of the cases classified “good” was unhappy with the final cosmetic result (post-op angles, IM :

Table II. – duPont bunion rating score

<i>Objective</i>					
MTP angle					
Degrees	0 to 15	16 to 25	26 to 35	36 to 45	> 45 or varus
Points	5	4	3	2	1
IM angle					
Degrees	< 9	10 to 15	16 to 20	21 to 25	> 25
Points	5	4	3	2	1
Motion (degrees)					
Dorsiflexion	> 25	15 < DF < 25 or	15 < DF < 25 and	< 15	No motion
Plantarflexion	> 15	10 < PF < 15	10 < PF < 15	< 10	No motion
Points	5	4	3	2	1
<i>Subjective</i>					
Pain	None	Occasional	Constant non limiting	Constant limiting	RSD*
Points	5	4	3	2	1
Cosmesis	Excellent	Good	Fair	Poor	Worse than preoperative
Points	5	4	3	2	1

\* reflex sympathetic dystrophy.

Rating : excellent = 23-25 points, good = 20-22 points, fair = 17-19, poor = < 16 points.

12° and MTP : 19°) and another complained of moderate pain during athletic activities or in narrow footwear. The pain was located at the medial sesamoid although its post-operative position was Hardy 2.

Among the 5 cases with a “fair” result only one patient was really dissatisfied, reporting constant metatarsalgia that was worse when she was standing for a long period. This 12-year-old girl presented the greatest decrease of MLR. Although the post-op radiographs and MTP joint motion were not ideal in these feet classified as fair, the subjective final result was satisfying in all other patients.

One result was classified as poor because of recurrence of the valgus deformity. Revision surgery was performed 9 months later. The final outcome was a very stiff MTP joint (duPont fair), but the patient was very happy because she could finally perform everyday activities without pain.

Preoperatively the tibial sesamoid was located laterally or centrally (beyond position 4 of Hardy) in 28 cases (71.7%). Post-operatively it was located centrally or medially (better than position 3 of Hardy) in 32 cases (82%). The average sesamoid position improved from 4.9 to 2.3 (7).

The length of the first and second metatarsals was measured preoperatively and postoperatively to

evaluate shortening resulting from the osteotomy. Preoperatively the MLR was 0.848 (0.811-0.892) and postoperatively (after confirmed radiological union of the osteotomy) 0.832 (0.781-0.871). Against our expectations the average decrease of the MLR was 0.016 (-1.8%).

The average values for preoperative and post-operative IM angle, MTP angle, sesamoid position, MLR as well as for the MTP joint ROM are presented in table III.

Complications included three cases of temporary scar hypersensitivity persisting for a few months, one case of superficial skin infection, controlled by antibiotics but resulting in an unsightly painless scar and one case of recurrence (as mentioned above).

## DISCUSSION

Hallux valgus in adolescents is not an uncommon deformity. Diverging concepts of aetiology and pathophysiology have led to different treatment options. More than 130 operations for hallux valgus in adolescents have been reported (9). They fall into 4 main categories : proximal metatarsal osteotomies, distal metatarsal osteotomies, soft tissue procedures and combinations of the above procedures.

Table III. – Measurements (average value)

Measurement	Preoperative	Postoperative
IM angle	15.3°	8°
HV angle	36°	22°
Sesamoid position (according to Hardy)	4.9	2.3
Metatarsal length ratio	0.848	0.832
MTP joint ROM	flexion 36° extension 62°	flexion 25° extension 48°

The procedure that was performed in this study was a combination of proximal osteotomy with a lateral soft tissue release and medial capsular tensioning.

Distal osteotomies of the first metatarsal such as the Mitchell and chevron osteotomy, have become very popular for specific reasons: 1) metatarsus primus varus is corrected reducing splay-foot deformity, 2) the operative site is remote from the physis of the first metatarsal, and 3) the soft tissue correction of the first MTP joint is performed through the same incision. The efficacy in adolescents of Mitchell's osteotomy (14), a modification of older operations (Peabody 1931 – Hawkins 1945) (8,15), has received both praise and condemnation. Ball and Sullivan reported disappointing results with a recurrence rate of 61% and recommended abandoning the procedure for adolescents (2). On the contrary Geissel and Stanton (5) reported remarkable 95% success rate and Canale *et al* reported 68% satisfying results (3). The poor results in Ball's series and the complications reported by Geissel and Canale were related to the step-off osteotomy and the inadequate fixation provided by the suture loop. Metatarsal shortening and dorsal tilt of the distal part caused weight transfer to the lateral metatarsals and transient metatarsalgia. Modifications of Mitchell's osteotomy (smooth pin fixation – use of trapezoidal sector for the step-off osteotomy) have been used in recent years (4,12,21) with good results, but shortening of the first metatarsal, an important biomechanical disadvantage, cannot be avoided. Zimmer and Johnson in 1989 reported good results with the chevron osteotomy (25). We think that a further disadvantage of the distal osteotomies is that these procedures are performed close to the nutrient artery for the metatarsal head, which enters the

diaphysis only 2.5 cm proximal to the capsule of the 1<sup>st</sup> MTP joint. On the contrary, osteotomies of the metatarsal base are performed in an area with richer blood supply and consequently less chances for bone necrosis.

Osteotomies of the proximal part of the 1<sup>st</sup> metatarsal seem to be more demanding, are performed near the physis of the metatarsal and they have not been used so frequently as the distal osteotomies. Different types of proximal osteotomies have been reported. Among the most popular are the closing – wedge osteotomies (17) usually resulting in metatarsal shortening and transient metatarsalgia, the open – wedge osteotomies (11) which because of the metatarsal lengthening can result in early recurrence, and the dome osteotomies (22) like ours, that were proposed to avoid the previous problems.

Scranton and Zuckerman (18) reported a recurrence rate of 30% using different types of proximal osteotomies (closing-wedge, open-wedge, oblique, dome). In their series there was no evidence of proximal physeal damage. However it is their belief that children with open physes should not have elective reconstructive surgery and this is based on the opinion that bunion surgery is a particularly demanding and precise procedure. In our series none of the patients developed deformity secondary to physeal injury and our opinion is that open physis is not a contraindication to perform a basal osteotomy in adolescents.

Senaris-Rodriguez *et al* (19) using closing – wedge osteotomy of the proximal metatarsal in ten cases, reported two poor results due to post-op hallux varus deformity and nine cases of post-op metatarsal shortening, however without transient metatarsalgia. The relation between metatarsal shortening and transient metatarsalgia is still a matter of debate. Stabilisation of the osteotomy with two K-wires was satisfactory and damage to the physis was not recorded. In our series overcorrection to hallux varus was not seen. Soon after the end of the surgery and before cast application A/P and lateral radiographs of the foot were performed in the operating room to check for any malalignment at the osteotomy site. Dorsal angulation of the distal part of the metatarsal was noted in no instance.

The slight decrease in length of the first metatarsal might be caused by minimal bone loss at the osteotomy site or improper reduction of the osteotomised 1<sup>st</sup> metatarsal at the moment of pin insertion. We cannot be sure if very small changes of the MLR can lead to transient metatarsalgia although the patient who had the greatest decrease of the MLR was the only one presenting with this symptom. Peterson *et al* (16), performing a double osteotomy procedure and causing a 3.4% decrease in the MLR, did not note a single patient with post-operative metatarsalgia.

We did not encounter bone healing problems, probably because the contact area between the two parts of the osteotomised bone is wide, the Steinman pin ensures stable fixation and the bone at the metatarsal base has a rich blood supply.

Various methods have been used to stabilise the osteotomy of the first metatarsal including a simple suture (3,4,12), one or two K-wires (19,21), a lag screw (24), Steinman pin (16) or plate and screws (1). In our series a Steinmann pin offered stable fixation and early bone healing, without jeopardising the MTP joint. Aronson *et al* (1) using a modified Peterson procedure (16) found the large Steinman pin used for fixation was painful to remove in outpatient clinic and risked intraarticular damage of the MTP joint, and consequently decreased joint motion.

As a conclusion, we think that the adolescent hallux valgus deformity can be treated operatively after conservative methods have failed. We did not confirm the fear for the high incidence of recurrence that has been reported (2,5,20). Although in the literature the proximal osteotomies are generally reserved for the more severe cases, we have demonstrated that even in mild and moderate cases a satisfactory result is obtained with a proximal osteotomy combined with a lateral release of the capsular structures and distal medial reefing.

The shortcomings of this study are that it is not prospective and that a relatively small number of feet is presented.

The proximal crescentic osteotomy of the first metatarsal is a reliable and effective operation but needs some surgical experience. The performance of a smooth dome osteotomy instead of a straight

one, the manual correction of the deformity at the level of the osteotomy and the concomitant accurate pin insertion were found to be the major technical problems. Moving the distal dome laterally onto the proximal concave bone surface, a marked deformity can be corrected without significant change in the length of the first metatarsal (fig 1). When combined with a distal soft tissue procedure the risk of recurrence is small. Steinman pin fixation of the osteotomy is very stable and leads to early bone healing without bone grafting. Removal of the pin can be performed in the outpatient clinic and causes only slight discomfort to the patient.

## REFERENCES

1. **Aronson J, Nguyen L, Aronson EL.** Early results of the modified Peterson bunion procedure for adolescent hallux valgus. *J Pediatr Orthop* 2001 ; 21-A : 65-69.
2. **Ball J, Sullivan J.** Treatment of juvenile bunion by the Mitchell osteotomy. *Orthopedics* 1985 ; 18 : 1249-1252.
3. **Canale PB, Aronson DD, Lamont RL, Manoli A.** The Mitchell procedure for the treatment of adolescent hallux valgus. *J Bone Joint Surg* 1993 ; 75-A : 1610-1618.
4. **Das De S.** Distal metatarsal osteotomy for adolescent hallux valgus. *J Pediatr Orthop* 1984 ; 4-A : 32-38.
5. **Geissele AE, Stanton RP.** Surgical treatment of adolescent hallux valgus. *J Pediatr Orthop* 1990 ; 10-A : 642-648.
6. **Groiso JA.** Juvenile hallux valgus : a conservative approach to treatment. *J Bone Joint Surg* 1992 ; 74-A : 1367-1374.
7. **Hardy RA, Clapham JCR.** Observations on hallux valgus. Based on a controlled series. *J Bone Joint Surg* 1951 ; 33-B : 376-391.
8. **Hawkins FB, Mitchell CL, Hendrick DW.** Correction of hallux valgus by metatarsal osteotomy. *J Bone Joint Surg* 1945 ; 27-A : 387-394.
9. **Helal B.** Surgery for adolescent hallux valgus. *Clin Orthop* 1981 ; 157 : 50-63.
10. **Herring A.** *Tachdjian's Pediatric Orthopedics*. 3d ed, WB Saunders, Philadelphia, 2002, pp 1012-1037.
11. **Limbird TS, Da Silva RM, Green NE.** Osteotomy of the first metatarsal for metatarsus primus varus. *Foot Ankle* 1989 ; 9 : 158-162.
12. **Luba R, Rosman M.** Bunions in children : Treatment with a modified Mitchell osteotomy. *J Pediatr Orthop* 1984 ; 4-A : 44-47.
13. **Mann RA, Rudicel S, Graves SC.** Repair of hallux valgus with a distal soft-tissue procedure and proximal metatarsal osteotomy. *J Bone Joint Surg* 1992 ; 74-A : 124-129.
14. **Mitchell CL, Flemming JL, Allen R, Glenney C, Sanford GA.** Osteotomy – Bunionectomy for hallux valgus. *J Bone Joint Surg* 1958 ; 40-A : 41-60.

15. **Peabody CW.** The surgical cure of hallux valgus. *J Bone Joint Surg* 1931 ; 31-A : 273-282.
16. **Peterson H, Newman S.** Adolescent bunion deformity treated with double osteotomy and longitudinal pin fixation of the first ray. *J Pediatr Orthop* 1993 ; 13 : 80-84.
17. **Resch S, Stentrom A, Egund N.** Proximal closing wedge osteotomy and adductor tenotomy for treatment of hallux valgus. *Foot Ankle* 1989 ; 9 : 272-280.
18. **Scranton PE, Zuckerman JD.** Bunion surgery in adolescents : results of surgical treatment. *J Pediatr Orthop* 1984 ; 4-A : 39-43.
19. **Senaris-Rodriguez J, Martinez-Serano A, Rodriguez-Durantez J A., Soletto-Martinez J, Gonjalez-Lopez JL.** Surgical treatment for bunions in adolescents. *J Pediatr Orthop* 1998 ; 7-B : 210-216.
20. **Simmonds FA, Menelaus MB.** Hallux valgus in adolescents. *J Bone Joint Surg* 1960 ; 42-B : 761-768.
21. **Talab Y.** Hallux valgus in children. *Acta Orthop Scand* 2002 ; 73(2) : 195-198.
22. **Thodarson DB, Leventen EO.** Hallux valgus correction with proximal metatarsal osteotomy : two years follow-up. *Foot Ankle* 1992 ; 13 : 321-326.
23. **Thompson GH.** Bunions and deformities of the toes in children and adolescents. *J Bone Joint Surg* 1995 ; 77-A : 1924-1936.
24. **Wanivenhaus AH, Feldner-Butzin H.** Basal osteotomy of the first metatarsal for the correction of the metatarsus primus varus associated with hallux valgus. *Foot Ankle* 1988 ; 8 : 337-343.
25. **Zimmer TJ, Johnson KA, Klassen RA.** Treatment of hallux valgus in adolescents by the Chevron osteotomy. *Foot Ankle* 1989 ; 9 : 190-193.