



## An unusual presentation of a giant tumour-like lesion of the thigh

Michail KOKKINAKIS, Aysha RAJEEV, Mike NEWBY, David GRAHAM

*From Queen Elizabeth Hospital, Gateshead, United Kingdom*

**Soft tissue swellings of the thigh, which become painful and are gradually increasing in size, should always raise the suspicion of a soft tissue tumour. We report a case of a clinically silent chronic granuloma formation, which presented 45 years later as a giant tumour-like lesion. A metallic foreign body implanted following an injury was found as the source of the tissue reaction. This is the longest period of delay to presentation described in the English literature for the clinical manifestation of a granulomatous reaction.**

**Keywords :** foreign body reaction ; granuloma ; tumour-like lesion.

### INTRODUCTION

Large, unilateral and painful soft tissue swellings of the thigh are consistent with a variety of conditions including infection, haematoma, lipoma, ganglion, schwannoma, neurofibroma and malignant tumours such as a sarcoma.

A foreign body reaction leads to local migration of activated macrophages, which ingest the foreign material but cannot digest it. Granulation tissue and a fibrotic capsule surround the cluster of macrophages and form the granuloma (3). It is very unusual for a granuloma to present many years after the initial foreign body implantation.

### CASE REPORT

A 59-year-old female presented with a 6-month history of a painful swelling of the left anterolater-

al thigh, which gradually increased in size. She had debridement and wound closure of a laceration in the same region 45 years earlier following a mechanical fall. She has been completely asymptomatic since then. On examination the swelling was approximately 20 × 10 × 10 cm in size, hemispherical, soft, fluctuant, with smooth surface and confined edges. The lesion did not seem to be attached to the skin or underlying structures and it was located underneath the old, hypertrophic scar. There was no associated lymphadenopathy. The patient was systemically well. The inflammatory markers including CRP, ESR and white cell count were normal. A radiograph of the left thigh demonstrated a large soft tissue swelling and a 3 × 2 cm area anterolaterally, which resembled a calcification.

The MRI scan illustrated numerous densities within the proximal and lateral soft tissues of the thigh. There was a massive degree of artefacting

---

■ Michail C. Kokkinakis, PhD, MRCS, Clinical Fellow in Trauma and Orthopaedics.

■ Mike Newby, FRCR, Consultant Radiologist.

■ Aysha S. Rajeev, FRCS, Staff Grade in Trauma and Orthopaedics.

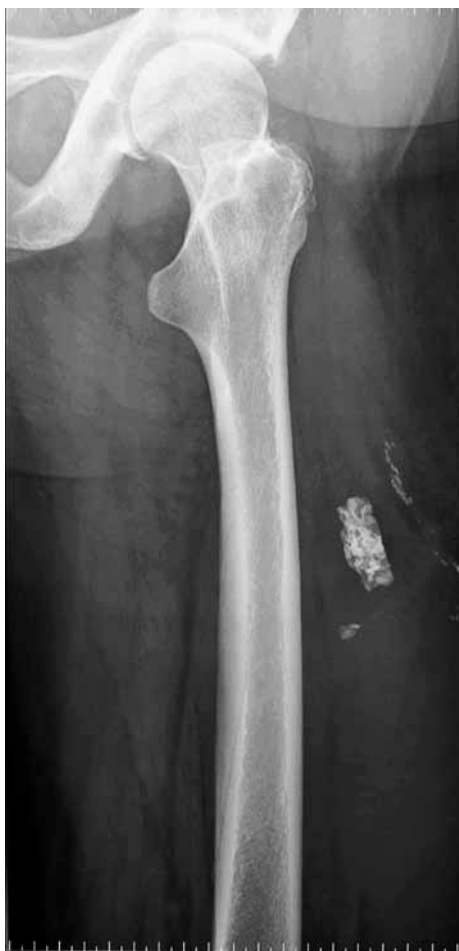■ David Graham, FRCS (Tr & Ortho), Consultant Orthopaedic Surgeon.

*Queen Elizabeth Hospital, Gateshead, United Kingdom.*

Correspondence : M. Kokkinakis, Queen Elizabeth Hospital, Queen Elizabeth Avenue, Sherrif Hill, Gateshead, NE9 6SX, Tyne and Wear, United Kingdom.

© 2008, Acta Orthopædica Belgica.

---

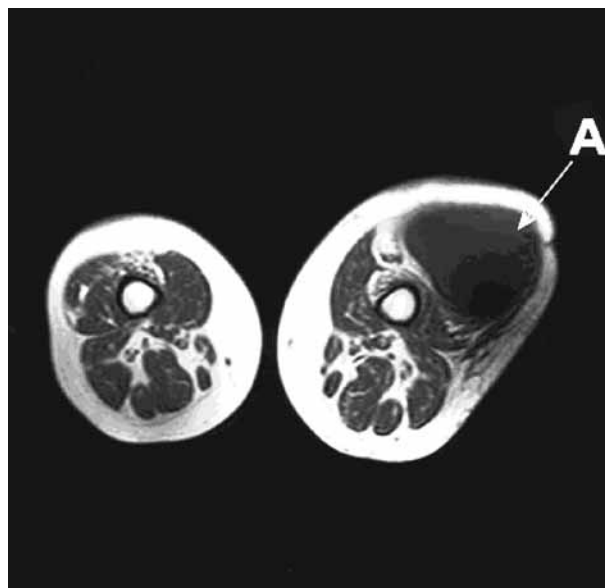


*Fig. 1.* — The lateral view of the left proximal femur illustrates the metallic object mimicking calcification of a soft tissue tumour.

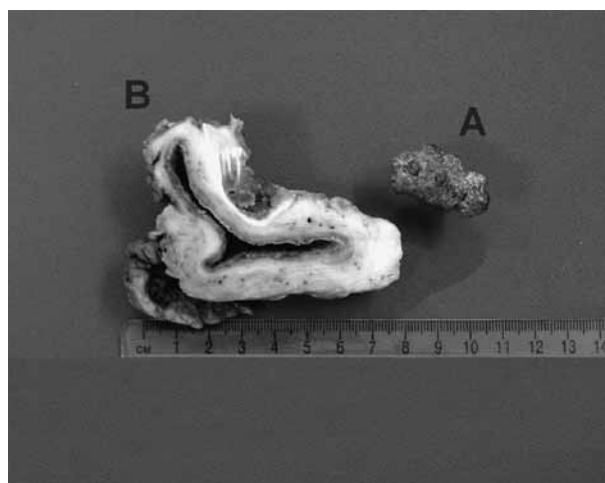from these areas. The T1 and STIR high signal intensity suggested that this was a cystic or fluid lesion as apposed to the soft tissue of the thigh.

Aspiration of the lesion revealed thick purulent fluid and subsequently excision of the cyst was undertaken. A ferro-metallic foreign body, 3 × 2 cm in size, was found lying deep on the superolateral aspect of the fluid filled cavity.

The histopathology report confirmed the diagnosis of a cyst, which was lined by chronically inflamed capillary granulation tissue. Cholesterol crystals, multinuclear giant cells and pigmented material consistent with metal debris, were present within the wall of the cyst. The features were consistent with those of a chronic granulomatous reac-



*Fig. 2.* — The axial T<sub>1</sub> MRI image demonstrates the soft tissue lesion in the anterolateral part of the left thigh.

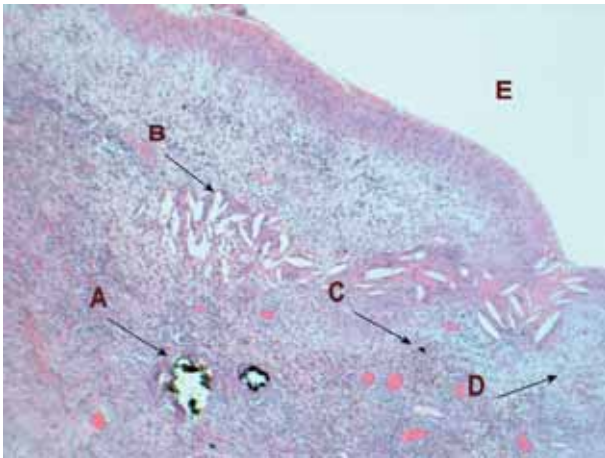


*Fig. 3.* — **A.** The ferro-metallic foreign body. **B.** The macroscopic appearance of the inflammatory cavity.

tion to metallic material. There was no evidence of malignancy.

## DISCUSSION

Foreign bodies, implanted into soft tissues, are well known to cause granulomatous reactions. The majority are symptomatic and therefore they are



**Fig. 4.** — A. Multinuclear macrophage, which has ingested metal debris. B. Cholesterol crystals C. Metal Debris D. Granulation tissue E. Lumen.

surgically excised. There have been several cases reported of late presentations of granulomata. Textilomata are inflammatory swellings caused by a retained textile foreign body (1,5). They are most described in abdominal, thoracic and neurosurgery, where surgical cotton material is left behind following procedures. Stoll reported a case, where a cotton pad was left posterior to the lumbosacral vertebrae during a laminectomy operation, and the material eventually caused a cavitory lesion 40 years later (7). Murphy *et al* detected a suture granuloma masquerading as a malignancy of the biliary tract (6).

Tissue reactions to arthroplasty implants have also been described. Mak *et al* reported on an intrapelvic mass resulting from reaction to wear debris after total hip arthroplasty and Chang *et al* described a granulomatous reaction to a failed metal-backed patellar component following total knee arthroplasty, which presented as a giant calf mass (2,4).

We report of a ferro-metallic foreign body reaction caused by a metallic object, which was

implanted in the thigh following an injury 45 years earlier. The initial wound debridement failed to identify and excise the metallic item, which remained asymptomatic for such a long period. The reason for the clinical manifestation of the foreign body reaction after so many years is unknown. The appearance of “calcified regions” in the radiographs and the interaction of the ferro-metallic material with MRI reduced the diagnostic accuracy.

## CONCLUSION

Massive lesions of the limbs are not necessarily soft tissue tumours. This is a rare presentation of a giant cystic reaction to a metallic foreign body, which took place after 45 years of a symptom-free period. To our knowledge it is the longest delay to presentation of a granulomatous reaction in the English literature.

## REFERENCES

1. Abdul-Karim FW, Benevenia J, Pathria MN, Mackley JT. Retained surgical sponge (gossypiboma) with a foreign body reaction and remote and organizing haematoma. *Skel Radiol* 1992 ; 21 : 466-469.
2. Chang FY, Tseng KF, Chen WM, Huang CK, Chen Th, Lo WH. Metal-backed patellar component failure in total knee arthroplasty presenting as a giant calf mass. *J Arthroplasty* 2003 ; 18 : 227-230.
3. Donath K, Laass M, Gunzl HJ. The histopathology of different foreign-body reactions in oral soft tissue and bone tissue. *Virchows Arch A Pathol Anat Histopathol* 1992 ; 420 : 131-137.
4. Mak KH, Wong TK, Poddar NC. Wear debris from total hip arthroplasty presenting as an intrapelvic mass. *J Arthroplasty* 2001 ; 16 : 674-676.
5. Okten AI, Adam M, Gezercan Y. Textiloma : a case of foreign body mimicking a spinal mass. *Eur Spine J* 2006 ; 15 : 626-629.
6. Murphy JR, Shay SS, Moses FM, Braxton J, Jaques DP, Wong RK. Suture granuloma masquerading as malignancy of the biliary tract. *Dig Dis Sci* 1990 ; 35 : 1176-1179.
7. Stoll A. Retained surgical sponge 40 years after laminectomy. A case report. *Surg Neurol* 1988 ; 30 : 235-236.