



Congenital unilateral pseudarthrosis of the olecranon

Leonhard E. RAMSEIER, G. Ulrich EXNER

From the Orthopaedic University Clinic Balgrist, Zurich, Switzerland

Congenital pseudarthrosis of the olecranon is a rare condition. Three isolated cases with bilateral presentation, different treatment modalities and variable outcome were reported in the orthopaedic literature. In this presented case a pseudarthrosis of the right olecranon in a 13-year-old boy was treated by pseudarthrosis resection, bone graft interposition and tension band osteosynthesis. Hardware removal was performed nine months after the initial procedure. At 6-year follow-up at the end of growth, the patient has no pain and a free range of motion of his dominant right elbow. This (to our knowledge) first case of unilateral pseudarthrosis of the olecranon had an excellent clinical result with stable fixation and support of bone healing by a bone graft interposition.

Keywords : congenital ; pseudarthrosis ; olecranon ; non-union.

INTRODUCTION

Congenital pseudarthrosis in the upper extremity is a rare condition affecting either the ulna or the radius or both forearm bones. In orthopaedic literature, approximately 60 cases with different treatment modalities have been described (6). There are only three reported cases of pseudarthrosis of the olecranon, all bilateral (2,4,5). Owing to poor healing conditions of the pseudarthrotic area with conservative or surgical attempts (e.g. excision or osteotomy with osteosynthesis, bone grafting) recent reports have preferred resection of the pseudarthrosis and reconstruction with a free vas-

cularised fibula graft (FVFG) (6). In contrast it appears unnecessary to treat a congenital pseudarthrosis of the olecranon in such an extensive manner (2,4,5). We would like to present the long-term course of a unilateral congenital pseudarthrosis of the right olecranon treated by pseudarthrosis resection, bone graft interposition and stable tension-band compression osteosynthesis.

CASE REPORT

A 13-year-old boy presented with an active extension loss of 25° of his right elbow, with free flexion up to 150°. During palpation there was a painless gap between the olecranon and the ulna with a mobile olecranon part, which could nearly be brought down to the main ulnar bone by gentle pressure. The patient and his parents said there had been no history of trauma to his right elbow, but reported a continued extension deficit since many years (fig 1a-b). As a soccer goalkeeper he was

■ Leonhard E. Ramseier, MD, Orthopaedic Surgeon.

■ G. Ulrich Exner, MD, Professor of Paediatric and Tumour Orthopaedics.

Orthopaedic University Clinic Balgrist, Zurich, Switzerland.

Correspondence : Leonhard Ramseier MD, Orthopaedic University Clinic Balgrist, Forchstrasse 340, CH-8008 Zurich, Switzerland. E-mail : leonhard.ramseier@balgrist.ch

© 2008, Acta Orthopædica Belgica.




Fig. 1a-b. — Preoperative view of the elbow in maximal flexion and extension

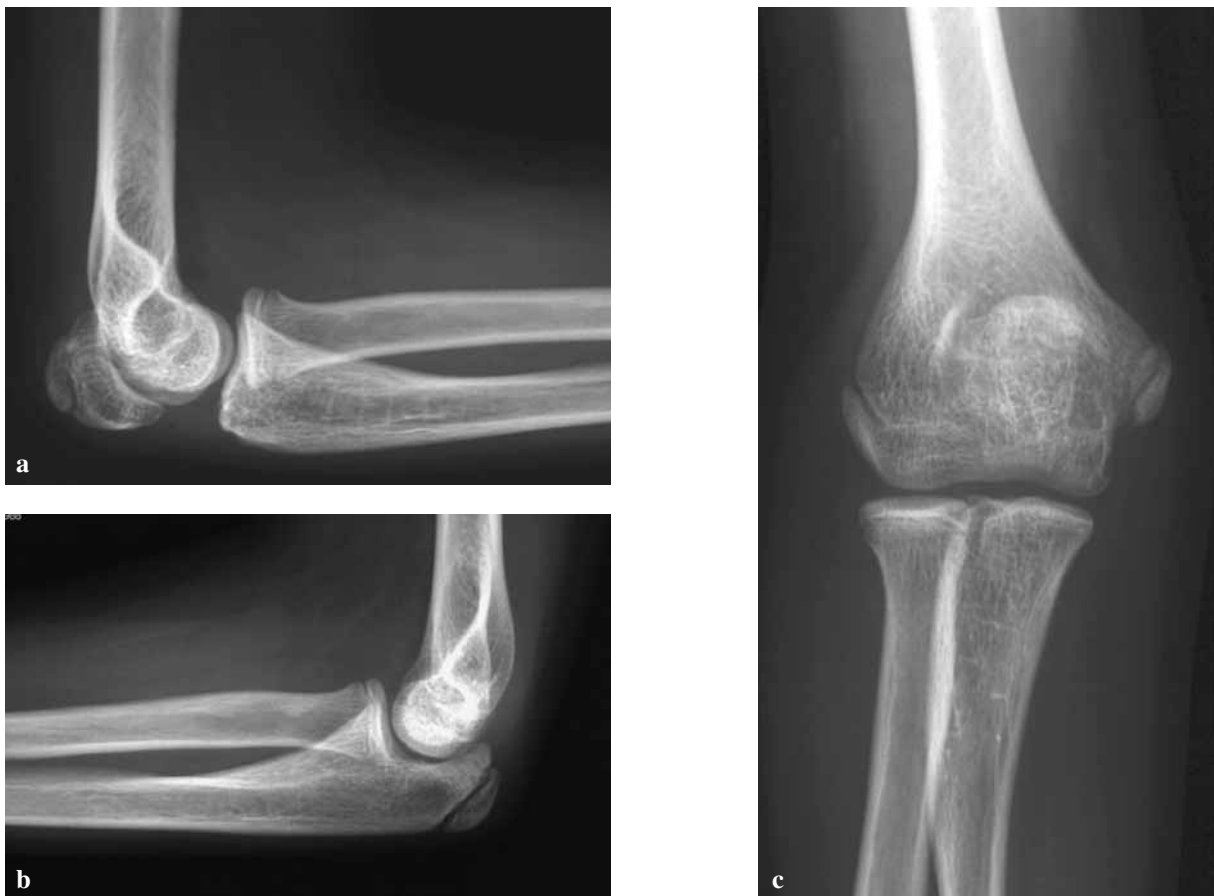

Fig. 2a-c. — Preoperative radiographs show the congenital pseudarthrosis of the olecranon, and the contralateral elbow for comparison.

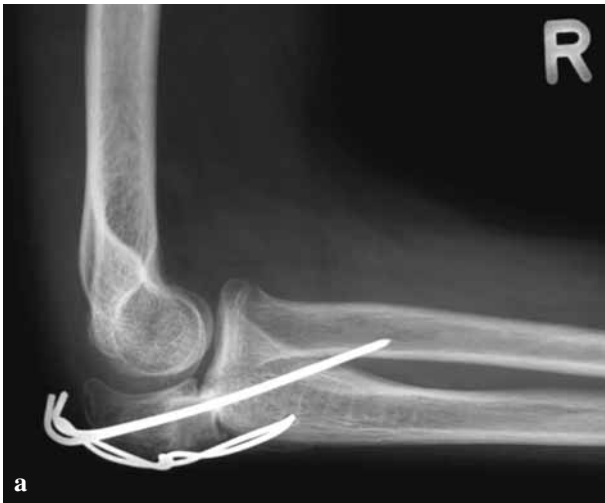
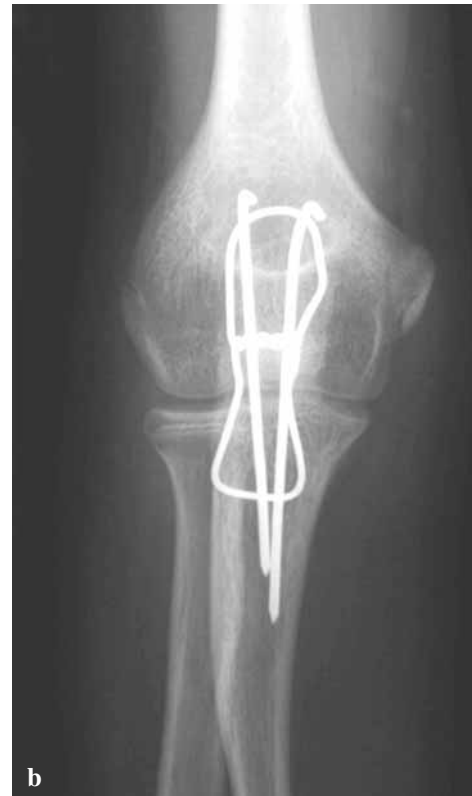
Fig. 3a-b. — Postoperative documentation with the interposed graft in anatomical position.



hampered in catching balls because of the extension deficit. The lateral radiograph of the right elbow showed a radiolucent gap between the olecranon and the ulna, not where the epiphyseal growth plate nor the olecranon apophysis would normally be expected (fig 2a-c). Fluoroscopic examination confirmed the mobility of the fragment and the possibility of nearly congruous adaptation to the upper end of the ulna. The left elbow was clinically and radiographically normal. Due to the disturbing extension lag an operation was performed through an angulated skin incision over the dorsal aspect of the elbow. The soft-tissue mass in the pseudarthrosis was first removed. A bone graft approximately 1×1.5 cm was then harvested from the right iliac crest and was interposed for restoration of the physiological olecranon concavity. Joint congruity was achieved by the readapted olecranon. Final fixation was carried out by a K-wire tension band cerclage (fig 3a-b). Postoperatively the patient wore a dorsal, removable orthosis with the elbow in 90° of flexion for 6 weeks and was allowed to do intermittent active flexion/extension movements. Due to persisting reduction in pronation and extension nine months after the initial procedure, anterior capsulectomy was performed, with posterior debridement of the olecranon fossa in combination with hardware removal. Following this operation the range of

motion improved with physiotherapy and a static extension brace for 6 weeks. At 6-year follow-up, at the end of growth, the patient has no pain and a free range of motion of the dominant right elbow (fig 4a-d).

DISCUSSION

The clinical and radiological presentation of our case differs from the three cases reported (2,4,5) in the literature because of its unilateral involvement and its late clinical presentation. Burge and Benson (2) described a tension-band fixation and cortico-cancellous graft interposition after excision of the pseudarthrotic area in a six-year-old boy. Both affected sides were operated within a 6-month interval, bony healing occurred over a period of four months with improved but not normalised extension (30° extension deficit on the better side) at one-year follow-up. Pouliquen *et al* (5) reported curettage of the fibrocartilage tissue and attachment of the fragments by two nylon threads after V-

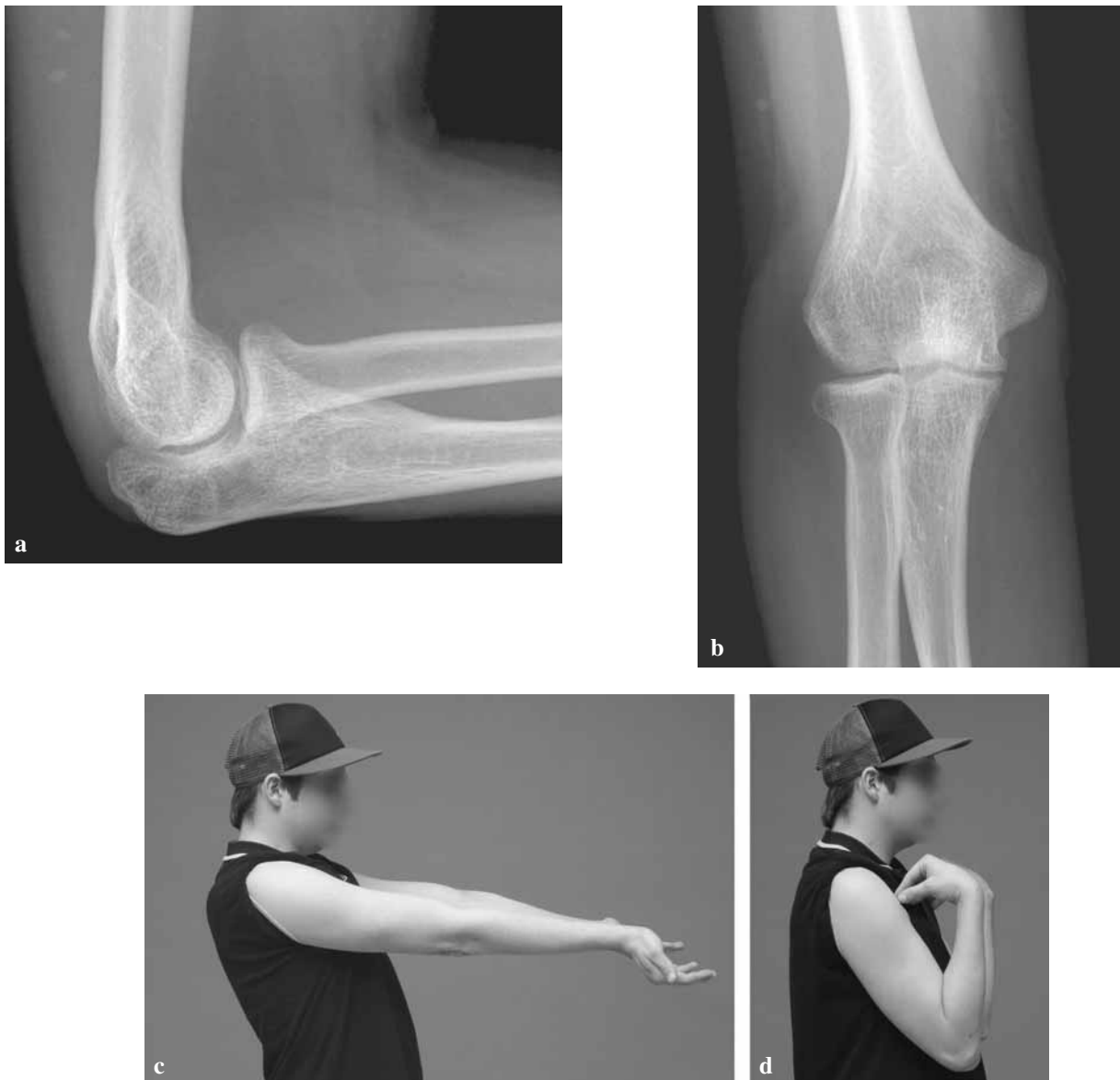

Fig. 4a-d. — Radiographs at latest follow-up with a normal elbow joint ; clinically there was a full range of motion of the right elbow

shaped lengthening of the triceps tendon, followed by 30 days of plaster cast immobilisation in a 15-month-old boy. At 2-year follow-up the patient showed bony fusion with 10° extension deficit on both operated sides. The third reported patient was a 13-year-old boy not hampered by a mild flexion contracture. Because of the asymptomatic presentation no treatment was recommended (4).

Our patient presented as a simple fibrous pseudarthrosis without the typical radiological pat-

tern of a congenital ulna pseudarthrosis like cystic and sclerotic bone lesions, tapered bone ends or medullary canal obliteration. The patient's history included no previous trauma, and a longstanding flexion contracture for many years, making a simple posttraumatic pseudarthrosis unlikely.

We agree with Burge and Benson (2) that congenital olecranon pseudarthrosis seems to be a different clinical entity compared to congenital pseudarthrosis of the ulna mainly because of the radiological

and clinical presentation. The treatment, if necessary, is much easier than the recommended treatment options for congenital ulnar pseudarthrosis like FVFG (1) or construction of a one bone forearm (3). In the previously reported two cases (2,5) and in our presented case the operative site reached bony union following bone grafting and internal fixation after the first procedure. In this presented case there was an additional procedure because of postoperative reduction of range of motion. The additional operative procedure with open anterior capsulectomy, posterior fossa debridement and postoperative wear of a static extension brace for 6 weeks lead to full range of motion.

At latest follow-up, the patient, who has reached skeletal maturity, is pain free with a full range of motion. Based on the three known cases of olecranon pseudarthrosis, treatment by pseudarthrosis resection, bone grafting and internal fixation appears as an adequate treatment modality for this rare orthopaedic problem.

REFERENCES

1. **Allieu Y, Gomis R, Yoshimura M et al.** Congenital pseudarthrosis of the forearm-two cases treated by free vascularized fibular graft. *J Hand Surg* 1981 ; 6-A : 475-481.
2. **Burge P, Benson M.** Bilateral congenital pseudarthrosis of the olecranon. *J Bone Joint Surg* 1987 ; 69-B : 460-462.
3. **Maffulli N, Fixsen JA.** Pseudoarthrosis of the ulna in neurofibromatosis. A report of four cases. *Arch Orthop Trauma Surg* 1991 ; 110 : 204-207.
4. **Pellett J, Iwinski HJ, Bertrand SL.** Bilateral pseudarthrosis of the olecranon. *J South Orthop Assoc* 1997 ; 6 : 93-96.
5. **Pouliquen JC, Pauthier F, Kassis B, Glorion C.** Bilateral congenital pseudarthrosis of the olecranon. *J Pediatr Orthop B* 1997 ; 6-B : 223-224.
6. **Witoonchart K, Uerpaiojkit C, Leechavengvongs S, Thuvasethakul P.** Congenital pseudarthrosis of the forearm treated by free vascularized fibular graft : a report of three cases and a review of the literature. *J Hand Surg* 1999 ; 24-A : 1045-1055.