



Arthroscopic anatomical reconstruction of the acromioclavicular joint

Gian M. SALZMANN, Lars WALZ, Philip B. SCHOETTLE, Andreas B. IMHOFF

From the Department of Orthopaedic Sports Medicine, Klinikum rechts der Isar, Technical University of Munich, Munich, Germany

Traditional techniques for restoration of a separated acromioclavicular joint are afflicted with various complications and often lead to recurrent dislocation. Lately, anatomic as well as minimally-invasive repair techniques with major focus on restoration of the coracoclavicular ligaments have been described for acromioclavicular joint reconstruction. We present a technique for an arthroscopically-assisted anatomical acromioclavicular joint reconstruction by replacing the conoid and trapezoid separately with non-absorbable sutures and titanium buttons.

Keywords: acromioclavicular joint ; instability ; acromioclavicular ; coracoclavicular ; arthroscopy ; anatomical reconstruction.

INTRODUCTION

Acute acromioclavicular (AC) separation is a common injury among young athletes following blunt force to the shoulder during sports activities (5,13). In the uninjured joint the coracoclavicular (CC) ligaments are the major restraint against superior and posterior translation of the distal clavicle with respect to the scapula (6). Rupture of both structures leads to severe acromio-clavicular separation (classified as Rockwood IV-VI) and surgical treatment is recommended (11,13). Current procedures do not restore the strength and stiffness of the native AC-joint and furthermore do not provide an anatomical reduction, providing a two-plane stability (1-3,7,8,11). Based on the biomechanics of the CC ligaments we here describe an arthroscopically-

assisted technique to anatomically replace the CC ligaments with nonabsorbable sutures and titanium buttons to achieve stability in both the vertical as well as the horizontal plane.

SURGICAL TECHNIQUE

The technique is intended to be used in the acute setting only (within 6 weeks post-injury) for repair of Rockwood IV-VI separations and for Rockwood III dislocations in manual labourers or high demand athletes.

The injured shoulder is prepped and draped in sterile fashion and the arm is fixed to a mechanical arm holder. According to data by Rios *et al* (12) the total clavicle length is measured and in addition to standard anatomic landmarks (coracoid, clavicle, acromion, AC-joint, posterior and anterolateral portals 1 and 2) two independent points, representing

-
- Gian M. Salzmänn, MD, Resident.
 - Lars Walz, MD, Resident.
 - Philip B. Schoettle, MD, Fellow.
 - Andreas B. Imhoff, MD, Professor.

Department of Orthopaedic Sports Medicine, Klinikum rechts der Isar, Technical University of Munich, Munich, Germany.

Correspondence : Andreas B. Imhoff, MD, Department of Orthopaedic Sports Medicine, Klinikum rechts der Isar, Connollystrasse 32, 80809 Muenchen, Germany.

E-mail : a.imhoff@sportortho.de

© 2008, Acta Orthopædica Belgica.

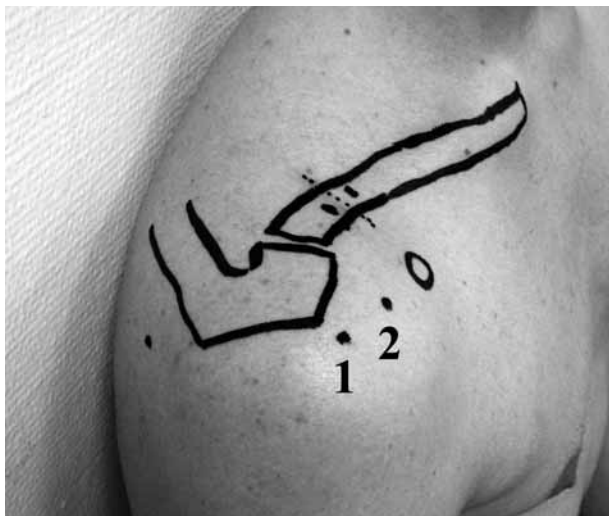

Fig. 1. — Landmarks. Prior to the procedure the total clavicle length is measured. The coracoid, clavicle, acromion, AC-joint, the dorsolateral soft spot, the anterolateral portal one (1) and the anterolateral portal two (2) are marked. On top of the clavicle the skin incision as well as the points for clavicular drilling holes are indicated according to the total clavicle length.

17% (trapezoid insertion, approximately 2.5 cm) and 30% (conoid insertion, approximately 4.5 cm) of the total clavicle length are measured medial to the lateral clavicular edge and are marked for optimal clavicular tunnel placement on top of the clavicle with a sterile pen (fig 1). Initial diagnostic glenohumeral joint arthroscopy is performed with a 30° 4-mm arthroscope through the standard posterior portal. Two anterolateral portals are located through the rotator cuff interval in order to provide working access to the coracoid undersurface (fig 1). The camera is introduced into the subacromial space and a 3.5-mm 90° radiofrequency ablation device (Opes®, Arthrex, FL, USA) is inserted through portal 1. The AC-joint is visualised and the disc is removed if damaged. The arthroscope is reinserted into the glenohumeral joint via the portal 1. By use of the ablation device through portal 2 the coracoid undersurface is prepared circumferentially to visualise the medial and lateral edge as well as the base tip and the precipice of the coracoid. Following coracoid preparation a 3 cm vertical skin incision is set directly over and perpendicular to the clavicle in alignment with the coracoid, between the

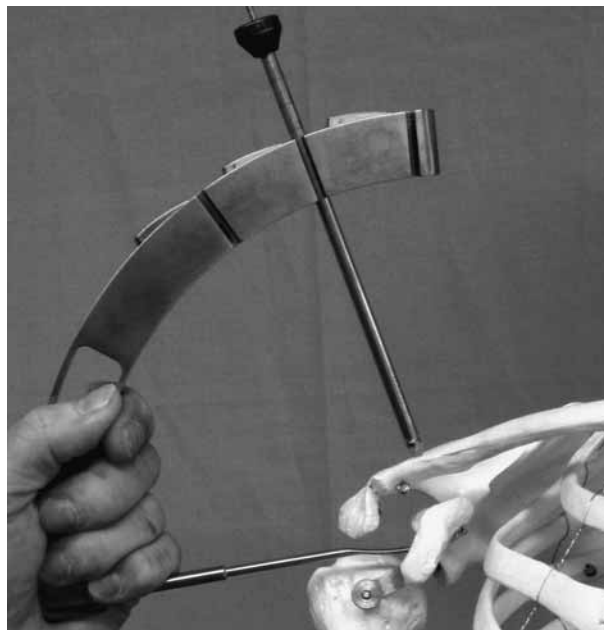


Fig. 2. — Drill guide *in situ*. The guide is inserted through the anterolateral portal two under arthroscopic control from the anterolateral portal one. The sleeve is placed under direct visualisation. The guide can be adjusted to different angles.

previously marked orientation points. The exposed clavicle is then reduced to an anatomic position by elevating the arm against the scapula. A drill guide with a marking hook (fig 2) (Acromioclavicular TightRope™ -ACTR- Drill Guide, Arthrex, FL, USA) is introduced through portal 2) with its tip positioned at the undersurface of the coracoid under arthroscopic control from portal 1. In respect to the previously marked points for the coronal clavicular orientation for conoidal and trapezoidal tunnel placement the drill sleeve is placed on top of the clavicle (fig 3). Optimal tunnel placement of the conoid coracoidal tunnel should be at the posterior aspect of the coracoid close to the base, and the medial edge. The trapezoid coracoidal tunnel should be anterolateral to the conoidal tunnel leaving a bony bridge between tunnels of at least 10 mm. K-wires, equipped with an automatic drill stop to prevent iatrogenic neurovascular injury, are drilled through the clavicle and the coracoid under arthroscopic visualisation until each wire can be seen at the caudal coracoid in an anatomic position. K-wires are left in place and two 3.5-mm bony

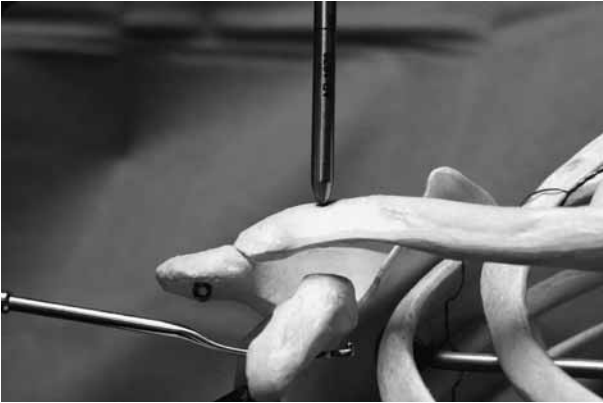


Fig. 3. — Principle of drill guide placement. The tip is placed at the base of the coracoid undersurface. The sleeve is positioned on top of the clavicle.

tunnels are drilled over the K-wires through the clavicle and the coracoid. The cannulated drill bits are maintained while the K-wires and the guiding tool are removed. Two Suturelasso SD wire loops® (Arthrex, FL, USA) are inserted through the cannulation and the drill bits are removed. The loops are connected to each one TightRope™ (Arthrex, FL, USA) outside the superior surface of the clavicle. The TightRope™ device consists of one round clavicular titanium button and one long coracoidal titanium button connected by one No. 5 non-absorbable suture (FiberWire®, Arthrex, FL, USA) organised as a pulley (fig 4). Each device is pulled through the tunnel via portal 2 by the lasso until the caudal (long) buttons can be completely visualised at the coracoid undersurface. Each device is pulled cranially so that the buttons flip and come in place in a locking horizontal anatomic position at the coracoid undersurface. By subacromial arthroscopic control the clavicle is held in reduction in an anatomic position and the clavicular buttons are placed on top of the clavicle under direct visualisation. First the medial and then the lateral device is tightened by aid of the pulley system and secured by alternating knots. The arm is placed in a sling in an adducted and internally rotated position for 6 weeks. Limited range of motion is allowed out of the sling by physiotherapeutic instruction only. Exercises to regain strength are initiated once the patient has full, pain-free passive and active range

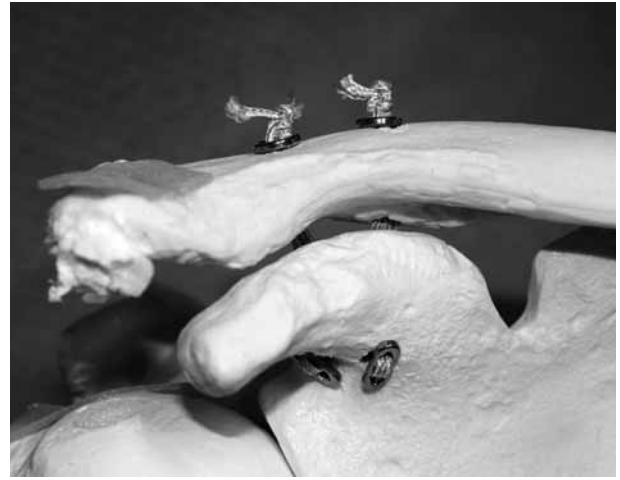

Fig. 4. — Principle of TightRope™ AC-joint repair. Two devices span the space between the coracoid and the clavicle in an anatomic two tunnel manner. The buttons are flipped and the device is tightened.

of motion, not before week 7 post-operatively. Return to contact sports activities is allowed 6 months after the procedure.

DISCUSSION

The CC ligaments are considered the prime suspensory ligaments of the AC-joint (1). Each CC ligament has a different role in providing acromioclavicular joint stability in response to various loading conditions (10). Debski *et al* (2) reported about the conoid being the major restraint against superior and the trapezoid against posterior loading. Traditional techniques do not create an anatomic repair and most do not provide the stability required to withstand common loads until biologic healing has occurred (11). Osteoarthritis, redislocation, pain, malfunction or deformity are frequently reported problems associated with traditional AC-joint surgery (8). Recent operative developments seek to address the CC ligament complex anatomically to gain optimal stability and function (3,7). Different novel techniques for anatomic repair have already been investigated under experimental settings. Dimakopoulos *et al* (4) were the first to describe an anatomic technique *in vivo* using double-loop sutures for repair of acute AC-joint disruptions.

However, techniques described for anatomic AC-joint repair replace or reconstruct the coracoclavicular ligaments with one structure. They do not account for the separate anatomical role of the CC ligament complex. Synchronous to an anatomic approach, AC-joint repair techniques aim to approach the AC-joint arthroscopically assisted (9,14). Nevertheless, previously described arthroscopic techniques do not restore the joint anatomically and furthermore they may not provide the required initial stability. To our knowledge, the reconstruction technique presented here has not been previously described. It provides initial static and dynamic stability in both the vertical as well as the horizontal plane superior to the native CC ligaments (unpublished data). The pulley system allows guided alignment of the clavicle during reduction and fixation with respect to the acromion and can be easily achieved under direct visualisation from the subacromial space in order to avoid malcorrection. The technique described here provides the opportunity to reconstruct the AC-joint in both the vertical as well as the horizontal plane by separately matching the CC ligaments in an anatomical and mechanically stable manner where no graft is needed and no implant removal is required.

REFERENCES

1. Costic RS, Labriola JE, Rodosky MW, Debski RE. Biomechanical rationale for development of anatomical reconstructions of coracoclavicular ligaments after complete acromioclavicular joint dislocations. *Am J Sports Med* 2004 ; 32 : 1929-1936.
2. Debski RE, Parsons IM 3rd, Fenwick J, Vangura A. Ligament mechanics during three degree-of-freedom motion at the acromioclavicular joint. *Ann Biomed Eng* 2000 ; 28 : 612-618.
3. Deshmukh AV, Wilson DR, Zilberfarb JL, Perlmutter GS. Stability of acromioclavicular joint reconstruction : biomechanical testing of various surgical techniques in a cadaveric model. *Am J Sports Med* 2004 ; 32 : 1492-1498.
4. Dimakopoulos P, Panagopoulos A, Syggelos SA *et al.* Double-loop suture repair for acute acromioclavicular joint disruption. *Am J Sports Med* 2006 ; 34 : 1112-1119.
5. Flik K, Lyman S, Marx RG. American collegiate men's ice hockey : an analysis of injuries. *Am J Sports Med* 2005 ; 33 : 183-187.
6. Fukuda K, Craig EV, An KN *et al.* Biomechanical study of the ligamentous system of the acromioclavicular joint. *J Bone Joint Surg* 1986 ; 68-A : 434-440.
7. Grutter PW, Petersen SA. Anatomical acromioclavicular ligament reconstruction : a biomechanical comparison of reconstructive techniques of the acromioclavicular joint. *Am J Sports Med* 2005 ; 33 : 1723-1728.
8. Guttman D, Paksima NE, Zuckerman JD. Complications of treatment of complete acromioclavicular joint dislocations. *Instr Course Lect* 2000 ; 49 : 407-413.
9. Lafosse L, Baier GP, Leuzinger J. Arthroscopic treatment of acute and chronic acromioclavicular joint dislocation. *Arthroscopy* 2005 ; 21 : 1017.
10. Lee KW, Debski RE, Chen CH *et al.* Functional evaluation of the ligaments at the acromioclavicular joint during anteroposterior and superoinferior translation. *Am J Sports Med* 1997 ; 25 : 858-862.
11. Mazzocca AD, Arciero RA, Bicos J. Evaluation and treatment of acromioclavicular joint injuries. *Am J Sports Med* 2007 ; 35 : 316-329.
12. Rios CG, Arciero RA, Mazzocca AD. Anatomy of the clavicle and coracoid process for reconstruction of the coracoclavicular ligaments. *Am J Sports Med* 2007 ; 35 : 811-817.
13. Rockwood CA, Williams G, Young D. Disorders of the acromioclavicular joint. In : Rockwood CJ, Matsen FA III (eds). *The Shoulder*. 2nd ed, WB Saunders, Philadelphia, 1990, pp 483-553.
14. Wolf EM, Pennington WT. Arthroscopic reconstruction for acromioclavicular joint dislocation. *Arthroscopy* 2001 ; 17 : 558-563.