



## Prophylactic intramedullary nailing in monostotic fibrous dysplasia

Bahtiyar DEMIRALP, Cagatay OZTURK, Kutay OZTURAN, Yavuz S. SANISOGLU, Ilker E. CICEK, Kaan ERLER

From Gulhane Military Medical Academy, Ankara, Turkey, Turkish Armed Forces Rehabilitation and Care Center, Ankara, Turkey, and Izzet Baysal University Medical School, Duzce, Turkey

Fibrous dysplasia of bone is an enigma with no known cure. Treatment currently consists of curettage and bone-grafting in an attempt to eradicate the lesion and to prevent progressive deformity. This study presents the results of prophylactic intramedullary nailing in 10 patients with monostotic fibrous dysplasia, pain increasing with movement, and scintigraphically established activity.

Ten patients with monostotic fibrous dysplasia in their upper or lower extremities treated between 2001 and 2003 were included in the study. Seven patients were male and 3 were female; their mean age was 26.9 years. The mean duration of follow-up was 33.5 months. Closed intramedullary nail without reaming was used in all cases. Bone grafting was not performed. Patients were allowed full weight bearing on the affected extremities on the second postoperative day.

Mean VAS for functional pain was  $5.33 \pm 0.65$  preoperatively and  $2.26 \pm 0.57$  at final follow-up ( $p < 0.05$ ). Radiographs showed no changes in lesion size, and the intramedullary fixation appeared to be stable.

Prophylactic intramedullary nailing appeared to be beneficial in monostotic fibrous dysplasia with scintigraphically proven activity and functional pain. It also avoids problems that may occur following pathological fracture.

**Keywords:** fibrous dysplasia; monostotic; surgical treatment; intramedullary nailing.

### INTRODUCTION

Fibrous dysplasia, first identified by Lichtenstein in 1938 (1), is an anomaly characterised by widen-

ing of the affected bone with cortical thinning and presence of fibro-osseous tissue inside the bone. There may also be areas with islands of cartilage or cysts, and some lesions may be expansile. It may present under a monostotic or polyostotic form. Besides these forms, there are McCune Albright and Mazabraud syndromes in which skeletal lesions are observed in conjunction with cutaneous hyperpigmentation and various endocrinopathies, or with soft tissue masses in addition to multiple bone involvement, respectively.

Aetiologically, the X subunit of the G protein localised on the 20q13.2-13.3 chromosome that is encoded by a mutated gene is responsible in

---

■ Bahtiyar Demiralp, MD, Assistant Professor.

■ Ilker E. Cicek, MD, Consultant.

■ Kaan Erler, MD, Professor.

*Gulhane Military Medical Academy, Department of Orthopaedics and Traumatology, Ankara, Turkey.*

■ Cagatay Ozturk, MD, Consultant.

*Turkish Armed Forces Rehabilitation and Care Center, Ankara, Turkey.*

■ Kutay Ozturan, MD, Consultant.

*Izzet Baysal University Medical School, Department of Orthopaedics and Traumatology, Duzce, Turkey.*

■ Yavuz S. Sanisoglu, MD, PhD, Consultant.

*Gulhane Military Medical Academy, Department of Biostatistics, Ankara, Turkey.*

Correspondence : Dr Bahtiyar Demiralp, GATA Ortopedi ve Travmatoloji AD, 06018 Etlik, Ankara, Turkey.

E-mail : rezocagatay@hotmail.com

© 2008, Acta Orthopædica Belgica.

---

patients with McCune Albright syndrome. Cells encoded by this gene are of dysplastic character (1). Kaplan *et al* (9) used polymerase chain reaction (PCR) in peripheral blood cells to demonstrate genetic mutations in patients with isolated fibrous dysplasia, except for patients with McCune Albright syndrome.

Fibrous dysplasia of bone is an enigma with no known cure. Treatment currently consists of curettage and bone-grafting in an attempt to eradicate the lesion and to prevent progressive deformity (3). In addition, Enneking *et al* (3) have also shown that autografts become incorporated soon after grafting, but subsequently turn into dysplastic tissue.

Lesions have a tendency to recur and may result in pathological fractures following curettage and grafting (5). In the multicentric study of the European Paediatric Orthopaedic Society, pathological fractures occurred in 47% of the patients with monostotic fibrous dysplasia (8). Treatment of symptomatic patients should have a long-term perspective and should minimise the risk of recurrence and fracture or deformity which may occur secondarily. No definite criteria have been established to identify patients at high risk of presenting pathological fractures (1).

We present our results with prophylactic intramedullary nailing in 10 patients with monostotic fibrous dysplasia, pain increasing with movement, and scintigraphically established activity. To our knowledge, no previous study has focused on prophylactic intramedullary nailing of the long bones with monostotic fibrous dysplasia in symptomatic patients.

#### PATIENTS AND METHODS

Ten patients with monostotic fibrous dysplasia in their upper or lower extremities, operated between the years 2001 and 2003, were included in the study. Seven patients were male and three were female. Mean age of the patients was 26.9 years (range : 19 to 34). Mean duration of follow-up was 33.5 months (range : 24 to 48). Patients who had been incidentally diagnosed with fibrous dysplasia without functional pain or pathological fractures were excluded from the study, whereas patients who had functional pain and underwent prophylactic intramedullary nailing were included in the study.

Patients whose skeletal development was not completed were excluded since activity of monostotic fibrous dysplasia may regress spontaneously in these cases. Demographic characteristics of the patients are shown in table I.

Lesions were located in the femur in 6, the humerus in 2 and the tibia in 2 of the 10 patients. Lesions were observed on plain radiographs (fig 1a) and magnetic resonance imaging (fig 1b), and activity of the lesion was demonstrated with increased isotope uptake on bone scintigraphy in all of the cases (fig 1c). Scintigraphy also showed absence of involvement of the rest of the skeleton.

Closed Inflated Intramedullary Nailing without reaming was used in all cases. Bone grafting was not performed. Patients were allowed full weight bearing on the affected extremities on the second postoperative day. The Inflatable Nail (Fixion Intramedullary Nailing Systems, Disc-O-Tech Medical Technologies, Herzeliya, Israel) has a short conical end-point connecting four longitudinal bars, with a folded cylindrical chamber inside these bars and a single-direction valve that allows inflation of the chamber with fluid. After insertion of the nail, the special pump was connected to the valve and the nail was inflated with sterile saline with controlled pressure (max. 70 bar), so that the inflatable IMN would adapt to the contour of the endosteal cortex.

Functional pain, size of the lesion on radiographs and stability of prophylactic fixation were evaluated in follow-up visits every 6 months. A visual analogue scale (VAS) was used in assessing functional pain.

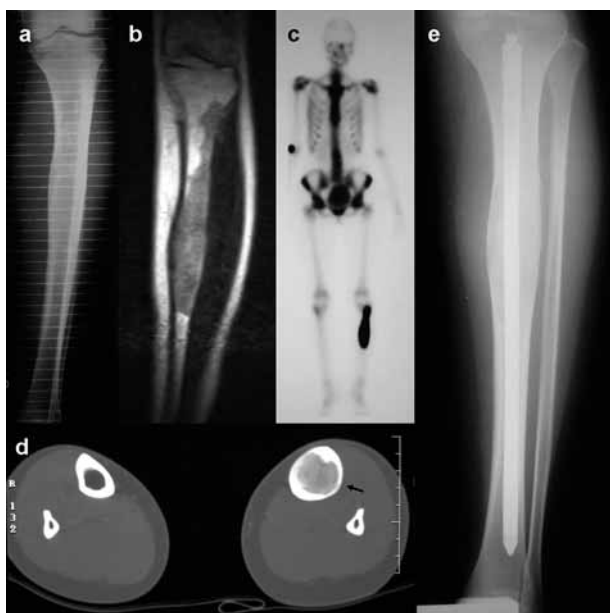
For statistical analysis, Wilcoxon Signed Rank Test (with Bonferroni correction) was used and a p value of less than 0.05 was considered as statistically significant.

#### RESULTS

Mean VAS for functional pain was  $5.33 \pm 0.65$  preoperatively and  $2.26 \pm 0.57$  at final follow-up ( $p < 0.05$ ). Radiographs showed no progression in lesion size and the intramedullary fixation appeared stable. A non-displaced fracture occurred two months postoperatively following a road traffic accident in one patient who had a lesion in the metaphyso-diaphyseal part of his left femur. A 5° varus angulation of the intramedullary nail was noted and was considered acceptable. Conservative treatment with a long leg cast was applied for 6 weeks.

Table I. — Demographic characteristics and outcomes of the patients

Case	Sex	Age (yr)	Site	Indication for surgery	Follow-up (month)	Preoperative VAS	Last follow-up VAS
1	M	22	Femur diaphysis	Functional pain, fracture risk	30	4.9	1.7
2	F	34	Femur diaphysis	Functional pain, fracture risk	44	5.8	2.4
3	M	19	Distal femur metadiaphysis	Functional pain, fracture risk	26	6.4	2
4	F	29	Femur diaphysis	Functional pain, fracture risk	31	5.3	1.8
5	M	29	Femur diaphysis	Functional pain, fracture risk	24	6.1	3
6	M	22	Femur diaphysis	Functional pain, fracture risk	28	4.9	2.5
7	M	20	Humerus diaphysis	Functional pain, fracture risk	27	4.5	2.9
8	M	32	Humerus diaphysis	Functional pain, fracture risk	40	5.7	3
9	F	29	Tibia diaphysis	Functional pain, fracture risk	37	5.2	1.5
10	M	32	Tibia diaphysis	Functional pain, fracture risk	48	4.5	1.8



**Fig. 1.** — (a) Anteroposterior plain radiograph of a 32-year-old male patient showing fibrous dysplasia of the tibia. (b) MRI demonstrates the extent of lesion. (c) Scintigraphy shows the monostotic involvement. (d) CT of both tibiae. Note the thinned cortex (black arrow) when compared with the normal tibia. (e) Post-operative plain radiograph of the same patient after intramedullary nailing.

Pathological fractures and deformities secondary to the lesion occurred in none of the patients.

## DISCUSSION

Lichtenstein (11) is credited with having coined the term fibrous dysplasia in 1938 ; in 1942, Lichtenstein and Jaffe (12) reviewed all known cases of this entity. Those authors established that fibrous dysplasia of bone was a distinct pathological and clinical condition.

Fibrous dysplasia may occur due to a failure in remodelling of primitive bone into mature lamellar bone, which negatively affects the mechanical properties of the affected bone. Thus pain, deformities, and pathological fractures may occur (1).

Fibrous dysplasia has traditionally been divided into three clinical forms : monostotic, polyostotic and endocrinopathic (McCune-Albright syndrome) (7). It is generally accepted that monostotic lesions are easier to treat, are associated with better outcomes, necessitate fewer operations and result in fewer fractures (4).

Healing after pathological fractures in dysplastic bones is comparable with that of normal bone. However, the callus includes dysplastic bone tissue (2). The lesion persists despite healing of the fracture.

The accepted principle in the treatment of lesions that are painful or at risk for fracture, even if asymptomatic, is curettage and grafting (6). However, according to our review of the literature, it is uncertain whether this form of treatment offers a definitive solution (7). It has also been reported that curettage or biopsy of an isolated lesion may predispose the bone to pathological fracture or progression of the lesion (5). There is no accurate indication of the rate of success of curettage and bone grafting. In their study on patients with fibrous dysplasia localised in the neck of the femur, Guille *et al* (6) have shown that the lesion was not eradicated with curettage and grafting, and the bone was further weakened due to deformation of the trabecular structure in dysplastic bone as a result of curettage. In the present series, we did not perform curettage and bone grafting.

Resorption and recurrence secondary to grafting after curettage are other problems. Guille *et al* (7) have shown in their study that all cancellous or cortical grafts they used, in addition to autogenous fibular strut grafts, were resorbed. In addition, according to DiCaprio and Enneking (1), cortical grafts are more durable compared to cancellous grafts, as they are only partly replaced by dysplastic host bone: only their osteonal portion (about 50% of the graft) is replaced by dysplastic bone, whereas the interstitial lamellae are not replaced and persist.

The size of the lesion may change with skeletal growth; however it is difficult to differentiate whether this is secondary to skeletal growth or to progression of the lesion (4). Since fibrous dysplasia is a genetic disorder which is not curable, the treatment modality should be long lasting. No definite criteria are available to state in which cases pathological fracture will occur (1). In the multicentric study of the European Paediatric Orthopaedic Society, fractures had occurred in 47% of patients with monostotic fibrous dysplasia (8). Therefore, we recommend prophylactic intramedullary fixation in

patients with monostotic fibrous dysplasia. This prophylactic therapy avoids complications such as delayed union and deformities following fracture.

A vascularised fibula has been used in some cases following fracture (10). It appears more reasonable to take the necessary steps to prevent fracture, considering the technical difficulty, delayed weight bearing, risks of graft resorption and re-fracture in addition to high costs, if the affected bone is not strengthened and fractures.

The occurrence of a non-displaced fracture in the distal femur in one of our subjects following a traffic accident two months after prophylactic nailing supports our policy. This patient did not require any additional treatment, whereas he would likely have required a problematic internal fixation for his fracture, had the nail not been present.

Reaming was not used prior to nailing in our patients, as it was deemed unnecessary for prophylactic nailing of non-fractured long bones, added to the fact that it might have contributed to weakening the bone to some extent.

As a result of this study, we believe that prophylactic intramedullary fixation can be performed successfully in cases of monostotic fibrous dysplasia with scintigraphically proven activity and functional pain. This will avoid problems that may occur following pathological fractures.

## REFERENCES

1. DiCaprio MR, Enneking WF. Fibrous dysplasia. Pathophysiology, evaluation, and treatment. *J Bone Joint Surg* 2005 ; 87-A : 1848-1864.
2. Enneking WF. Fibrous lesions originating in bone. In: Enneking WF (ed). *Muskuloskeletal Tumor Surgery*, Churchill-Livingstone, New York, 1983, pp 855-867.
3. Enneking WF, Gearen PF. Fibrous dysplasia of the femoral neck. Treatment by cortical bone-grafting. *J Bone Joint Surg* 1986 ; 68-A : 1415-1422.
4. Funk FJ Jr, Wells RE. Hip problems in fibrous dysplasia. *Clin Orthop* 1973 ; 90 : 77-82.
5. Grabias SL, Campbell CJ. Fibrous dysplasia. *Orthop Clin North Am* 1977 ; 8 : 771-783.
6. Guille JT, Kumar SJ, Shah A. Spontaneous union of a congenital pseudarthrosis of the tibia after Syme amputation. *Clin Orthop* 1998 ; 351 : 180-185.
7. Guille JT, Kumar SJ, MacEwen GD. Fibrous dysplasia of the proximal part of the femur. *J Bone Joint Surg* 1998 ; 80-A : 648-658.

8. **Ippolito E, Bray EW, Corsi A et al.** Natural history and treatment of fibrous dysplasia of bone : a multicenter clinicopathologic study promoted by the European Pediatric Orthopaedic Society. *J Pediatr Orthop B* 2003 ; 12 : 155-177.
9. **Kaplan FS, Fallon MD, Boden SD, Schmidt R, Senior M, Haddad JG.** Estrogen receptors in bone in a patient with polyostotic fibrous dysplasia (McCune-Albright syndrome). *N Engl J Med* 1988 ; 319 : 421-425.
10. **Kumta SM, Leung PC, Griffith JF, Kew J, Chow LT.** Vascularized bone grafting for fibrous dysplasia of the upper limb. *J Bone Joint Surg* 2000 ; 82-B : 409-412.
11. **Lichtenstein L.** Polystotic fibrous dysplasia. *Arch Surg* 1938 ; 36 : 874-898.
12. **Lichtenstein L, Jaffe HL.** Fibrous dysplasia of bone. A condition affecting one, several or many bones, the graver cases of which may present abnormal pigmentation of skin, premature sexual development, hyperthyroidism or still other extraskeletal abnormalities. *Arch Pathol* 1942 ; 33 : 777-816.