



Acromioclavicular joint reconstruction using the Nottingham Surgilig : A preliminary report

Rajarshi BHATTACHARYA, Lorna GOODCHILD, Amar RANGAN

From James Cook University Hospital, Middlesbrough, United Kingdom

Eleven patients with a chronic acromio-clavicular joint disruption underwent acromio-clavicular joint stabilisation using the Nottingham Surgilig and were followed up clinically and radiologically for an average of 24 months post operation.

The mean post-operative Constant score was 83.1, the Imatani score was 81.2 and the Walsh score was 14.1. Eighty-two per cent of patients were satisfied with the operation. There was one case of rupture through the central portion of the Surgilig, and following laboratory analysis, the ligament has been modified since. In 4 patients there was evidence of loosening of the screw but only one complained of this being a problem.

This short-term outcome analysis of the Nottingham Surgilig is the first such report outside the Nottingham unit where the prosthesis was originally developed. Our results are encouraging and justify further use and evaluation of this relatively new technique.

Keywords : acromioclavicular joint disruption ; chronic ; reconstruction ; Surgilig.

and Allman (1) as incomplete (Grades I and II) and complete (Grade III). Rockwood *et al* (18) expanded the original classification to include six types of injuries. The ideal treatment of the Type 3 injury remains a matter of debate.

Although various methods of stabilising the disruption of the A-C joint have been described using the coracoacromial ligament (4,6,11,13,20,24,25), the need to preserve this ligament where possible has also been acknowledged in the literature (12,14). Over the years, the methods that have been used on their own or in conjunction with the coraco-acromial ligament for the reconstruction of the coraco-clavicular ligament include PDS (16), merse-lene (17), Dacron (5,22) or Dacrylene (15), carbon fibre (2) and coraco-clavicular screw (24).

More recently, a braided synthetic ligament, the Nottingham Surgilig, was developed for this purpose, using polyester fibres, similar to that used for

INTRODUCTION

Acromio-clavicular (A-C) joint disruption is a relatively common injury (10). There is a significant male preponderance of this injury and the most common mechanism is a direct force occurring from a fall on the point of the shoulder (18). A-C joint injuries have been classified by Tossy *et al* (21)

■ Rajarshi Bhattacharya, MBBS, MRCS (Edin), MRCS (Glas), MSc (Orth), Specialist Registrar in Orthopaedics.

■ Lorna Goodchild, BSc (Physio) MCSP, MACP, Senior Physiotherapist.

■ Amar Rangan, FRCS (Glas) MCh (Orth) FRCS Ed (Orth), Consultant Orthopaedic Surgeon.

Department of Trauma and Orthopaedic Surgery, James Cook University Hospital, Middlesbrough, United Kingdom.

Correspondence : R. Bhattacharya, 11 Carham Close, Gosforth, Newcastle Upon Tyne, NE3 5DX, United Kingdom.
E-mail : drbhattacharya@yahoo.com

© 2008, Acta Orthopædica Belgica.




Fig. 1. — The Nottingham Surgilig with 2 loops and fixation screw.

anterior cruciate ligament reconstruction in the knee. We report our experience with the use of this ligament for A-C joint reconstruction especially in cases of longstanding A-C joint instability.

MATERIALS AND METHODS

The Nottingham Surgilig is a braided polyester ligament with a loop at each end (fig 1). One of the loops is stiff and called the hard loop, which is used for screw fixation. The other loop, called the soft loop is used to thread the ligament through itself. The ligament is passed around the coracoid process threaded through itself, passed around the back of the clavicle and then anchored to the clavicle using a screw. The prosthetic ligament is available in sizes from 5 to 20 cm in increments of 1 cm. The standard instruments available for prosthesis insertion include a curved rasp, a cannulated positioner, a tubular introducer and a loop tensioner (fig 2) along with a Surgilig length gauge with a metal leader (fig 3).

Eleven patients (10 male and 1 female) underwent A-C joint stabilisation using the Nottingham Surgilig. The average gap period between the injury and the stabilisation procedure was 21 months (range : 5 to 41). Only in one case was the operation done relatively early, at 5 months following injury, due to impending breakdown of the overlying skin as a result of pressure from the lateral end of the clavicle. All the remaining patients had long standing A-C joint instability, of at least a year or more, with associated symptoms mainly of pain and

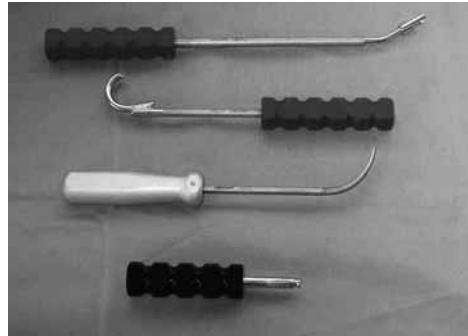


Fig. 2. — Instruments for the Surgilig from above down : 1. loop tensioner, 2. tubular introducer, 3. curved rasp, 4. cannulated positioner.




Fig. 3. — Tubular introducer with Surgilig length gauge

functional disability, following an initial disruption of Rockwood Type 3 or above and had a course of conservative treatment.

All the patients received a similar postoperative follow-up regime involving immobilisation in a poly sling for 2 weeks followed by supervised physiotherapy to full mobilisation as tolerated.

Operative technique

A vertical skin incision is made from above the clavicle to the coracoid. An incision is then made along the lateral 2 cm of the clavicle, dividing the periosteum as far as the displaced lateral end of the clavicle. The lateral 1 cm of the clavicle is excised.

The base of the coracoid is identified with a blunt instrument and then the Surgilig Tubular Introducer (fig 2) is passed around the base of the coracoid with its tip passed adjacent to the bone from the medial side downwards staying close to the bone. The Surgilig Length Gauge, which has a loop at each end and a metal leader in front of one of the loops (fig 2), is then fed into

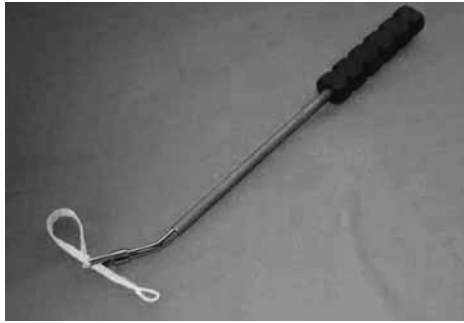


Fig. 4. — Surgilig with loop tensioner

the Tubular Introducer (fig 3) using the metal leader as the advancing end.

Holding the Surgilig Length Gauge that has exited from the Tubular Introducer, the Introducer is then removed, leaving the measuring tape of the Gauge around the coracoid. The measuring tape is then looped around the coracoid in the same way as the ligament would be and passed up and behind the lateral end of the clavicle and the clavicle is reduced to its normal alignment, flush with the level of the acromion and the appropriate length of the prosthesis can be chosen from the measuring tape.

Two fixation positions are acceptable, either aiming for the hard loop of the Surgilig to lie at the posterior or superior edge of the clavicle. The aim is to achieve a slight degree of over correction of the clavicular reduction.

The appropriate length of Surgilig now replaces the Surgilig Length Gauge by daisy chaining the Surgilig onto the Length Gauge. The Surgilig is then passed around the base of the coracoid and the hard loop is threaded through the soft loop, so that the soft loop sits on the clavicular (superior) side of the coracoid. The Surgilig should sit flat on the coracoid and not be twisted. Any bony spikes are gently removed from the clavicle with the Curved Rasp (fig 2). The Surgilig is snugged up to the coracoid using the Surgilig Loop Tensioner (fig 4).

The Surgilig is then passed behind the clavicle. The Tubular Introducer is now inserted through the loop of Surgilig and used to apply traction on the Surgilig to allow accurate reduction of the clavicle.

A drill hole is now made in the clavicle at the position of the hard loop of the Surgilig and the Surgilig is fixed with a bicortical screw inserted through the loop and into the clavicle. It is important that the Surgilig is not twisted and there is no slack in the ligament (fig 5).

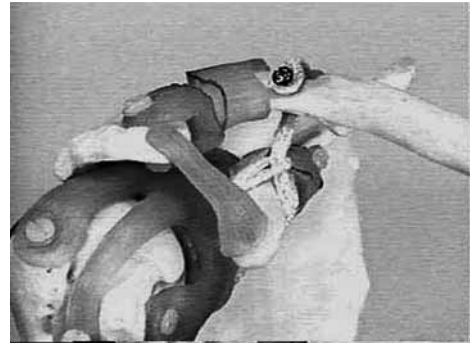


Fig. 5. — Final position of Surgilig in an anatomical model

Postoperatively, the arm is supported in a sling for 2 weeks and then mobilised with supervised physiotherapy.

Follow-up

This was a prospective cohort study involving 11 patients all of whom were followed-up to an average period of 24 months (range : 6 to 76) post operation. Except for one patient who had a revision procedure at 6 months, all the other patients had a minimum follow-up of 12 months. The follow-up protocol consisted of clinical and radiological examinations (fig 6), with plain radiographs of the A-C joint, and collection of data for the Constant-Murley, the Imatani (7) and the Walsh (23) scores. The average age of the patient cohort was 35.1 years (range : 21 to 56). There were an equal number of operations on the right and left sides and on dominant and non-dominant sides.

RESULTS

At follow-up, clinical examination showed satisfactory outcome in most of the patients. Nine (82%) were satisfied with the overall procedure, with good functional outcome. This was corroborated by the good scores obtained in the outcome measurement questionnaires.

The detailed scores are presented in table I. Clinically, there was prominence of the fixation screw in 4 cases and radiographs showed lucency around the screws, but only one of the cases complained of any pain or discomfort. However, he declined surgery for screw removal. Unfortunately, his individual low scores affected the mean scores of the study despite all the other patients scoring

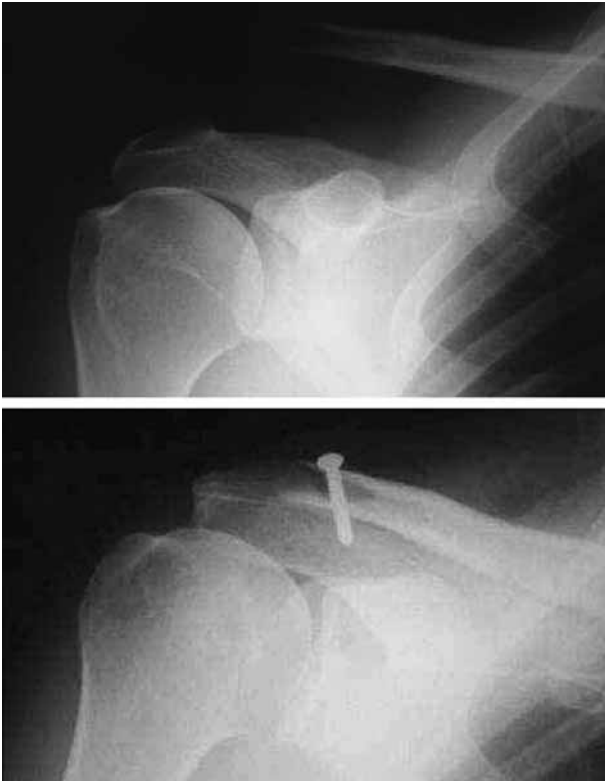


Fig. 6. — Pre-operative and post-operative x-rays

reasonably well in all three scoring systems (table II). There was a rupture of the central portion of the ligament in one patient after 6 months and this had to be revised with a clavicular hook plate, hence this patient's follow-up was considered only till 6 months. All the patients in the above study had been treated with the unmodified ligament but only one had the ligament rupture. Following detailed analysis of this retrieved ligament, the prosthesis has since been reinforced and strengthened in the central portion.

DISCUSSION

Surgery for A-C joint separation has remained a debated issue over the years. When surgical treatment is indicated, there are a variety of operations to choose from that have varying degrees of success reported in the literature (3).

The Weaver-Dunn procedure, where the coraco-acromial ligament is detached from its acromial

Table I. — Postoperative scores

	Mean	Standard deviation	Range
Post-op Constant score	83.1	12	61-100
Post-op Imatani score	81.2	19.4	51-98
Post-op Walsh scores	14.1	4.3	8-20

Constant score : 0 to 100. Normal is 100.

Imatani score : 0 to 100. Normal is 100.

Walsh score : 0 to 20. Normal is 20.

insertion and reattached within the intramedullary cavity of the clavicle has gained considerable popularity. Other methods of A-C joint fixation using the coraco-acromial ligament have also been proposed (4,6,11,13,20,25). More recently, the importance of preserving the subacromial arch and specifically the coraco-acromial ligament has been stressed (12,14). Biomechanical studies have shown that release of the coraco-acromial ligament can lead to increased glenohumeral joint translation and laxity (14) while phylogenetic analyses have stressed the role of the coraco-acromial ligament to provide increased mechanical stability of the shoulder (12). The coraco-acromial ligament also acts as a buffer between the acromion and the rotator cuff and this buffering action is lost in coraco-acromial ligament transection (19). An advantage of the Surgilig is the sparing of the coraco-acromial arch. Besides, occasionally, patients present with failed Weaver-Dunn procedures or a repeat A-C joint disruption after other types of previous stabilisation with the coraco-acromial ligament. The Nottingham Surgilig would be a useful alternative to consider in these situations.

Our series is based mainly on the results of late reconstructions of chronic Rockwood Type 3 A-C joint disruption. Although the literature describes various forms of surgery in A-C joint disruption, very few papers deal with the results of surgery in symptomatic chronic injuries having late reconstruction (3,4,6,15,25) and even fewer look exclusively at grade 3 injuries (25). Most of the papers report a mixed population of injuries. While some of these have a very few chronic cases (24), some fail to report the results of the chronic group separately (9). Besides the lack of homogeneity in the study

Table II. — Detailed results of the patients

Patient	Age	Injury to operation time (months)	Follow-up (months)	Constant	Imatani	Walsh
1	37	23	76	88	86	16
2	56	25	34	94	97	15
3	22	5	33	78	51	9
4	25	8	29	90	85	20
5	30	13	22	78	76	12
6	24	41	14	95	93	14
7	43	25	14	61	52	8
8	46	24	14	79	97	17
9	51	18	12	92	98	19
10	21	33	6	71	67	10
11	31	12	14	88	91	15

groups, the outcome measures used in the different papers also vary widely. Most of the authors have assessed patients using self-prepared evaluation systems. Very few papers have used A-C joint specific scores and even in those that have, there is no uniformity of the scoring system used. As a result of this variation in study group and outcome measures, a direct comparison of the results with our series becomes very difficult.

The overall success rate in A-C joint surgery, both acute and chronic, is around 90% as reported by various authors (4,6,13,15,24,25), while in the case of late reconstruction the success rate has been reported at around 78% (4,6,25). In our unit, the use of the Surgilig ligament in case of chronic AC joint disruptions has yielded comparable overall results to the other techniques of late reconstructions reported in the literature. Additionally, the Surgilig can be loaded immediately and mobilised early unlike the Weaver-Dunn procedure. The initial resting period is purely for scar healing. Unlike previous published studies where patients had untoward reactions to the synthetic materials used for coracoclavicular ligamentoplasty (5,15), none of our patients reported any tolerance problems to the material used in Surgilig.

CONCLUSION

The Nottingham Surgilig is a relatively new technique for A-C joint reconstruction. A recent

series from the Nottingham Unit, where the ligament was initially developed, has shown promising results with this technique (8). Our series is however, the first report from an independent centre outside Nottingham, and despite the relatively small number of cases, based on our experience of this artificial ligament, these short term results would justify further use and evaluation of this technique.

REFERENCES

1. **Allman FL Jr.** Fractures and ligamentous injuries of the clavicle and its articulation. *J Bone Joint Surg* 1967 ; 49-A : 774-784.
2. **Burri C, Neugebauer R.** Carbon fibre replacement of the ligaments of the shoulder girdle and the treatment of lateral instability of the ankle joint. *Clin Orthop* 1985 ; 196 : 112-117.
3. **Dewar FP, Barrington TW.** The treatment of chronic acromioclavicular dislocation. *J Bone Joint Surg* 1965 ; 47-B : 32-35.
4. **Dumontier C, Sautet A, Man M, Apoil A.** Acromioclavicular dislocations : treatment by coracoacromial ligamentoplasty. *J Shoulder Elbow Surg* 1995 ; 4 : 130-134.
5. **Goldberg JA, Viglione W, Cumming WJ et al.** Review of coracoclavicular ligament reconstruction using Dacron graft material. *Austr N Z J Surg* 1987 ; 57 : 441-445.
6. **Guy DK, Wirth MA, Griffin JL, Rockwood CA Jr.** Reconstruction of chronic and complete dislocations of the acromioclavicular joint. *Clin Orthop* 1998 ; 347 : 138-149.
7. **Imatani RJ, Hanlon JJ, Cady GW.** Acute, complete acromioclavicular separation. *J Bone Joint Surg* 1975 ; 57-A : 328-331.

8. **Jeon IH, Dewnany G, Hartley R et al.** Chronic acromioclavicular separation : The medium term results of coracoclavicular ligament reconstruction using braided polyester prosthetic ligament. *Injury* 2007 ; 38 : 1247-1253.
9. **Kawabe N, Watanabe R, Sato M.** Treatment of complete acromioclavicular separation by coracoacromial ligament transfer. *Clin Orthop* 1984 ; 185 : 222-227.
10. **Koval KJ, Zuckerman JD.** *Handbook of Fractures*. 2nd edition. Lippincott Williams and Wilkins, London, 2002, p 68.
11. **Kumar S, Sethi A, Jain AK.** Surgical treatment of complete acromioclavicular dislocation using the coracoacromial ligament and coracoclavicular fixation : report of a technique in 14 patients. *J Orthop Trauma* 1995 ; 9 : 507-510.
12. **Kummer FJ, Blank K, Zuckerman JD.** Coracoacromial ligament function : a phylomorphic analysis. *Bull Hospital Joint Disease* 1996 ; 55 : 72-74.
13. **Kutschera HP, Kotz RI.** Bone-ligament transfer of coracoacromial ligament for acromioclavicular dislocation. A new fixation method used in 6 cases. *Acta Orthop Scand* 1997 ; 68 : 246-248.
14. **Lee TQ, Black AD, Tibone JE, McMahon PJ.** Release of coracoacromial ligament can lead to glenohumeral laxity : a biomechanical study. *J Shoulder Elbow Surg* 2001 ; 10 : 68-72.
15. **Mathieu L, Rongieras F, Fascia P et al.** [Acromioclavicular dislocations treated by synthetic coraco-clavicular ligamentoplasty.] (French) *Rev Chir Orthop* 2007 ; 93 : 116-125.
16. **Motamadi AR, Blevins FT, Willis MC et al.** Biomechanics of the coracoclavicular ligament complex and augmentations used in its repair and reconstruction. *Am J Sports Med* 2000 ; 28 : 380-384.
17. **Pearsall AW 4th, Hollis JM, Russell GV Jr, Stokes DA.** Biomechanical comparison of reconstruction techniques for disruption of the acromioclavicular and coracoclavicular ligaments. *J South Orthop Assoc* 2002 ; 11 : 11-17.
18. **Rockwood CA Jr, Williams GR, Young DC.** Injuries to the acromioclavicular joint. In : Rockwood and Green (eds). *Fractures in Adults*. 4th edition. Lippincott-Raven, London, 1996.
19. **Salter EG Jr, Nasca RJ, Shelley BS.** Anatomical observations on the acromioclavicular joint and supporting ligaments. *Am J Sports Med* 1987 ; 15 : 199-206.
20. **Tienan TG, Oyen JE, Eggen PJ.** A modified technique of reconstruction for complete acromioclavicular dislocation : a prospective study. *Am J Sports Med* 2003 ; 31 : 655-659.
21. **Tossy JD, Mead MC, Simmond HM.** Acromioclavicular separations : Useful and practical classification for treatment. *Clin Orthop* 1963, 28 : 111-119.
22. **Verhaven E, DeBoeck H, Haentjens P et al.** Surgical treatment of acute type-V acromioclavicular injuries in athletes. *Arch Orthop Trauma Surg* 1993 ; 112 : 189-192.
23. **Walsh WM, Peterson DA, Shelton G, Neumann RD.** Shoulder strength following acromioclavicular injury. *Am J Sports Med* 1985 ; 13 : 153-158.
24. **Weaver JK, Dunn HK.** Treatment of acromioclavicular injuries, especially complete acromioclavicular separation. *J Bone Joint Surg* 1972 ; 54-A : 1187-1194.
25. **Weinstein DM, McCann PD, McIlveen SJ et al.** Surgical treatment of complete acromioclavicular dislocations. *Am J Sports Med* 1995 ; 23 : 324-331.