



Lymphangiomyoma of the shoulder : An exceptional localisation A case report

Mostapha BOUSSOUGA, Anas HARKET, Nabile BOUSSELMAME, Khalid LAZRAK

From Mohamed V Military Hospital, Rabat, Morocco

Lymphangiomyomatosis (LAM) is a rare condition usually occurring in young women of child-bearing age. It is characterised by the presence of abnormal smooth muscle cells (LAM cells) in the lungs, lymph nodes, and/or other organs, with a few reports of isolated extrapulmonary cases. We report the case of a 26-yr-old female who presented with a painless shoulder mass. Ultrasonography, computed tomography and magnetic resonance imaging revealed an intermuscular mass with cystic and solid tissue components, measuring 6 cm × 4 cm. The mass was removed surgically after the diagnosis of LAM was made following tru-cut biopsy. This case corresponds to an exceptional localisation of LAM.

Keywords : lymphangiomyoma ; extrapulmonary ; hamartoma ; smooth muscle tumour.

CASE REPORT

A 26-year-old female was noted to have a large painless mass over her right shoulder during a routine physical examination. The mass had been present for at least six months. There was no history of trauma. Clinical examination revealed a poorly delimited non inflammatory mass, measuring 6 × 8 cm, located at the posterior aspect of the shoulder. Standard radiographs of the shoulder did not show any osseous involvement. Contrast-enhanced CT examination of the shoulder was performed and revealed a 6 × 4 × 6 cm mass containing both solid and cystic components, with the solid components showing heterogeneous enhancement (fig 1).

INTRODUCTION

Lymphangiomyomatosis (LAM) is a rare condition of unknown aetiology, characterised by proliferation of abnormal lymphatic smooth muscle cells. It generally presents with features of pulmonary involvement. The condition has also been reported elsewhere, in the mediastinum, and the retroperitoneum. We report an unusual case of an isolated localised form of LAM limited to the posterior shoulder region.

- Mostapha Boussouga, MD, Assistant Professor.
- Nabile Bousselmame, MD, Professor.
- Khalid Lazrak, MD, Professor.

Orthopaedic surgery department, Mohamed V Military Hospital, Rabat, Morocco.

Anas Harket, MD, Assistant Professor.

Pathology department, Mohamed V Military Hospital, Rabat, Morocco.

Correspondence : Mostapha Boussouga, 328, Groupe Elmajd, HayNahda II, Rabat, Morocco.

E-mail : bousiken@yahoo.fr

© 2008, Acta Orthopædica Belgica.

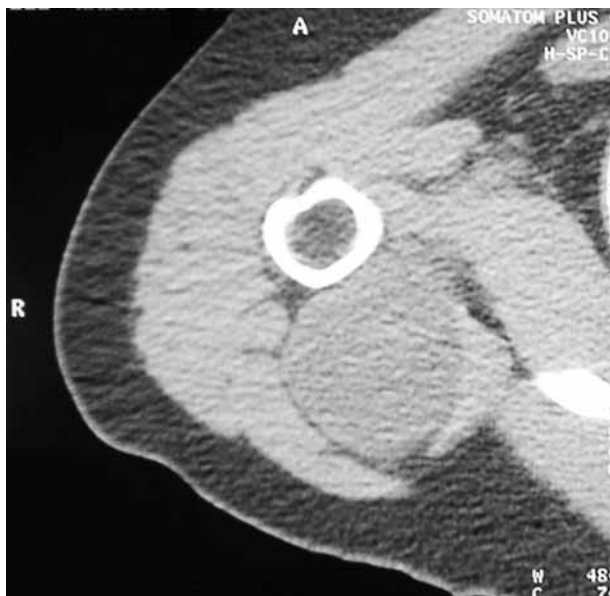

Fig. 1. — CT examination of the shoulder revealing a 6 × 4 × 6 cm mass containing both solid and cystic components, with the solid components showing heterogeneous enhancement.

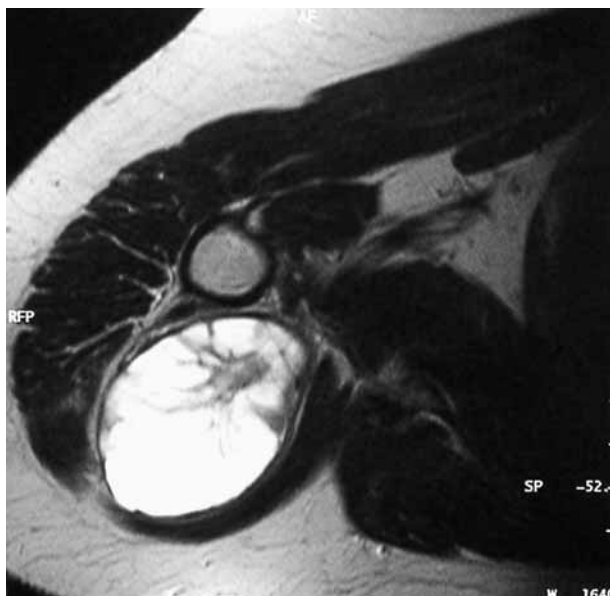

Fig. 2. — Magnetic resonance imaging (MRI) on axial view of the shoulder showing a 4 cm × 6 cm mass with high signal intensity on T2-weighted sequence.

Magnetic resonance imaging of the shoulder revealed a septated mass limited anteriorly by the infraspinatus, triceps and teres minor, and posteriorly by the deltoid muscle ; the mass demonstrated

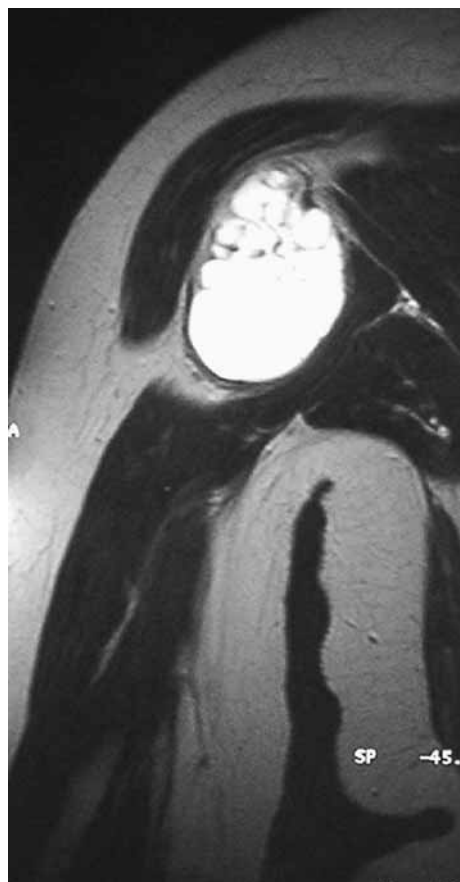


Fig. 3. — MRI aspect on frontal view

low signal intensity on T1-weighted, high signal intensity on T2-weighted and contrast-enhanced sequences (fig 2 & 3). The presumptive diagnosis at this point was with other carcinomas of soft tissue, lymphoma, synovial cyst, benign soft tissue tumour, and hydatid cyst. Biological investigations including hydatid serology were unremarkable.

A tru-cut biopsy of the mass was performed and showed tumour cells expressing the smooth muscle markers actin and desmin ; there was a focal expression of melanoma-specific antigen (HMB-45). The histological diagnosis was LAM (fig 4). Surgical resection was performed, using a direct posterior approach under general anaesthesia. The mass was found to be encapsulated and complete resection was achieved easily. High resolution CT of the thorax, performed subsequently, was free of abnormality, and there has been no local recurrence at three years follow-up.

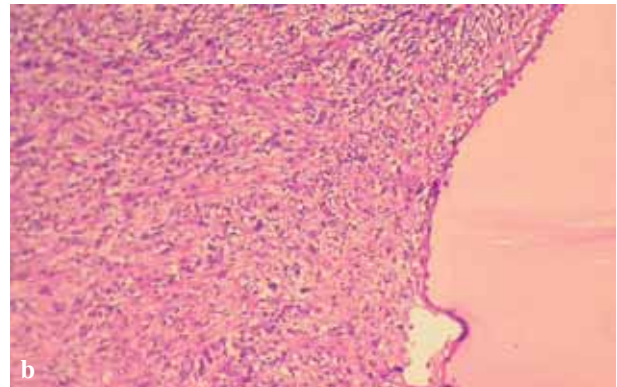
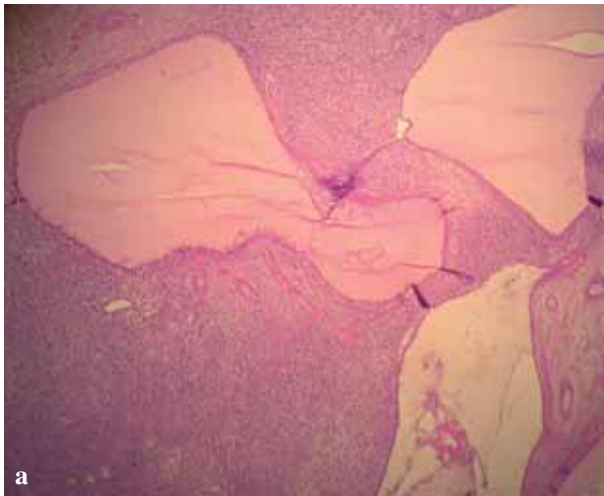

Fig. 4. — Histological aspects showing that LAM cells proliferate in fascicles, separated by narrow lymphatic channels. Note the presence of aggregates of lymphoid cells forming follicular centres : 4a) original magnification $\times 100$. 4b) original magnification $\times 200$.

DISCUSSION

Lymphangiomyomatosis (LAM) is a rare condition of hamartomatous nature that is seen exclusively in female patients usually during their reproductive years. It is characterised by proliferation of abnormal lymphatic smooth muscle cells. In Europe and the United States, the incidence is thought to be about 1 in 1 million individuals ; the worldwide incidence is estimated about 100 cases per year (7). The first report was done by von Stossel (10) in 1937 ; he described the lesion as “muscular cirrhosis of the lungs”. Cornog and Enterline (3) subsequently coined the term “lymphangiomyoma” according to their findings with electron microscopy in similar cases. It most commonly involves the pulmonary system and causes dyspnoea, chylous pleural effusions, pneumothorax, haemoptysis, and respiratory failure.

However, the condition has also been reported in the mediastinum, the retroperitoneum (2), and sporadically in the inguinal, supraclavicular lymph nodes (12) and ureter (4).

To date, the pathogenesis is still unrecognised, a hormonal factor has been considered as the disease only affects women of reproductive age and may be exacerbated by pregnancy or by administration of oestrogen, and some LAM cells express oestrogen and progesterone receptors (6). A genetic factor is

thought to be responsible in sporadic forms, related to mutation of one of the tuberous sclerosis complex genes (TSC2) on chromosome 16 (7,13). Histological study of LAM shows a proliferation of smooth muscle cells arranged in fascicular, trabecular, and papillary patterns associated with slit-like vascular channels. Immunohistochemically, LAM cells usually express a representative smooth muscle phenotype and are positive for HMB-45, a monoclonal melanoma-associated marker that reacts with a premelanosome-associated glycoprotein (7,11).

The size of extrapulmonary LAM lesions is widely dependent on the development of multiple cysts, as a consequence of obstruction to lymph flow. Various differential diagnoses are suggested. Absence of mitoses and the low MIB-1 proliferation index are not consistent with a diagnosis of leiomyosarcoma or metastatic sarcoma. Absence of involvement of lymph nodes at a distance from the lesion, as well as absence of pathologic vascularity on magnetic resonance angiography may help to rule out the possibility of a leiomyosarcoma or a metastatic sarcoma (5). Other differential diagnoses include angiomyolipoma which contains abnormal smooth muscle cells showing reactivity with HMB-45 antibody ; however, it is characterised by the presence of abundant adipose tissue and by a disorganised blood vessels pattern (1,8). Pulmonary

LAM is usually progressive and unresponsive to treatment despite a variety of treatment regimens including hormonal therapy, as well as to surgical management, with high mortality (5,9). To the best of our knowledge, localisation in the soft tissues at the shoulder has not been previously reported in medical literature.

REFERENCES

1. **Chan JK, Tsang WY, Pau MY, Tang MC, Pang SW, Fletcher CD.** Lymphangiomyomatosis and angiomyolipoma : closely related entities characterized by hamartomatous proliferation of HMB-45-positive smooth muscle. *Histopathology* 1993 ; 22 : 445-455.
2. **Chu SC, Horiba K, Usuki J et al.** Comprehensive evaluation of 35 patients with lymphangiomyomatosis (LAM). *Chest* 1999 ; 115 : 1041-1052.
3. **Cornog JL, Enterline HT.** Lymphangiomyoma, a benign lesion of chyloferous lymphatics synonymous with lymphangiopericytoma. *Cancer* 1966 ; 19 : 1909-1930.
4. **Gray SR, Carrington CB, Cornog JL.** Lymphangiomyomatosis : report of a case with ureteral involvement and chyluria. *Cancer* 1975 ; 35 : 490-498.
5. **Jaiswal VR, Baird J, Fleming J, Miller DS, Sharma S, Molberg K.** Localized retroperitoneal lymphangiomyomatosis mimicking malignancy. *Arch Pathol Lab Med* 2003 ; 127 : 879-882.
6. **Johnson SR, Tattersfield AE.** Clinical experience of lymphangiomyomatosis in the UK. *Thorax* 2000 ; 55 : 1052-1057.
7. **Johnson SR, Tattersfield AE.** Lymphangiomyomatosis. *Semin Respir Crit Care Med* 2002 ; 23 : 85-92.
8. **Matsui K, Tatsuguchi A, Valencia J et al.** Extra-pulmonary lymphangiomyomatosis (LAM) : Clinicopathologic features in 22 cases. *Hum Pathol* 2000 ; 31 : 1242-1248.
9. **Sullivan EJ.** Lymphangiomyomatosis : a review. *Chest* 1998 ; 114 : 1689-1703.
10. **von Stossel VE.** [About muscular cirrhosis of the lungs.] (German). *Beitr Klin Tbk* 1937 ; 90 : 432-442.
11. **Weiss S, Goldblum JR.** *Soft Tissue Tumors*. 4th ed. Mosby, St Louis, Mo. 2001 : pp. 973-981.
12. **Wolff M.** Lymphangiomyoma : clinicopathologic study and ultrastructural confirmation of its histogenesis. *Cancer* 1973 ; 31 : 988-1007.
13. **Yu J, Astrinidis A, Henske E.** Chromosome 16 loss of heterozygosity in tuberous sclerosis and sporadic lymphangiomyomatosis. *Am J Resp Crit Care Med* 2001 ; 164 : 1537-1540.