



## Mechanism of failure eleven years following a Buechel Pappas hip resurfacing

Ajay MALVIYA, Steven LOBAZ, James HOLLAND

*From Freeman Hospital, Newcastle upon Tyne, UK*

Hip resurfacing is gaining popularity as an acceptable treatment option for young active patients with hip osteoarthritis. The Buechel-Pappas hip resurfacing system has a titanium alloy femoral and acetabular component with a polyethylene liner. The titanium nitride coating of the femoral component has been shown to have a very low wear rate during in vivo laboratory studies. Although it has been on the marketplace since 1989, we could find no follow-up results in the literature. We report a rare case of Buechel-Pappas hip resurfacing which presented with catastrophic failure at 11 years follow-up. The polyethylene liner was worn through, and there was severe metallosis with extensive titanium debris. The head of the femur was however viable, suggesting that the failure of the procedure was due to the bearing surface.

**Keywords :** titanium ; hip resurfacing ; failure.

UHMWPE wear and eliminate metallic wear debris.

We present a case of the the so-called "New Jersey" hip designed by Buechel and Pappas, which presented with catastrophic failure at 11 years follow-up.

### CASE REPORT

A 45-year-old lady with rheumatoid arthritis involving several joints underwent a Buechel Pappas hip resurfacing in 1995. She did well following her surgery, but developed some pain in the hip at about 9 years after a fall when she was suspected to have sustained a fracture of the tip of the greater trochanter. Conservative management was adopted but the hip pain progressed over the next year when features suggestive of florid heterotopic

### INTRODUCTION

The Buechel-Pappas resurfacing system was introduced in 1989 as a cementless resurfacing system with a modular acetabular component and a titanium nitride coated femoral component (2). However, there have been no reports in the literature of its design and few of its implantation. The resurfacing has an ultra high molecular weight polyethylene (UHMWPE) bearing insert with a titanium alloy femoral and acetabular component. The titanium nitride coating is said to reduce

■ Ajay Malviya, MRCS Ed, Specialist Registrar Orthopaedics.

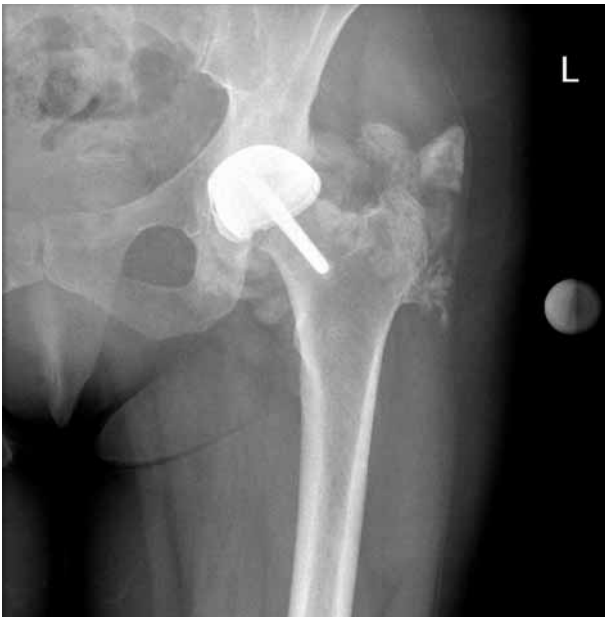■ Steve Lobaz, MBBS, Foundation Year 1 Doctor Orthopaedics.

■ James Holland, FRCS Orth, Consultant Orthopaedic Surgeon.

*Department of Orthopaedic Surgery, Freeman Hospital, Newcastle upon Tyne, United Kingdom.*

Correspondence : A. Malviya, 81 Daylesford Drive, Gosforth, Newcastle upon Tyne, NE3 1TW, United Kingdom.  
E mail : malviya7@aol.com

© 2007, Acta Orthopædica Belgica.



*Fig. 1.* — Radiograph at presentation suggesting heterotopic bone formation with concern about a neoplastic process.

ossification and calcification were noted on radiographs. This was investigated further by MRI scan which revealed a well-defined large soft tissue mass around the lateral and posterior aspects of the femoral neck. A biopsy of the mass was undertaken to exclude a neoplastic lesion. This revealed the presence of wear debris and excluded an infective or neoplastic process. Further radiographs showed a collapse and obvious wear of the prosthesis with further progression of radiological appearance of presumed heterotopic ossification (fig 1). A decision was made to revise the left hip to a total hip replacement.

During surgery extensive black pigmentation of the tissues around the hip was noted, with lumps of soft tissue mass in the areas of suspected heterotopic ossification. The polyethylene liner had worn through and the head had eroded into the acetabular metal shell (fig 2). The titanium nitride coating of the head was burnished. The femoral component was knocked free of the femoral head revealing intact bleeding femoral head cancellous bone beneath. The acetabular polyethylene remnant was loose and lifted free. The acetabular metal shell was fully osseointegrated and worn through to

bone in the dome of the acetabulum. Notable was complete absence of osteolysis. A hybrid hip replacement with an uncemented acetabular component and a cemented stem was successfully performed.

Following resection, the head was analysed histologically. The head and neck of the femur were viable throughout with evidence of vascularity and osteocyte nuclei within the bone (fig 3).

On histological analysis, the specimen of soft tissue lumps revealed features suggestive of tissue response to wear, containing titanium and polyethylene debris with no evidence of heterotopic ossification (fig 4). The specimen from the bone revealed further tissue reaction to wear debris.

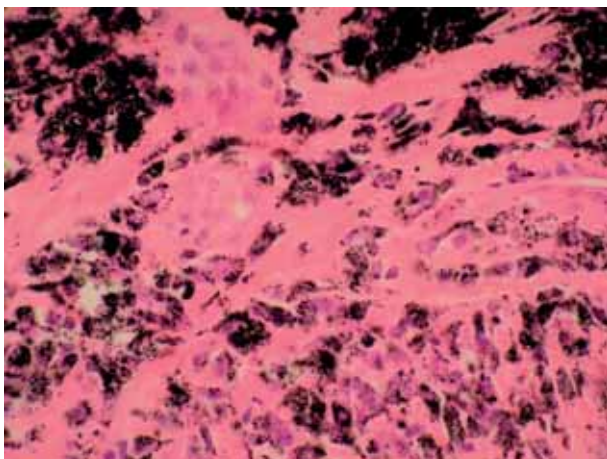
## DISCUSSION

The early results of hip resurfacing in the 1970s and 1980s were poor and the procedure was largely abandoned by the mid-1980s (8). The expectation that these prostheses would be easy to revise was not often fulfilled. The large diameter of the articulation combined with thin polyethylene cups or liners resulted in accelerated wear and the production of large volumes of biologically active particulate debris, leading to bone loss and implant loosening (8). The failure of early hip resurfacings was essentially a consequence of the use of inappropriate materials, poor implant design, inadequate instrumentation, and crude surgical technique (8). It was not an inherent problem with the procedure itself.

Studies on wear particles (9) around failed hip replacement show that the tissues around metal-on-metal prostheses contained large numbers of metal particles and large numbers of macrophages, and occasional multinucleated giant cells. The tissues around metal-on-polyethylene prostheses often contained large numbers of small and large polyethylene particles, variable numbers of cement particles, and occasional metal particles. Large numbers of macrophages and multinucleated giant cells were frequently seen in these tissues. It is believed that in the failure of metal on polyethylene prostheses the role played by production of metal particles is less than that by polyethylene particles



**Fig. 2.** — The explanted prosthesis showing the worn metal backing with the polyethylene liner and the titanium nitride coated femoral component.

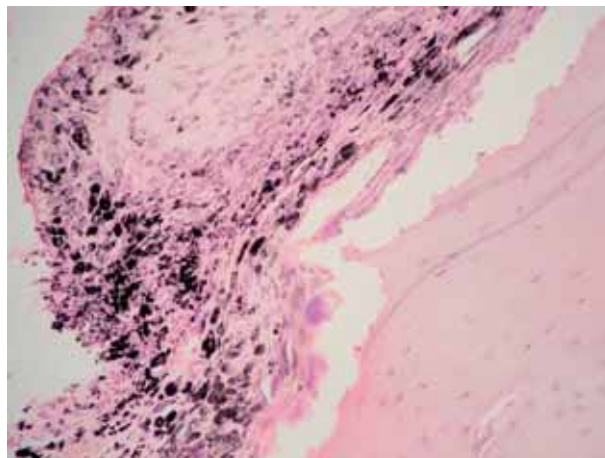


**Fig. 3.** — Histology of the head of the femur showing viable bone with osteocytes.

unless the polyethylene component is worn through and the two metal surfaces rub against each other (5).

The intense mono- and multinucleated histiocytic reaction to polyethylene wear debris in metal on polyethylene hip replacements has been proposed to be one of the main causes of osteolysis in short and long term failures (6).

Whilst no published reports of the definitive Buechel Pappas resurfacing were found on a



**Fig. 4.** — Histology of soft tissue showing inflammatory response to metal and polyethylene debris.

routine Pubmed search, poor outcome and osteolysis associated with this implant has been presented (11). There is, however, a report of a resurfacing of similar design using cobalt chrome instead of titanium. The socket was fixed by bone ingrowth into the porous coating, supplemented with bone screws (3). Large osteolytic regions were observed in the pelvis at short (24-60 months) follow-up times. These were particularly concentrated around the fixation screws. The screws and screw holes may have provided wear debris with easy access to the trabecular spaces in the pelvis, thus causing the lesions. However, the only apparent modification made to the final resurfacing was to change the material to titanium and to coat the femoral component with titanium nitride for lower wear, and the removal of fixation screws.

The Buechel-Pappas hip resurfacing metal implants are all coated with titanium nitride (TiN) which is claimed to reduce the wear rate on UHMWPE to 2% of that found in similar tests with 32-mm cobalt chrome femoral heads. The titanium nitride-polyethylene couple was believed to have a great potential as a lifetime bearing combination (10).

The acetabular component is a 2 mm thick spherical metal fixation cup with 1 mm thickness of porous coating. The polyethylene bearing insert has a 4 mm thickness. The total acetabular cup thickness is therefore 7 mm (7).

This case, however, outlines the problems with thin polythene liners and titanium bearing surfaces. After wearing out the liner, the titanium articulating surface produced large amount of metal debris which mimicked heterotopic ossification. The titanium debris with its black pigmentation causes staining of all the surrounding tissue with obvious soft tissue reaction. Although the prosthesis lasted more than ten years the failure was catastrophic and this would be a good enough indication to avoid such bearing surface. It has been shown in the past that a femoral component that is made of titanium alloy can undergo severe wear of the surface with liberation of potentially toxic local concentrations of metal debris into the surrounding tissues and may contribute to infection and loosening (1).

Interestingly, the femoral head and neck which were retrieved from the prosthesis were viable. Previous studies have confirmed that femoral heads remain viable for up to 12 years following resurfacing arthroplasty (4). There was also no evidence of osteolysis that is normally associated with such polyethylene wear. Additionally there did not appear to be any problem with prosthetic fixation to bone, which was sound at 11 years. This reinforces optimism for the future of hip resurfacing. Viable bone should be able to support the prosthesis for an indefinite period. By the use of appropriate bearing material and good implant design hip resurfacing has a potential to last.

## REFERENCES

1. **Agins HJ, Alcock NW, Bansal M et al.** Metallic wear in failed titanium alloy total hip replacements. *J Bone Joint Surg* 1998 ; 70-A : 347-56.
2. **Buechel FF.** Resurfacing total hip replacement for avascular necrosis in young patients : durability, revision options and future technology. *6th Annual Current Concepts in Joint Replacement Symposium*. Orlando, Florida, 1990.
3. **Buechel FF, Drucker D, Jasty M, Jiranek W, Harris WH.** Osteolysis around uncemented acetabular components of cobalt chrome surface replacement hip arthroplasty. *Clin Orthop* 1994 ; 298 : 202-11.
4. **Campbell P, Mirra J, Amstutz HC.** Viability of femoral heads treated with resurfacing arthroplasty. *J Arthroplasty* 2000 ; 15-1 : 120-122.
5. **Doorn PF, Campbell PA, Amstutz HC.** Metal versus polyethylene wear particles in total hip replacements. *Clin Orthop* 1996 ; 329S : S206-S16.
6. **Doorn PF, Mirra JM, Campbell PA, Amstutz HC.** Tissue reaction to metal on metal total hip prostheses. *Clin Orthop* 1996 ; 329S : S187-S205.
7. **Endotech data sheet.** B-005. Rev. A Date 8/17/01. 2001.
8. **Grigoris P, Roberts P, Panousis K, Bosch H.** The evolution of hip resurfacing arthroplasty. *Orthop Clin North Am* 2005 ; 36 : 125-134.
9. **Howie DW.** Tissue response in relation to type of wear particles around failed hip arthroplasties. *J Arthroplasty* 1990 ; 5-4 : 337-348.
10. **Pappas MJ, Makris G, Buechel FF.** Titanium nitride ceramic film against polyethylene. A 48 million cycle wear test. *Clin Orthop* 1995 ; 317 : 64-70.
11. **Prasad PSV, Takahashi T, Steele N, Richardson JB.** A comparative study of bone conserving hip replacements : the thrust plate and the Buechel Pappas resurfacing prosthesis. Presented at the EFORT meeting, Helsinki, June 2003. *J Bone Joint Surg* 2004 ; 86-B suppl III : 279.