



Cementless modular hip arthroplasty as a salvage operation for failed internal fixation of trochanteric fractures in elderly patients

Jean-Michel LAFFOSSE, François MOLINIER, Jean-Louis TRICOIRE, Nicolas BONNEVIALLE, Philippe CHIRON, Jean PUGET

From Service de Chirurgie Orthopédique et de Traumatologie, CHU Rangueil et CHU Purpan, Toulouse, France

Failure of internal fixation of trochanteric fractures requires repeat surgery in order to avoid the risks of complications affecting bedridden patients. This study was conducted to assess the results of hemi- or total hip arthroplasty with a cementless modular femoral stem, as a salvage operation following early mechanical failure of internal fixation.

Twenty nine patients with a mean age of 81.1 years (70-91) were included in the study. Fractures extending into the diaphysis and pathological fractures were excluded, as well as patients who presented late complications. A cementless modular stem designed for metaphyso-diaphyseal anchorage was used in all cases. Twenty-two patients underwent hemiarthroplasty and seven total hip arthroplasty.

Four patients died within one year and two were lost to follow-up. The remaining 23 patients were followed for a mean of 20 months (range : 6-89). At the time of last follow-up, 20 were ambulatory with (11 cases) or without support (9 cases) and three were bedridden. There were no intra- or postoperative femoral fractures. Two patients presented an early dislocation after bipolar hemiarthroplasty. One was successfully treated by closed reduction ; the other underwent revision with a dual mobility acetabular component because of recurrent dislocation. All the patients reported significant pain relief and functional improvement. Subsidence of the stem greater than 5 mm was noted in three cases, without clinical consequences.

The cementless modular femoral stem used in this study appeared as a reliable implant. Primary arthroplasty with such an implant could be considered in selected cases such as markedly unstable fractures and in osteoporotic elderly patients.

Keywords : trochanteric fracture ; elderly ; failure ; hip arthroplasty ; cementless ; modularity.

INTRODUCTION

Trochanteric hip fractures in elderly patients have benefited from advances in internal fixation. Ambulation with full weight bearing can be resumed earlier, thus diminishing the morbidity related with this type of fracture (3). Early failure of

- Jean-Michel Laffosse, MD, Orthopaedic resident.
- François Molinier, MD, Resident.
- Jean-Louis Tricoire, MD, Orthopaedic surgeon.
- Philippe Chiron, MD, Professor.
- Jean Puget, MD, Professor.

Service de Chirurgie Orthopédique et de Traumatologie, CHU Rangueil, 1 avenue Jean Poulhès, TSA 50032, 31059 Toulouse Cedex 9, France.

- Nicolas Bonneville, MD, Resident.

Service de Chirurgie Orthopédique et de Traumatologie, CHU Purpan, Place du Docteur Baylac TSA 40031, 31059 Toulouse Cedex 9, France.

Correspondence : Jean-Michel Laffosse, Service de Chirurgie Orthopédique et de Traumatologie, CHU Rangueil, 1 avenue Jean Poulhès, TSA 50032, 31059 Toulouse Cedex 9, France. E-mail : jean-michel.laffosse@wanadoo.fr

© 2007, Acta Orthopædica Belgica.

internal fixation occurs however in a number of cases (2,8,33,36). The causes are multiple and sometimes predictable (16,19,24). Failure may be due to a technical error (improper position of the cervical screw or insufficient reduction) or to a poor indication with an implant ill-adapted to the treatment of a potentially unstable or comminuted fracture (2,16,18). Rigidity of the implant combined with poor bone quality will encourage failure of fixation. Breakage of implants themselves is very rare (1,8).

Failure of internal fixations results in pain and functional disability (14,20,35), which may result in complications related with prolonged recumbency and may affect the vital prognosis of these fragile patients. Treatment options are multiple. For young patients with excellent general condition and good bone quality, repeat internal fixation is advocated (1,13,19,30,32,38). Some authors recommend lateral displacement of the proximal femur (13,30,32,38) and/or medial displacement of the distal femur (6,32). Autograft or allograft bone (13) or cement supplementation (38) have also been advocated. The clinical and radiological results seem to be satisfactory (1,13,30,32,38) but the reported series are small and the follow-up is limited. However such osteotomies alter the morphology of the proximal femur (32) and will cause difficulties in case of subsequent arthroplasty, while also delaying weight-bearing (38). In an elderly and fragile population (12,14), the aim of treatment is early weight-bearing and such conservative treatments are not suitable. A Girdlestone procedure can be considered for patients with very limited functional demands but the results are often poor (34). In most cases, for older people, the procedure of choice is hip replacement (12,14,20,29,30, 35,39) which generally provides good results.

The purpose of our retrospective study was to assess the outcomes achieved with a cementless, modular implant with metaphyseal-diaphyseal anchorage to salvage early mechanical failure of internal fixation of fractures of the proximal femur in elderly patients. We studied the early clinical and radiographic results as well as the complications.

MATERIAL AND METHODS

Material

We included all failures of internal fixations performed in our department for low-energy trochanteric hip fractures (AO/ASIF group 31, including pertrochanteric type : A1 or A2 and intertrochanteric type : A3) in patients over 70 years of age. True cervical fractures, trochanteric-diaphyseal fractures, high-energy fractures in young subjects and pathological fractures were excluded from the study. We also excluded late complications such as malunion of the proximal femur, post-traumatic avascular necrosis of the femoral head, or hardware disassembly following repetitive falls, as well as septic complications.

The study group included 29 patients (23 female and 6 male) treated between 1983 and 2005. The mean age was 81.1 years (70-91) at the time of revision. Average ASA score was 2.4, with 1 patient classified ASA 1, 17 classified ASA 2 and 11 classified ASA 3. In the majority of cases (24/29), revision was early, within the first 3 months after primary surgery. Preoperative data (fracture type, initial implant, time interval from fracture and mode of failure) are reported in table I. An example of implant failure is illustrated in fig 1a & 1b.

Table I. — Preoperative data

	Number of cases
AO Type :	
– A1.1 / A1.2 / A1.3	– 4 / 5 / 1
– A2.1 / A2.2 / A2.3	– 7 / 2 / 5
– A3.1 / A3.2 / A3.3	– 0 / 1 / 4
Type of implant :	
– Ender nailing	– 1
– Judet plating	– 4
– DHS TM	– 17
– Gamma nail TM	– 5
– Long Gamma nail TM	– 1
– PCCP	– 1
Interval from the fracture (<i>days</i>) :	
– mean (min - max)	– 60.3 (0 - 156)
– median	– 61
– < 90 days	– 24
– 90 to 180 days	– 5
Mode of failure :	
– Cut-out	– 21
– Disassembly	– 8
– Implant breakage	– 0

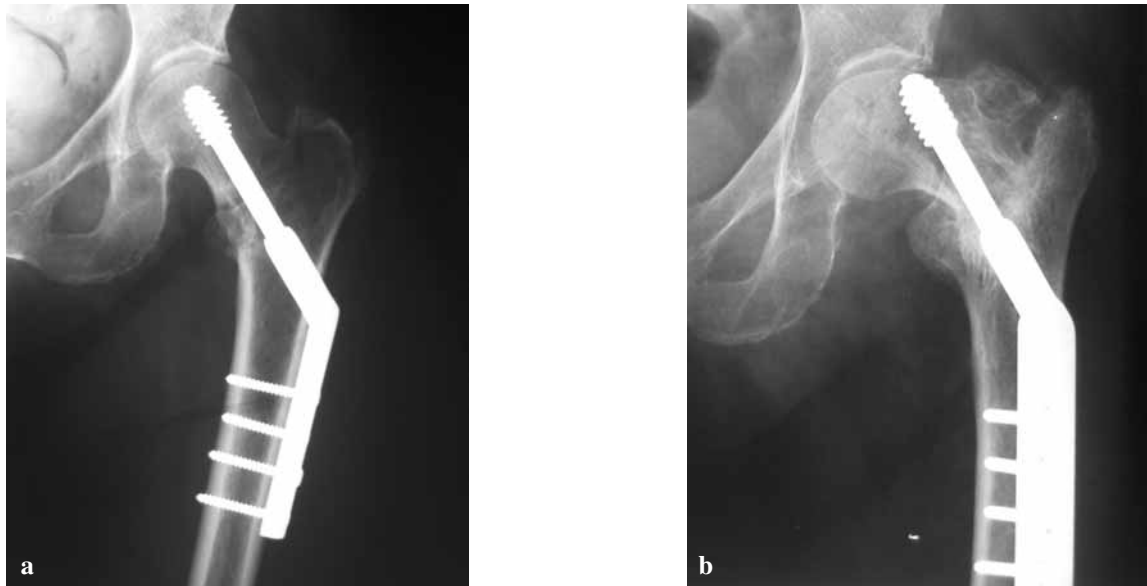


Fig. 1. — Internal fixation of a trochanteric fracture with a DHS™-type implant. a : Immediate postoperative radiograph showing good centering of the neck screw ; b : Cut-out at 3 weeks.

Implant description

All patients received the same femoral implant. The Puget prosthesis (Système PP™, Tornier, Monbonnot, France) consists of three parts : the stem, the baseplate and the head (fig 2). The stem has a quadrangular section and a sagittal curve approximating the anatomical curve of the femur. This allows for metaphyseal support and good primary stability, thus avoiding the use of cement. The stem is topped by a metaphyseal part or baseplate. The connection between the stem and baseplate is by a Morse taper and a longitudinal screw. The baseplate comes in several different heights, which allows for adjustment of limb length and muscle tension. Anteversion of the femoral neck can be adjusted to optimise the stability of the prosthetic hip. A system of perforations allows for reconstruction of the greater trochanter using tension bands and cerclage wires. Another Morse taper connects the baseplate and the head ; the latter comes in various diameters and neck lengths. This implant can be used in bipolar arthroplasty, as well as in standard or dual mobility total hip arthroplasty.

Operative technique

The patient was placed in a lateral decubitus position. A posterolateral approach was made after prophylactic antibiotic treatment had been given. The internal fixa-




Fig. 2. — The PP™ system. The cementless stem has a quadrangular section and is curved (black arrow), with a modular base-plate (white arrow) fixed to the stem with a Morse taper and a longitudinal screw. A Morse taper also connects the baseplate to the head.

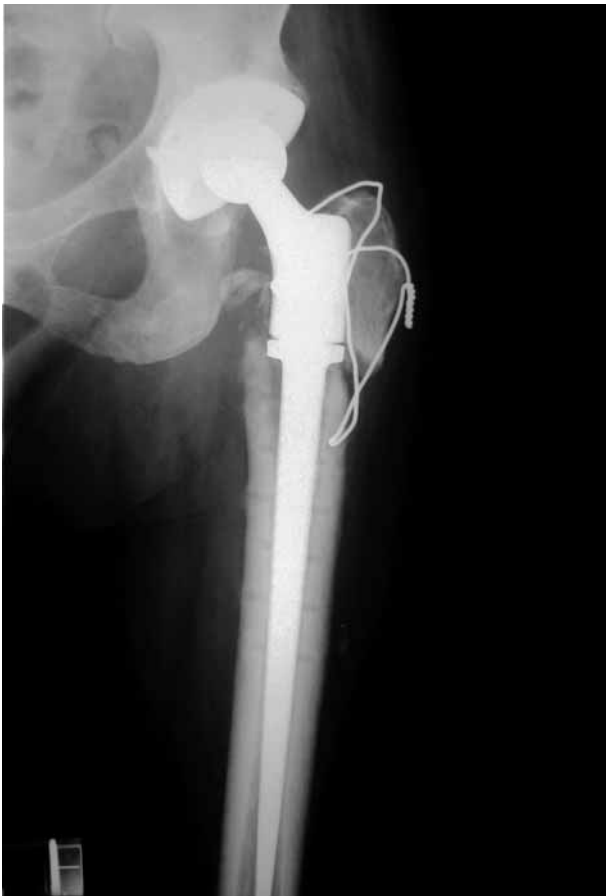

Fig. 3. — Revision with total hip arthroplasty

tion hardware was removed. Multiple tissue specimens were taken for bacteriological testing. The trochanteric fracture line was opened, a digastric osteomuscular flap was created, preserving the continuity between the abductor muscle (gluteus medius and minimus) and the vastus lateralis. The short external rotator muscles were divided, the digastric flap was retracted anteriorly, and the femoral head was removed after posterior capsulotomy. A horizontal saw cut was made above or below the lesser trochanter, depending on the location of the fracture line and comminution, so as to find a solid bearing zone in the posterior medial cortex. The femoral shaft was prepared using quadrangular rasps. The collar of the final femoral stem was made to rest against the horizontal cut line (fig 3). The long stem enabled the screw holes to be bridged after implant removal (fig 3). Full circumferential support is not necessary because the stability of the stem is primarily ensured by the metaphyseal-diaphyseal press-fit of the quadrangular stem. In

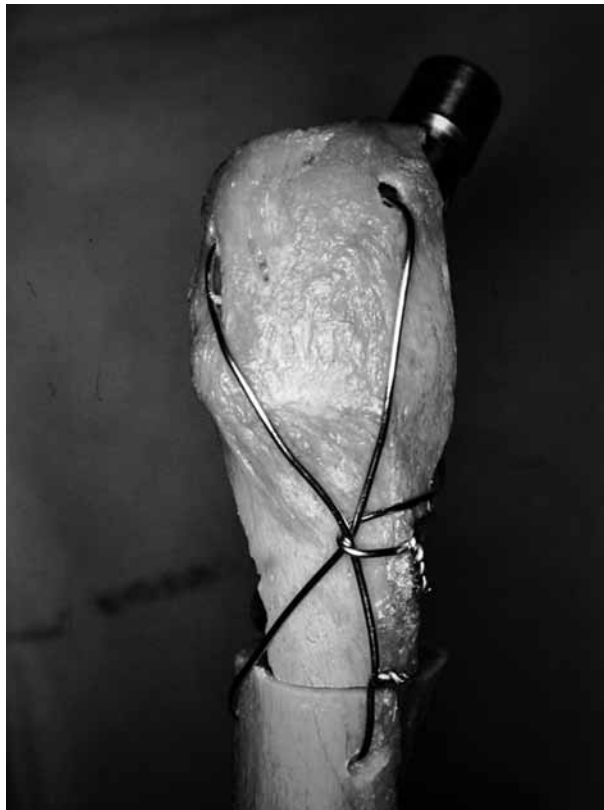

Fig. 4. — A tension band-wire with one or two cerclage wires reconstructs the greater trochanter and fixes the digastric flap between gluteus medius and vastus lateralis to prevent its anterior displacement.

case of acetabular cartilage damage or pre-existing osteoarthritis, an acetabular implant was inserted. The acetabulum was prepared in a standard fashion, followed by insertion of a standard or dual mobility cup. The length of the lower limbs and the offset were adjusted with the choice of baseplate and head. The greater trochanter was then reconstructed using an elastic system of cerclage wires passed transosseously in the metaphyseal region so as to also distalise the greater trochanter; in addition, one or two wire cerclages were passed through the holes in the baseplate to prevent its anterior migration (fig 4). This careful reconstruction provided good tension for the abductor musculature. Short external rotators were reinserted transosseously and the wound was closed.

Operative data

Twenty-three patients out of 29 were operated under general anaesthesia. The duration of the procedure was

109 min (65-180) on average. We carried out bipolar arthroplasty in 22 cases and total hip replacement in 7 cases (with a dual-mobility acetabular implant in 4 cases, a standard cemented polyethylene cup in 2 cases, and a cementless cup in 1 case). The duration of the procedure was not significantly increased by insertion of an acetabular component (105 min (65-150) versus 112 (65-180)). Implant removal did not pose any particular problem except in one case in which removal of the broken distal screw of a Gamma nail required femorotomy (the total duration of the procedure was 180 min). Bacteriological examination was negative in all cases except one where *Enterobacter faecalis* was found in several samples, warranting intravenous antibiotic treatment.

Postoperatively, patients were not allowed to sit in a chair before they were ambulatory. In the sitting position, considerable traction is indeed exerted on the greater trochanter, which may displace anteriorly. If possible, the patient should start walking with a walker on the second day, with full weightbearing if tolerated. Thromboembolism prophylaxis was with low-molecular-weight heparin. In all cases but one, the patient was discharged either to a rehabilitation centre or to an intermediate or extended care centre.

Perioperative blood loss was evaluated by calculating total blood loss using an established standardized method (4) taking into account the drop in haematocrit values between the day before operation and the fifth postoperative day and the number of red blood cells units transfused during the same period. Total calculated blood loss was 890 ml (270-2010) on average.

RESULTS

Early postoperative data

General complications. Two patients (both 90 year-old females with an ASA score of 3) died during hospitalization on the 1st and 15th postoperative day respectively with cardiac failure and respiratory complications. We noted 3 cases of bed sores, 4 cases of deep vein thrombosis without further complications, 4 cases of urinary tract infection and one case of ischaemic myocardial infarction.

Local complications. There were no deep infections and no perioperative or postoperative femoral fractures. After discharge, two patients with hip hemiarthroplasty presented a postoperative disloca-

tion (after 1 month and 3 months respectively). One was successfully treated by closed reduction ; the other presented recurrent dislocation and underwent successful revision with a dual mobility acetabular component.

Clinical results

The average duration of hospitalization was 18.6 days (6-63). Of the 29 patients, two died during hospitalization. Two other patients died shortly after discharge : one due to recurrent myocardial infarction and the other due to stroke. Two patients were lost to follow-up because they could not be transported owing to major deterioration of their general condition or cognitive functions. Twenty-three patients were evaluated over 20 months (6-89) on average : 6 patients ambulated independently with no support, 6 required a cane, 8 required two canes or a walker, and 3 patients had very limited autonomy and were bedridden. None of them complained of pain, whereas all had severe and incapacitating pain prior to revision.

Radiographic results

Results were satisfactory. Stem subsidence greater than 5 mm was noted in three cases but this did not interfere with ambulation or rehabilitation. Two patients presented non-union of the greater trochanter ; this was associated with pain in one patient, who required surgery to achieve bone healing. One bedridden patient presented Brooker type IV heterotopic ossifications.

DISCUSSION

Our study is one of the largest in the literature on this specific subject (12,14,20,30,35,39). Contrary to other series, the same implant was used in all cases, and all these were early failures of internal fixation. Other series (20,39) have also included late mechanical failures (periprosthetic fracture following trauma, fatigue fracture of implant) as well as septic complications or cases of avascular necrosis of the femoral head. The technical problems are not comparable (20). Data from other studies are presented

Table II. — Results of the literature

Serie	Number of cases	Age (years)*	Interval before revision (months)*	Follow-up (months)*	Good clinical results	Unipolar (disl) / Bipolar (disl) / THR (disl)	Long stem / standard stem
Haidukewych and Berry (2003)	60	78 (44 – 96)	–	65 (25 – 185)	39/44	1 (0) / 27 (?) / 32 (?)	30/30
Hernigou et al (2006)	20	79 (62 – 87)	–	88 (48 – 168)		0 / 20 (3)	4/16
Zhang et al (2004)	19	64.1 (21 – 87)	40.3 (2 – 288)	88 (24 – 216)	12/15	3 (0) / 16 (3)	0 / 19
Mehlhoff et al (1991)	13	65	10	34	5/13	0 / 13 (3)	–
Stoffelen et al (1994)	12	79 (61 – 94)	6 (5– 19)	32 (4– 84)	8 / 11	0 / 8 (1) / 4 (0)	12 / 0
Said et al (2006)	8	67 (68 – 84)	8 (5 – 12)		6/8	0 / 5 (0) / 3 (0)	–

Abbreviation : THR = Total Hip Replacement, disl = dislocation

* The values are given as the mean and the standard deviation with minimum and maximum

in table II. Our follow-up is short, but appears sufficient to analyze the results in this population with important comorbidities. Pitto (27) demonstrated that excess mortality in these patients essentially occurs in the first six months and that beyond this period, life expectancy is comparable with patients of similar age and gender.

Even though the clinical results are satisfying with pain relief and early resumption of ambulation, hip arthroplasty following failed internal fixation of a trochanteric hip fracture remains a technical challenge (12,20,30,35,39). Structural defects and modification of bony landmarks due to deformations and displacement of fragments (12,20,39), combined with poor bone quality, loss of bone stock and presence of holes after removal of internal fixation hardware (15) all encourage intraoperative mechanical complications (fractures and cortex perforations) (14,20). Several different implants have been used in many other studies (12,14,20,30,35,39). Absence of calcar support makes it difficult to implant a standard stem (12,20). Along with Stoffelen *et al* (35), as well as Hesse and Gächter (15), we used a long stem (175 mm) with metaphyso-diaphyseal anchorage. Zhang *et al* (39) implanted standard stems in all their procedures, but half of these were for post-traumatic

osteonecrosis of the femoral head. Hernigou *et al* (14) also favoured a standard cemented stem, whereas Haidukewych and Berry (12) only used one in 9 of their 60 patients. Some authors suggest using a long cemented stem (15) or a long cementless stems to bypass the cortical defect and/or screw-holes left at the site of the failed fixation (12,23). A cementless implant exposes to a risk of perioperative fracture, but the risk appears acceptable compared to the use of standard stems without a reliable calcar support. Because the holes could act as stress-risers predisposing to intra-operative fracture (12), some authors advise using cemented stems (14,15) to prevent this complication. The screw holes prevent intrafemoral pressurisation of cement (39), but authors using cemented stems did not report significant rates of loosening (12,14,20,39). Various techniques have been suggested to pressurise the cement in the medullary canal (23,39) but they may encourage fat embolism (7,22). This has been reported in elderly patients with a previous history of cardiovascular or respiratory disorders (7), but osteoporosis and the use of a long femoral stem (22) may also act as predisposing factors. Some studies (26) have shown that the risk of fat embolism is reduced with cementless stem implants. Reconstruction of the

trochanteric crest is particularly problematic. Comminution, poor bone quality, poor reduction or fixation complicate reconstruction and may result in non-union which itself promotes pain, limping (12,39) as well as dislocation (14,20,39). With the technique used in this study, an osteomuscular flap was created which incorporated part of the greater trochanter. This reduces the risk of perioperative fracture, improves femoral exposure and allows for better adjustment of muscle tension. Fixation of the intertrochanteric crest was then performed with tension bands and cerclage wires. This will reduce limping, malunion and dislocations. The use of bipolar hemiarthroplasty appears to be less invasive and provides better stability (5,10,12,20,39) in patients with multiple comorbidities and low functional demand. However, in cases with acetabular cartilage damage or pre-existing osteoarthritis, total hip arthroplasty is indicated, and a constrained or dual mobility acetabular implant is preferable because it will ensure excellent stability (14) and reduce the risk of postoperative dislocation (28,31) in those patients who often present neurological disorders or muscular insufficiency (20).

Vidal *et al* (37) and Lord *et al* (17) were the first to propose primary arthroplasty to treat trochanteric hip fractures at the end of the 1970's. The indications for arthroplasty were frequent (31), close to 25% for Puget *et al* (29), but this was largely due to deficiencies of the implants available for internal fixation at that time, such as Judet's plate-screw or Ender nails (17). Despite advances in internal fixation which have now lowered this percentage, fixation of unstable, comminuted or subtrochanteric fractures in elderly and osteoporotic patients still carries a high risk of failure (2,8,18,33,36). In such cases, primary arthroplasty appears as the best treatment (5,9-11,29) as it will allow for immediate ambulation. The comparative study done by Haentjens *et al* (9) showed less bedsores and pulmonary complications in patients treated with arthroplasty. Dobbs *et al* (7) found however that patients treated with arthroplasty were more at risk for intraoperative complications. To date, no study with a high level of evidence has shown the superiority of one type of treatment over the other in terms of functional results or of mortality (7).

REFERENCES

1. Alvarez DB, Aparicio JP, Fernandez EL, Mugica IG, Batalla DN, Jimenez JP. Implant breakage, a rare complication with the Gamma nail. A review of 843 fractures of the proximal femur treated with a Gamma nail. *Acta Orthop Belg* 2004 ; 70 : 435-443.
2. Audige L, Hanson B, Swiontkowski MF. Implant-related complications in the treatment of unstable intertrochanteric fractures : meta-analysis of dynamic screw-plate versus dynamic screw-intramedullary nail devices. *Int Orthop* 2003 ; 27 : 197-203.
3. Bonneville P, Féron JM. [Symposium SOFCOT. Fractures in elderly after 80 year-old.] (French). *Rev Chir Orthop* 2003 ; 89 (Suppl II) : 2S129 - 2S182.
4. Brecher ME, Monk T, Goodnough LT. A standardized method for calculating blood loss. *Transfusion* 1997 ; 37 : 1070-1074.
5. Chan KC, Gill G. Cemented hemiarthroplasties for elderly patients with intertrochanteric fractures. *Clin Orthop* 2000 ; 371 : 206-215.
6. Dimon J, Hughston J. Unstable intertrochanteric fractures of the hip. *J Bone Joint Surg* 1967 ; 49-A : 440-450.
7. Dobbs R, Parvizi J, Lewallen DG. Perioperative morbidity and 30-day mortality after intertrochanteric hip fractures treated by internal fixation or arthroplasty. *J Arthroplasty* 2005 ; 20 : 963-966.
8. Docquier P, Manche E, Autrique J, Geulette B. Complications associated with Gamma nailing. A review of 439 cases. *Acta Orthop Belg* 2002 ; 68 : 251-257.
9. Haentjens P, Casteleyn P, De Boeck H, Handelberg F, Opdecam P. Treatment of unstable intertrochanteric and subtrochanteric fractures in elderly patients. Primary bipolar arthroplasty compared with internal fixation. *J Bone Joint Surg* 1989 ; 71-A : 1214-1225.
10. Haentjens P, Casteleyn PP, Opdecam P. Primary bipolar arthroplasty or total hip arthroplasty for the treatment of unstable intertrochanteric and subtrochanteric fractures in elderly patients. *Acta Orthop Belg* 1994 ; 60 Suppl I : 124-128.
11. Haentjens P, Lamraski G. Endoprosthetic replacement of unstable, comminuted intertrochanteric fracture of the femur in the elderly, osteoporotic patient : a review. *Disabil Rehabil* 2005 ; 27 : 1167-1180.
12. Haidukewych GJ, Berry DJ. Hip arthroplasty for salvage of failed treatment of intertrochanteric hip fractures. *J Bone Joint Surg* 2003 ; 85-A : 899-904.
13. Haidukewych GJ, Berry DJ. Salvage of failed internal fixation of intertrochanteric hip fractures. *Clin Orthop* 2003 ; 412 : 184-8.
14. Hernigou P, Poignard A, Mathieu G, Cohen G, Manicom O, Filippini P. [Total hip arthroplasty after failure of per- and subtrochanteric fracture fixation in elderly subjects.] (French). *Rev Chir Orthop* 2006 ; 92 : 310-315.

15. Hesse B, Gachter A. Complications following the treatment of trochanteric fractures with the gamma nail. *Arch Orthop Trauma Surg* 2004 ; 124 : 692-8.
16. Im GI, Shin YW, Song YJ. Potentially unstable intertrochanteric fractures. *J Orthop Trauma* 2005 ; 19 : 5-9.
17. Lord G, Marotte J, Blanchard J, Guillaumon J, Hannoun L. [Role of neck-head arthroplasty in the treatment of per-trochanteric fractures after the age of 70. A propos de 140 cases.] (French). *Rev Chir Orthop* 1977 ; 63 : 135-148.
18. Madsen JE, Naess L, Aune AK, Alho A, Ekeland A, Stromsoe K. Dynamic hip screw with trochanteric stabilizing plate in the treatment of unstable proximal femoral fractures : a comparative study with the Gamma nail and compression hip screw. *J Orthop Trauma* 1998 ; 12 : 241-248.
19. Maury P, Putzeys P. Complications des fractures trochantériennes et sous-trochantériennes. In : *Fractures trochantériennes et sous-trochantériennes*. Cahiers d'Enseignement de la SOFCOT N°69, Ph. Vichard (ed), Expansion Scientifique Publications, Paris, 1999, pp 168-182.
20. Mehlhoff T, Landon GC, Tullos HS. Total hip arthroplasty following failed internal fixation of hip fractures. *Clin Orthop* 1991 ; 269 : 32-7.
21. Parker MJ, Pryor GA. Gamma versus DHS nailing for extracapsular femoral fractures. Meta-analysis of ten randomised trials. *Int Orthop* 1996 ; 20 : 163-168.
22. Patterson B, Healey J, Cornell C, Sharrock N. Cardiac arrest during hip arthroplasty with a cemented long-stem component. A report of seven cases. *J Bone Joint Surg* 1991 ; 73-A : 271-277.
23. Patterson B, Salvati E, Huo M. Total hip arthroplasty for complications of intertrochanteric fracture. A technical note. *J Bone Joint Surg* 1990 ; 72-A : 776-777.
24. Pervez H, Parker MJ, Vowler S. Prediction of fixation failure after sliding hip screw fixation. *Injury* 2004 ; 35 : 994-8.
25. Piriou P, Judet T. Traitement par arthroplastie d'emblée des fractures pertrochantériennes. In : *Fractures trochantériennes et sous-trochantériennes*. Cahiers d'Enseignement de la SOFCOT N°69, Ph. Vichard (ed). Expansion Scientifique Publications, Paris, 1999, pp 139-145.
26. Pitto R, Koessler M, Kuehle J. Comparison of fixation of the femoral component without cement and fixation with use of a bone-vacuum cementing technique for the prevention of fat embolism during total hip arthroplasty. A prospective, randomized clinical trial. *J Bone Joint Surg* 1999 ; 81-A : 831-843.
27. Pitto RP. The mortality and social prognosis of hip fractures. A prospective multifactorial study. *Int Orthop* 1994 ; 18 : 109-13.
28. Puget J, Tricoire JL. Traitement chirurgical des métastases de l'extrémité supérieure du fémur. In : *Fractures trochantériennes et sous-trochantériennes*. Cahiers d'Enseignement de la SOFCOT N°69, Ph. Vichard (ed). Expansion scientifique publications, Paris, 1999, pp 146-167.
29. Puget J, Tricoire JL, Chiron P, Utheza G. Reprise des faillites des ostéosynthèses des fractures cervico-trochantériennes du sujet âgé. In : *Les fractures trochantériennes du sujet âgé*. Saillant G, Laude F, Mabesoone F (eds). Sauramps Médical, Montpellier, 1996, pp 147-154.
30. Said GZ, Farouk O, El-Sayed A, Said H. Salvage of failed dynamic hip screw fixation of intertrochanteric fractures. *Injury* 2006 ; 37 : 194-202.
31. Saragaglia D, Carpentier E, Gordeff A, Legrand JJ, Faure C, Butel J. [Trochanteric fracture in the elderly : a comparison of the results of Ender's nailing, internal fixation and prosthetic replacement.] (French). *Rev Chir Orthop* 1985 ; 71 : 179-186.
32. Sarathy MP, Madhavan P, Ravichandran KM. Nonunion of intertrochanteric fractures of the femur : treatment by modified medial displacement and valgus osteotomy. *J Bone Joint Surg* 1995-B ; 77 : 90-92.
33. Saudan M, Lubbeke A, Sadowski C, Riand N, Stern R, Hoffmeyer P. Pertrochanteric fractures : is there an advantage to an intramedullary nail ? A randomized, prospective study of 206 patients comparing the dynamic hip screw and proximal femoral nail. *J Orthop Trauma* 2002 ; 16 : 386-393.
34. Sharma H, De Leeuw J, Rowley DI. Girdlestone resection arthroplasty following failed surgical procedures. *Int Orthop* 2005 ; 29 : 92-95.
35. Stoffelen D, Haentjens P, Reynders P, Casteleyn P, Broos P, Opdecam P. Hip arthroplasty for failed internal fixation of intertrochanteric and subtrochanteric fractures in the elderly patient. *Acta Orthop Belg* 1994 ; 60 (Suppl 1) : 135-139.
36. Utrilla AL, Reig JS, Munoz FM, Tufanisco CB. Trochanteric gamma nail and compression hip screw for trochanteric fractures : a randomized, prospective, comparative study in 210 elderly patients with a new design of the gamma nail. *J Orthop Trauma* 2005 ; 19 : 229-233.
37. Vidal J, Allieu Y, Buscayret C, Paron M. [Treatment of various cervical-trochanteric fractures in the very old by extensive prosthesis of the upper end of the femur.] (French). *Acta Orthop Belg* 1976 ; 42 : 25-30.
38. Wu CC, Shih CH, Chen WJ, Tai CL. Treatment of cutout of a lag screw of a dynamic hip screw in an intertrochanteric fracture. *Arch Orthop Trauma Surg* 1998 ; 117 : 193-196.
39. Zhang B, Chiu KY, Wang M. Hip arthroplasty for failed internal fixation of intertrochanteric fractures. *J Arthroplasty* 2004 ; 19 : 329-333.