



Multilevel vertebral osteomyelitis and facet joint infection following epidural catheterisation

Ranganathan ARUN, Shafic Said AL-NAMMARI, S. M. Hossein MEHDIAN

From Queen's Medical Centre, Nottingham, United Kingdom, and Leeds General Infirmary, Leeds, United Kingdom

We report a case of multilevel vertebral osteomyelitis with facet joint infection after epidural catheterisation.

Back pain relating to regional anaesthetic techniques is common and usually self-limiting. However, it is essential to consider infection in any differential diagnosis. Prolonged use of these regional anaesthetics post-operatively makes the possibility of infection more likely. The microbiology of spine infection resulting from direct spread is not well documented but the few cases reported suggest a wide range of causative organisms. For this reason in cases of spinal infection resulting from epidural catheterisation every effort should be made to obtain a direct tissue sample for pathogen identification and one should not simply rely on blood cultures or non-specific empirical antimicrobials. Delays in commencing appropriate antimicrobials may result in considerable morbidity.

Keywords : epidural ; epidural anaesthesia ; vertebral osteomyelitis ; facet joint infection ; spondylodiscitis.

multilevel vertebral osteomyelitis with facet joint infection after epidural catheterisation.

CASE REPORT

A 56-year old diabetic male on steroid treatment underwent total colectomy and end ileostomy for an acute exacerbation of ulcerative colitis. An epidural catheter was sited for analgesia. Two weeks post-operatively the patient developed back pain and bilateral sciatica. Blood investigations revealed a normal leukocyte count ($8.9 \times 10^9/L$) but a raised ESR (80 mm/hr) and CRP (176 mg/L). Plain radiographs of the lumbosacral spine showed decreased disc space at T12-L1 and L1-L2 with irregular erosions of the vertebral bodies (fig 1). Magnetic Resonance Imaging (MRI) at this stage showed evidence of spondylodiscitis at T12, L1 and L2 (fig 2). Blood cultures grew *Staphylococcus aureus* sensitive to flucloxacillin. He was treated with intravenous benzyl penicillin and fluclo-

INTRODUCTION

Back pain relating to regional anaesthetic techniques is common and usually self-limiting. The increased use of regional anaesthetic techniques has increased the number and variety of complications associated with these procedures. Prolonged use of these methods post-operatively makes the possibility of infection more likely, especially in the immunocompromised. We report one case of

■ Ranganathan Arun, MRCS, Spinal Research Fellow.
■ S. M. Hossein Mehdian, MS (Orth), MD, FRCS (Ed), Consultant Spine Surgeon.

Queen's Medical Centre, Nottingham, United Kingdom.

■ Shafic Said Al-Nammari, MRCS, Clinical Fellow.
Leeds General Infirmary, Leeds, United Kingdom.

Correspondence : R. Arun, 45 St Cuthbert's Avenue, Marton In Cleveland, Middlesbrough, TS7 8RG, United Kingdom.
E-mail : arearoon@yahoo.com.

© 2007, Acta Orthopædica Belgica.

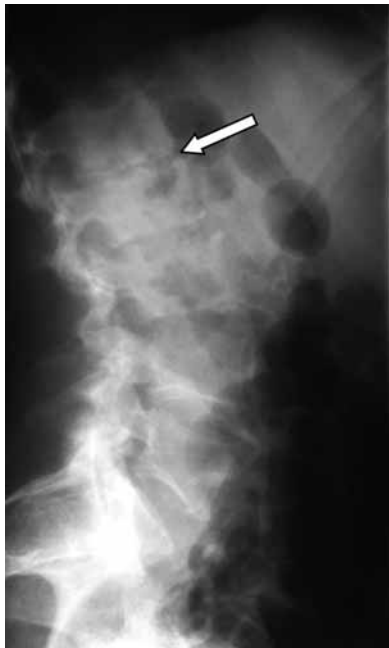

Fig. 1. — Plain lateral radiograph of the lumbosacral spine at initial presentation, arrowhead showing reduced L1/2 disc space.

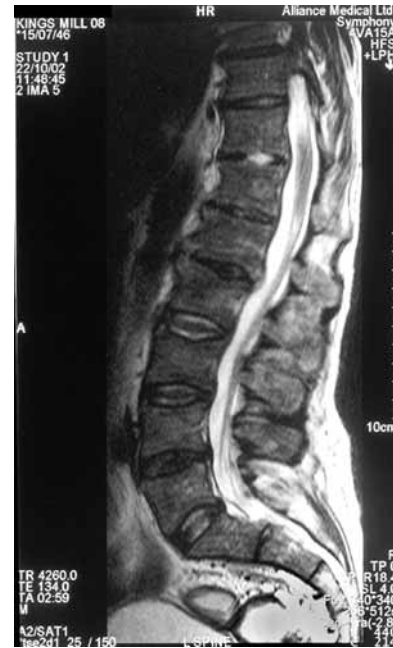

Fig. 2. — Sagittal T2 weighted MRI scan of the lumbosacral spine showing endplate irregularity and altered disc morphology and signal intensity at T12/L1 and L1/2 suggesting spondylodiscitis.

xacillin for 2 weeks followed by oral flucloxacillin for four weeks. Despite this his symptoms progressively worsened and his inflammatory markers remained elevated; he remained neurologically intact. At this point the patient was referred to our spinal unit. Plain radiographs now showed reduced disc spaces from T12 to L4 (fig 3). A repeat MRI scan revealed extensive spread of the infection to involve all the levels from T12 to L4 with fluid in the facet joint suggesting facet joint infection but without significant epidural abscess formation (fig 4) but with facet joint infection (fig 5). Blood cultures were now negative and a percutaneous Harlow Wood biopsy of the L4 vertebral body was performed. Histopathology revealed vertebral osteomyelitis (fig 6) and cultures from the tissue sample grew *Pseudomonas aeruginosa* sensitive to ceftazidime, gentamycin and ciprofloxacin. At this point the patient's spine was immobilised in a thoraco-lumbar brace and the patient was started on intravenous ceftazidime and gentamycin for

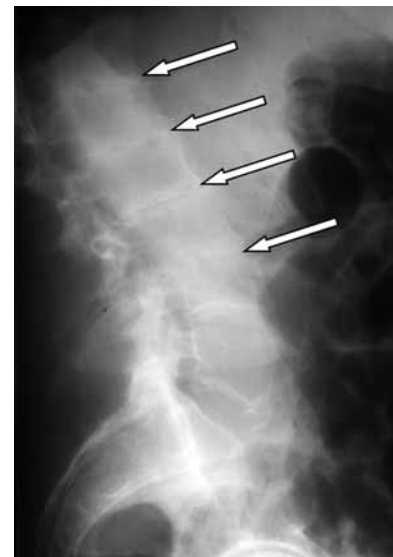


Fig. 3. — Plain lateral radiograph of the lumbosacral spine, arrowheads pointing towards reduced disc spaces from T12-L4 indicating the extensive spread of spondylodiscitis (cf. fig 1) to contiguous levels despite institution of antimicrobial therapy.

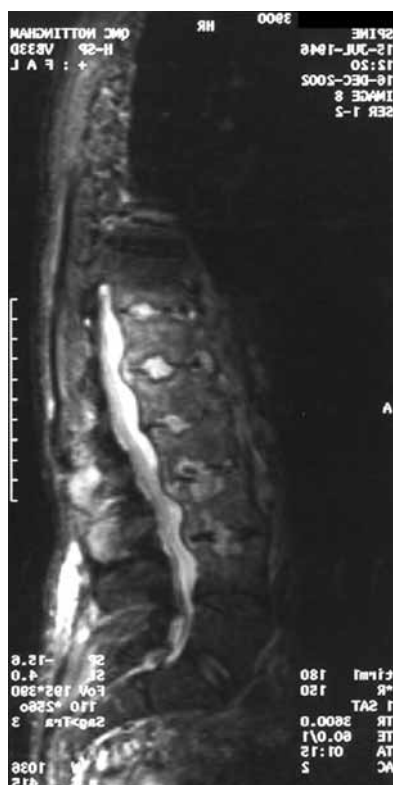

Fig. 4. — Sagittal T2 weighted MRI scan of the lumbosacral spine showing extensive multilevel spondylodiscitis from T11-L4 without epidural abscess formation.

6 weeks. At the end of this his inflammatory markers were on a downwards trend and his sciatica had resolved. The patient received a further 8 weeks of oral ciprofloxacin by which time his back symptoms had improved and his inflammatory markers had normalised. His last follow-up at two years showed the patient to be doing well except for mild back pain on extension and tenderness over the lumbar facets. He remained neurologically intact.

DISCUSSION

Reports of new-onset backache after epidural anaesthesia are common and vary from 2% to 31% (16). The most common causes of back pain after regional anaesthesia are thought to include haematoma formation, ligamentous trauma, reflex paraspinous muscle spasm, and ligamentous strain during patient positioning secondary to skeletal

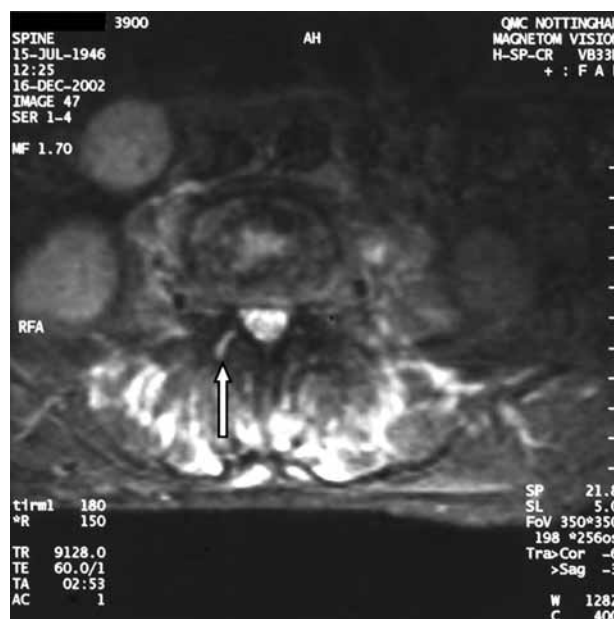

Fig. 5. — T2 axial MRI scan of lumbosacral spine at L3, arrowhead showing increased signal intensity in the right facet joint indicating fluid in the joint due to probable facet joint infection.

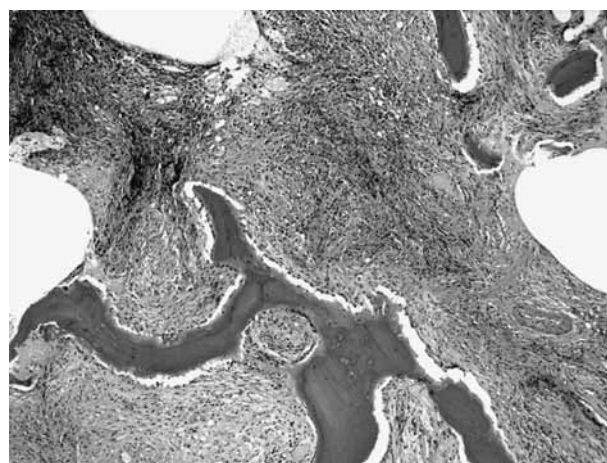


Fig. 6. — A microphotograph showing histopathology of the biopsy from L4 vertebral body. The clusters of leukocytes in the bony matrix indicate acute osteomyelitis.

muscle relaxation. Symptoms related to back pain are usually mild and respond well to conservative therapy (12). However it is essential to exclude sepsis in any differential diagnosis of back pain post epidural catheterisation. The proposed mechanisms of spinal infection after epidural

anaesthesia include haematogenous spread from a distant site (13), contiguous spread from surrounding sepsis and direct invasion either by skin bacteria through the needle track (4), contaminated syringes (7) or contaminated local anaesthetics (10).

Epidural abscesses are the most well documented infective complication of epidural catheter insertion (1,15). In contrast there have been few reports of vertebral osteomyelitis following epidural catheter use (2,3,8). Pyogenic vertebral osteomyelitis is a disease seen predominantly in men older than 50 years and the most common mechanism is haematogenous spread from an infected focus elsewhere within the body (11,14).

The cornerstone of the non-surgical management of vertebral osteomyelitis is antimicrobial therapy with or without spinal immobilisation. In haematogenous vertebral osteomyelitis some groups feel it is justifiable to commence antimicrobial therapy based on the results of blood cultures alone without the need for direct spinal biopsy and organism identification (9). This may be acceptable for haematogenous spine infections as they are almost always caused by *Staphylococcus aureus*, are monomicrobial and all these patients by definition have had at least one episode of bacteraemia (6, 9,11,14). Indications for biopsy include negative blood cultures, failure to respond to antimicrobials and to rule out differential diagnoses such as tumour.

Much less is known about the microbiology of spine infection after epidural catheterisation. It is known that *Staphylococcus aureus* is the most common colonising organism of epidural catheters (5) but there is not enough evidence to suggest that this is true for spine infections post epidural catheterisation. Indeed those cases reported in the literature reveal a wide range of causative organisms. In our case the organism isolated from the tissue sample was *Pseudomonas aeruginosa*. In fact, this is the sixth report of *Pseudomonas aeruginosa* infection following epidural catheter or injection (2,3,12,17,18). On the basis that spine infection caused by direct spread need not result in bacteraemia and that there is little known about the microbiology of spinal infection in this group we believe every effort should be made to

base antimicrobial therapy on organisms identified from spinal biopsy specimens. This is even more important when the patients' clinical and laboratory markers of infection are not settling on either empirical antimicrobials or antimicrobials directed against organisms isolated from blood cultures alone.

This is the first documented case of multilevel vertebral osteomyelitis with probable facet joint infection after epidural catheterisation. The mechanism of spread of infection from one level to the adjacent level is not very clear. Infection ordinarily does not originate in the vertebra or disc space, but rather, it spreads there from other sites via the bloodstream. Spinal arteries form two lateral anastomotic chains and one median anastomotic chain along the posterior surface of the vertebral bodies. Spinal arteries are the origin of periosteal arteries, which in turn give rise to metaphyseal arteries. In children, anastomoses between metaphyseal arteries are made by the intermetaphyseal arteries. However, in adults, these intermetaphyseal arteries degenerate. Septic emboli travel through this arterial system entering the metaphyseal arteries, which have become end arteries in the adult, causing a large area of infarction. Infarction of the vertebral endplates is followed by localised infection that subsequently spreads through the vertebral body and into the poorly vascularised disk space. Infection can then spread to the epidural space or paraspinous soft tissues. Intermetaphyseal communicating arteries allow the spread of septic thrombi from one metaphysis to the other in a single vertebral body. Other proposed routes of infection are the retrograde seeding of venous blood via Batson's plexus and the contiguous spread of infection into the vertebrae and disk beneath the anterior longitudinal ligament (ALL). The fact that metaphyseal bone near the anterior longitudinal ligament is richly vascular facilitates spread of infection by seepage beneath the ALL. The anterior and middle columns of the spine are the sites most often involved, although the infection may affect the posterior elements as well. The facet joints are relatively resistant to infection and the incidence of pyogenic facet arthropathy following spondylodiscitis is very rare.

CONCLUSION

Every effort should be made to obtain a direct tissue sample for organism identification in cases of spinal infection resulting from epidural catheterisation and one can not simply rely on blood cultures. Repeat MRI scan is indicated if the patient's condition deteriorates or does not improve despite antimicrobial therapy. Delays in commencing appropriate antimicrobials may result in considerable morbidity.

REFERENCES

1. **Borum SE, McLeskey CH, Williamson JB et al.** Epidural abscess after obstetric epidural analgesia. *Anesthesiology* 1995 ; 82 : 1523-1526.
2. **Chevalier X, Lavabre C, Claudépierre P, Larget-Piet B.** Iatrogenically induced vertebral osteomyelitis due to *Pseudomonas aeruginosa*. *Clin Exp Rheumatol* 1996 ; 14 : 191-194.
3. **Coapes CM, Roysam GS.** Vertebral osteomyelitis secondary to epidural catheter use : a case report. *Spine* 2001 ; 26 : 1492-1494.
4. **Du Pen SL, Peterson DG, Williams A, Bogosian AJ.** Infection during chronic epidural catheterization : diagnosis and treatment. *Anesthesiology* 1990 ; 73 : 905-909.
5. **Dyer RA.** Bacterial contamination of epidural catheters : microbiological examination of 502 epidural catheters used for postoperative analgesia. *Survey of Anesthesiology* 2005 ; 49 : 91-92.
6. **Hadjipavlou AG, Mader JT, Necessary JT, Muffoletto AJ.** Hematogenous pyogenic spinal infections and their surgical management. *Spine* 2000 ; 25 : 1668-1679.
7. **James FM, George RH, Naiem H, White GJ.** Bacteriologic aspects of epidural analgesia. *Anesth Analg* 1976 ; 55 : 187-190.
8. **Kruger M, Harries K, Dumont S.** Osteomyelitis following epidural analgesia in an immunocompromised patient. *Anaesthesia* 1998 ; 53 : 314-315.
9. **Lestini WF, Bell GR.** Spinal infection : patient evaluation. *Seminars in Spine Surgery* 1996 ; 8 : 81-94.
10. **North JB, Brophy BP.** Epidural abscess : a hazard of spinal epidural anaesthesia. *Aust N Z J Surg* 1979 ; 49 : 484-485.
11. **Patzakis MJ, Rao S, Wilkins J et al.** Analysis of 61 cases of vertebral osteomyelitis. *Clin Orthop* 1991 ; 264 : 178-183.
12. **Pinczower GR, Gyorke A.** Vertebral osteomyelitis as a cause of back pain after epidural anesthesia. *Anesthesiology* 1996 ; 84 : 215-217.
13. **Saady A.** Epidural abscess complicating thoracic epidural analgesia. *Anesthesiology* 1976 ; 44 : 244-246.
14. **Sapico FL, Montgomerie JZ.** Vertebral osteomyelitis. *Infect Dis Clin North Am* 1990 ; 4 : 539-550.
15. **Strong WE.** Epidural abscess associated with epidural catheterization : a rare event ? Report of two cases with markedly delayed presentation. *Anesthesiology* 1991 ; 74 : 943-946.
16. **Usubiaga JE.** Neurological complications following epidural anesthesia. *Int Anesthesiol Clin* 1975 ; 13 : 1-153.
17. **Wenningsted-Torgard K, Heyn J, Willumsen L.** Spondylitis following epidural morphine. A case report. *Acta Anaesth Scand* 1982 ; 26 : 649-651.
18. **Yue WM, Tan SB.** Distant skip level discitis and vertebral osteomyelitis after caudal epidural injection : a case report of a rare complication of epidural injections. *Spine* 2003 ; 28 : E209-E211.