



Navigated total knee arthroplasty in a patient with severe diaphyseal deformities

János PATAI, Gábor JANOSITZ, László MÉCS, Kálmán TÓTH

From the University of Szeged, Szeged, Hungary

A 65-year-old patient presented with severe osteoarthritis of the knee, 47 years after a severe polytrauma in which he had presented diaphyseal fractures of the left femur and tibia. These fractures had been treated conservatively and had healed with major deformities.

He underwent total knee arthroplasty with navigation assistance. This allowed for optimal component positioning and restoration of a correct limb alignment. The early functional result was excellent.

Navigation assistance appears of particular interest for total knee arthroplasty in such cases with complex post-traumatic diaphyseal deformities.

Keywords : total knee arthroplasty ; computer navigation ; femur ; tibia ; diaphyseal deformities.

a better functional outcome than achieved with conventional implantation, and accordingly navigated TKA now accounts for up to 20% of all TKAs in some countries (2, 3, 6).

Femoral or tibial diaphyseal fractures that have healed with a deformity should as a rule be corrected and the alignment restored before or during the prosthesis implantation (4, 9). In our case this option was not reasonably possible, and we therefore decided to use computer navigation. Although navigated TKA is already used routinely worldwide, very few similar cases have been reported so far.

CASE REPORT

A 65-year-old male patient was admitted to our institution in September 2005, with severe knee pain and loss of motion due to severe knee osteoarthritis. He had an American Knee Society

INTRODUCTION

Total knee arthroplasty (TKA) has been performed in Hungary for over 15 years (1); the first navigated TKA was carried out in 2001. One of the main requisites of total knee arthroplasty is correct positioning of the implants. With conventional arthroplasty techniques, correct alignment is ensured using extra- and intramedullary alignment guides.

Navigated TKA provides a better alignment than does the conventional technique, with a more accurate ligament balance and presumably fewer component failures in the long term. Comparative studies have revealed that navigated TKA results in

■ János Patai, MD, Resident Orthopaedic Surgeon.

■ László Mécs, MD, Consultant Orthopaedic Surgeon.

■ Kálmán Tóth, MD, Head of Department.

Orthopaedic Clinic, University of Szeged, Szeged, Hungary.

■ Gábor Janositz, MD, Consultant Orthopaedic Surgeon.

Orthopaedic Department, Bács-Kiskun County Hospital, Training Hospital of Szeged University, Szeged, Hungary.

Correspondence : János Patai, Orthopaedic Clinic, University of Szeged, H-6726 Szeged, Semmelweis u.6., Hungary. E-mail : patai@orto.szote.u-szeged.hu.

© 2007, Acta Orthopædica Belgica.

knee score of 22, and a functional score of 45. Active knee flexion was 5-40°, with significant pain during motion. He used walking aids (2 crutches).

Forty seven years previously, he had been run over by a truck while riding a motorcycle. He had suffered polytrauma with severe shock, and acute splenectomy had been performed because of spleen rupture. He had spent 21 days in coma because of a severe head injury, and his multiple lower limb fractures had therefore been treated conservatively. When his general condition improved, he had refused any corrective operation on his lower limbs.

His femoral and tibial diaphyseal fractures had healed with major deformities on the right side, with a varus and retrocurvation deformity of the femur (figs 1 & 2), and a valgus deformity of the tibia (fig 1).

After discussion, it was decided to proceed with total knee arthroplasty ; considering the marked deformities of his femoral and tibial diaphyses, it was decided to perform the operation with navigation.

The operation was performed with the Johnson & Johnson DePuy navigation system, which involves an implant-specific, passive marker technology-based, CT-free device. A PFC Sigma

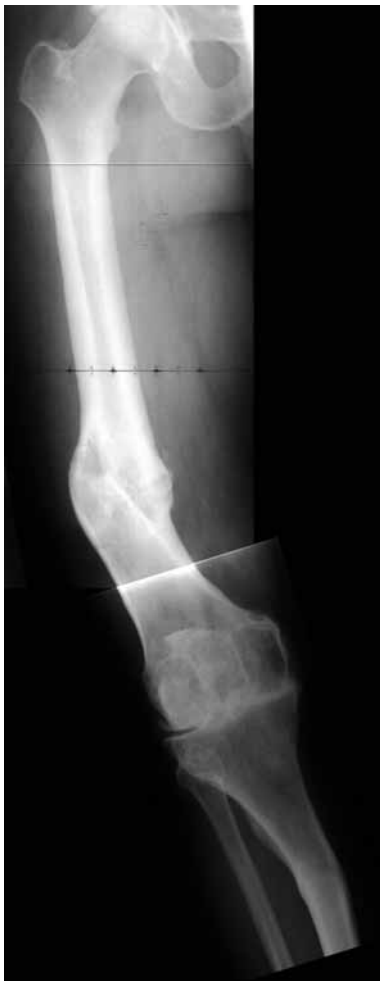

Fig. 1. — Right knee, preoperative AP radiograph.

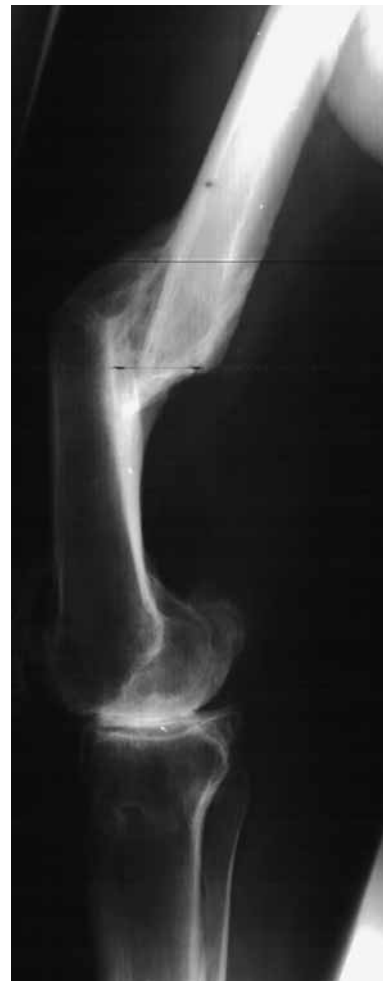

Fig. 2. — Right knee, preoperative lateral radiograph.

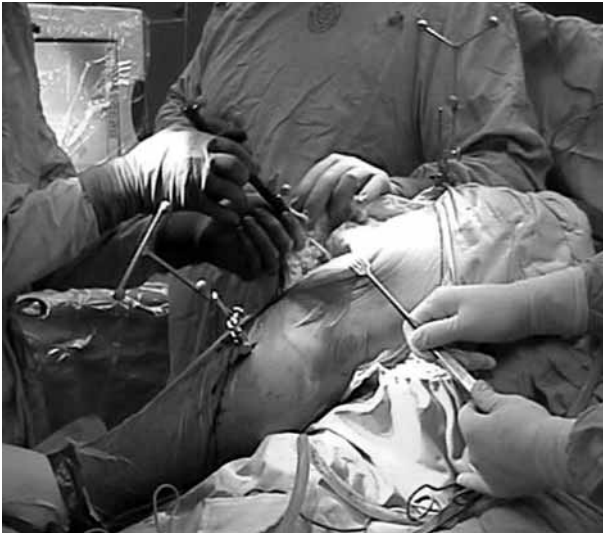

Fig. 3. — Application of reference guides.

posterior cruciate retaining modular total knee prosthesis was implanted.

The consecutive steps of the operation were identical with those of a regular navigated TKA : after insertion of the reference guides (fig 3) the patient's data were acquired (registration) (fig 4), which was the most important phase, considering the severe deformities present in this case. The computer established the center of rotation of the femoral head, then calculated the optimum mechanical axis of the limb, and finally suggested the size and alignment of the chosen implant.

Navigated bone resection was carried out with special instruments, and then following ligament balancing, the chosen components were implanted (fig 4).

Two weeks postoperatively, he had a painless knee flexion of 0-70°, and a stable knee joint (fig 5).

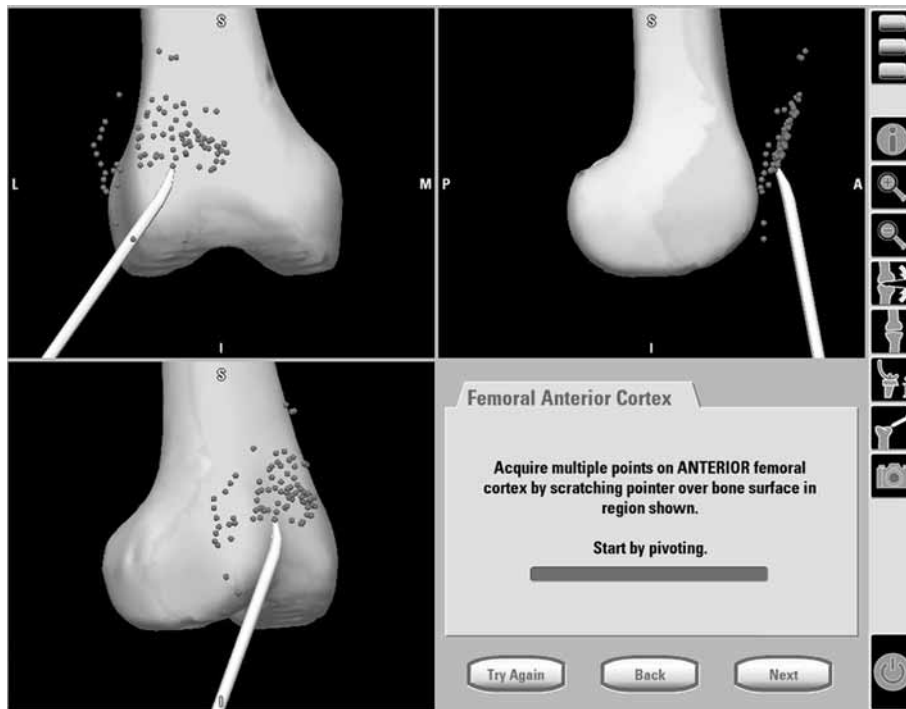


Fig. 4. — Registration of patient.

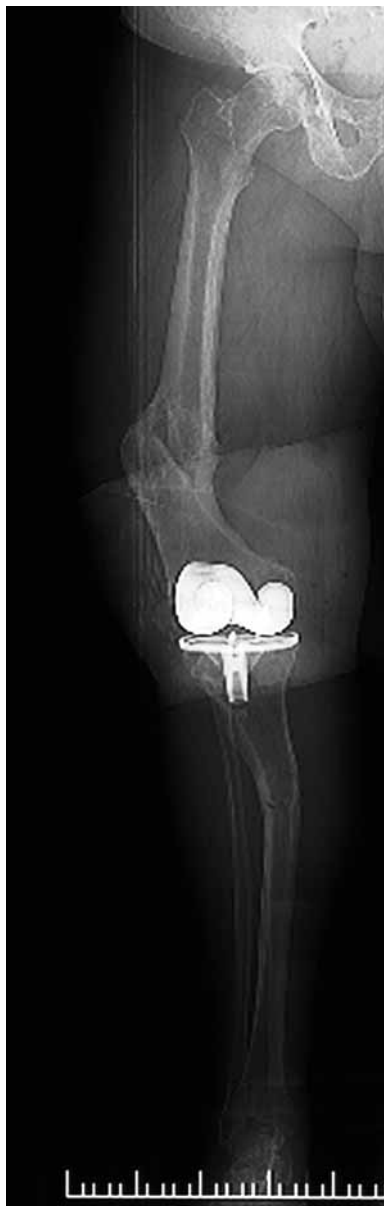

Fig. 5. — Right lower limb, postoperative AP radiograph.

One year postoperatively, the knee score was 89 and the functional score was 90, with a 0-90° knee flexion. The patient now walks without any walking aid, has resumed heavy physical work and is overall free of complaints.

DISCUSSION

In patients with osteoarthritis of the knee secondary to malunited femoral or tibial diaphyseal fractures, TKA usually necessitates correction of the limb alignment ; this can be done as a separate operation or at the same time as TKA (5, 8). In cases with periarticular deformities, the axis correction can be achieved by an osteotomy fixed with a plate or an intramedullary nail or using implants with long-stemmed revision components. For correction of diaphyseal deformities, intramedullary nailing or plating is the method of choice (7, 10).

In the present case, correction of the complex femoral and tibial diaphyseal deformities would have imposed a major additional surgical session, with a markedly extended and risky recovery period for the patient, who had already experienced a lengthy hospitalisation after his previous trauma, and for this reason he did not agree to this solution.

During conventional TKA, an extramedullary or less frequently an intramedullary guiding device is used for axial alignment on the tibial side, while on the femoral side the intramedullary technique is usually selected.

The major diaphyseal deformities in this case precluded the use of intramedullary guiding, and the extramedullary guiding procedure would not have yielded a correct antero-posterior implant alignment. Navigation ensured this alignment, together with correct varus-valgus alignment.

Navigation appeared to be the best available solution in this case with a view to achieve optimal alignment of the components and to restore a correct limb alignment.

REFERENCES

1. **Bellyei Á, Than P, Halmi V.** [Results of total knee arthroplasty procedures in our Clinic.] (in Hungarian). *Magyar Traumatológia Ortopédia Kézsebészet Plasztikai Sebészet* 1998 ; 41 : 319-326.
2. **Bergman N.** Regional trends in knee arthroplasty – Australia. Presented at Scorpio Masters, New York City, October 12th 2006.
3. **Bolognesi M, Hofmann A.** Computer navigation versus standard instrumentation for TKA : a single-surgeon experience. *Clin Orthop* 2005 ; 440 : 162-169.

4. **Hanssen AD, Dorr LD, Kurosaka M et al.** Case challenges in knee surgery. *J Arthroplasty* 2002 ; 17 : 83-84.
5. **Haspl M, Jelic M, Pecina M.** Arthroplasty in treating knee osteoarthritis and proximal tibia stress fracture. *Acta Chir Orthop Traumatol Cech* 2003 ; 70 : 303-305.
6. **Kim SJ, MacDonald M, Hernandez J, Wixson RL.** Computer assisted navigation in total knee arthroplasty : improved coronal alignment. *Z Orthop Ihre Grenzgeb* 2005 ; 143 : 323-328.
7. **Lonner JH, Siliski JM, Lotke PA.** Simultaneous femoral osteotomy and total knee arthroplasty for treatment of osteoarthritis associated with severe extra-articular deformity. *J Bone Joint Surg* 2000 ; 82-A : 342-348.
8. **Papadopoulos EC, Parvizi J, Lai CH, Lewallen DG.** Total knee arthroplasty following prior distal femoral fracture. *Knee* 2002 ; 9 : 267-274.
9. **Tóth K, Kelecsényi M, Greksa F, Fröhlich P.** [Use of revision knee prosthesis in primary total knee arthroplasty.] (in Hungarian). *Magyar Traumatológia Ortopédia Kézsebészet Plasztikai Sebészet* 2006 ; 49 : 275-279.
10. **Wang JW, Wang CJ.** Total knee arthroplasty for arthritis of the knee with extra-articular deformity. *J Bone Joint Surg* 2002 ; 84-A : 1769-1774.