



Isolated synovial cyst of the acromio-clavicular joint associated with joint degeneration and an intact rotator cuff

George M. KONTAKIS, Theodoros H. TOSOUNIDIS, Apostolos KARANTANAS

From the University Hospital of Heraklion, Crete, Greece

The majority of acromioclavicular joint cysts are the manifestation of underlying pathology of the rotator cuff. A chronic rotator cuff tear should be the first option in differential diagnosis, when facing such a condition, although this is not always the case. A case of a 67-year-old male patient, who abruptly developed a painless lump over his right acromioclavicular joint, is presented. Imaging studies were diagnostic for a cystic lesion, and degeneration of the acromioclavicular joint without communication with the subdeltoid bursa and the glenohumeral joint. The rotator cuff was intact. Surgical treatment, with cyst removal and resection of the distal end of the clavicle, was performed. The lesion was proved to be a synovial cyst. Eighteen months postoperatively, the patient was asymptomatic and no recurrence of the cyst was evident.

Keywords : acromioclavicular cyst ; isolated.

INTRODUCTION

An acromioclavicular (AC) joint cyst is a rarely reported condition. The common belief is that cysts over the AC joint are associated with a torn rotator cuff (2). The diagnosis of the cuff rupture is mandatory in order to treat the patient successfully, addressing the true pathology, i.e. the cuff tear, rather than only the epiphenomenon, i.e. the cyst. Thirty-four patients with subcutaneous cysts over the AC joint have been reported in the literature (1-3, 5, 6, 10-13, 15, 16, 18, 19). Thirty of thirty-four cysts

were associated with large rotator cuff tears. Of the four cases where the cysts were reported as isolated ganglia (1, 12, 15), only one was documented by ultrasonography, arthroscopy of the shoulder and histology (15).

We report a case of a synovial cyst over the AC joint associated with AC joint degeneration. The absence of a ruptured rotator cuff was documented preoperatively by ultrasonography and MRI. The diagnosis of the synovial cyst was confirmed by histological examination after excision of the lesion.

CASE REPORT

A 67-year old man, a retired school-teacher working in his farm, presented to our outpatient clinic with a large painless subcutaneous lump over

■ George M. Kontakis, MD, Assistant Professor.

■ Theodoros H. Tosounidis, MD, Resident.

Departments of Orthopaedics-Traumatology, University of Crete, University Hospital of Heraklion, Greece.

■ Apostolos Karantanias, MD, Associate Professor.

Department of Radiology, University of Crete, University Hospital of Heraklion, Greece.

Correspondence : George M. Kontakis, 1 Pindarou street, 71305 Heraklion, Crete, Greece.

E-mail : kontak@med.uoc.gr.

© 2007, Acta Orthopædica Belgica.

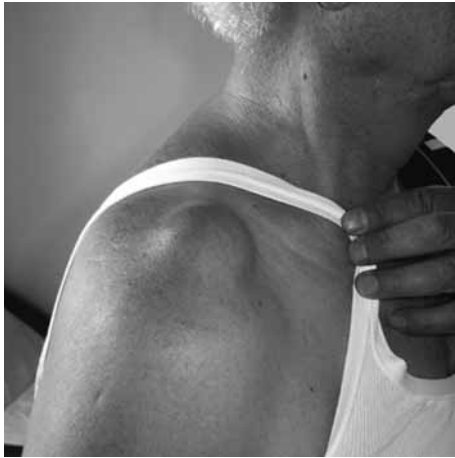

Fig. 1. — Supero-lateral aspect of the patient's right shoulder, as seen on his admission to hospital. A visible lump over the AC joint is apparent.

the right shoulder, which was first noticed 25 days previously (fig 1). He did not recall previous shoulder trauma and he experienced only mild symptoms at both shoulders especially after vigorous overhead activities (mild pain at rest or during forward elevation after strenuous manual work). The mass was symmetric with regular borders, no color

irregularity and was non tender on palpation. The right shoulder was almost fully mobile without pain. The only objective findings were a slight limitation of active forward flexion up to 160°, and a mild pain, which was provoked during cross-arm adduction. Further history and clinical examination were suggestive of mild cervical spondylosis.

Laboratory investigation (WBC-diff, ESR, CRP, Ca, P) was normal. Further work-up was not suggestive of any other underlying systemic pathology that could possibly be related the AC joint, e.g. calcium pyrophosphate deposits or calcium metabolism derangement.

Plain x-ray films showed AC joint space narrowing and osteophyte formation. Sonography revealed a cystic mass. No tear in the rotator cuff was demonstrated.

MR imaging examination was performed with a 1.5 Tesla scanner (Siemens Magnetom Sonata Maestro, Erlangen, Germany) and a phased array shoulder coil applying T1-w Spin Echo and fat suppressed T2-w Turbo Spin Echo pulse sequences in axial, oblique sagittal and oblique coronal levels. MR imaging findings consisted of a large cyst in communication with an osteoarthritic AC joint (fig 2). The rotator cuff was intact and there was no

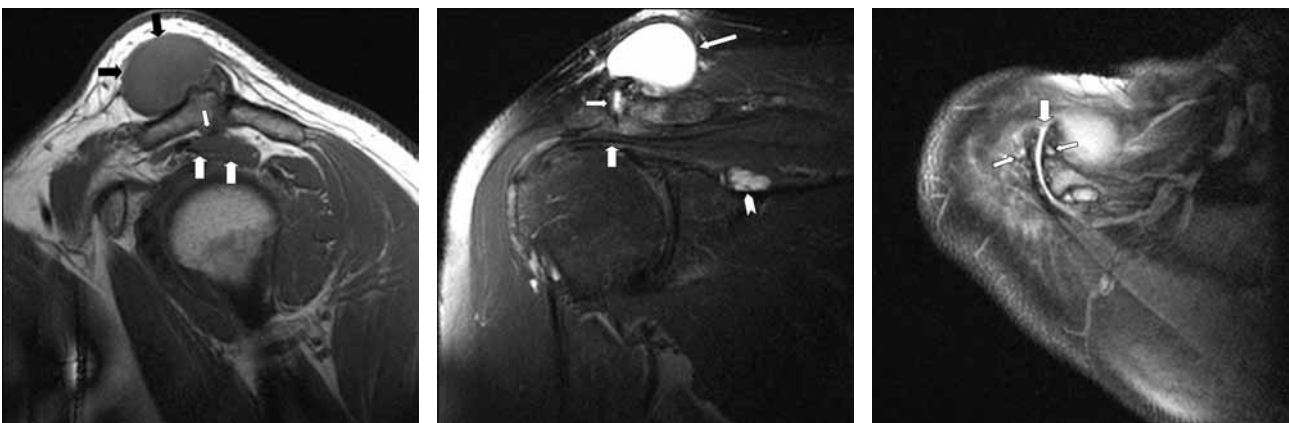


Fig. 2. — MR imaging of the right shoulder.

a) Oblique sagittal T1-w SE MR image shows the large synovial cyst (black arrows), the intact supraspinatus muscle (white arrows) and an acromial osteophyte projecting into the subacromial space (small white arrow).

b) Oblique coronal fat suppressed T2-w TSE MR image shows the large synovial cyst (long arrow), osteoarthritis of the acromioclavicular joint (small arrow) and an intact supraspinatus tendon. There are also asymptomatic venous varices into the scapular notch (arrowhead).

c) Axial proton density fat suppressed MR image shows the acromioclavicular joint osteoarthritis with joint effusion (thick arrow) and subchondral cysts bilaterally (small arrows).

significant intraarticular effusion. The cyst presented as a well defined lesion with intermediate signal intensity on T1 and high signal intensity on T2-w images.

Under general anaesthesia, the patient underwent resection of the cyst and of the distal end of the clavicle (Mumford procedure). In the beginning of the procedure the viscous content of the cyst was aspirated. Examination of the fluid under polarised light microscopy did not reveal crystal deposition. After an unsuccessful attempt to excise the cyst "en bloc", it was removed together with the distal 1 cm of the clavicle and the macroscopically torn joint meniscus. Figure 3 shows the appearance of the opened cyst before its resection. AC resection was considered the best treatment, since it addressed the possible cause of the pathologic process, i.e. AC joint arthritis.

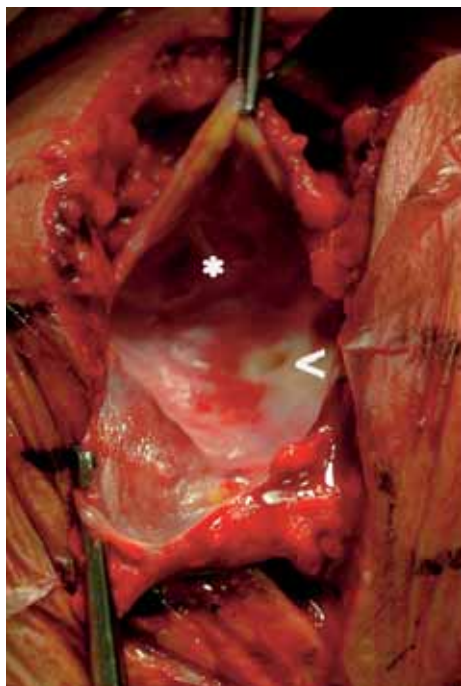


Fig. 3. — Intraoperative view of the AC joint. The superior aspect of the cyst has been dissected. Areas of synovitis, as well as septa of the synovium are apparent (*), supporting the diagnosis of synovial cyst. A hole in the superior acromioclavicular ligament is seen (<), denoting the communication of the cyst with the AC joint.

Histological examination of the removed cyst was indicative of a synovial cyst (an outer layer of reactive connective tissue with an inner lining layer with synovial cells). The resected clavicle exhibited osteoarthritic degenerative changes.

Eighteen months postoperatively the patient is pain free and has a full range of shoulder joint motion.

DISCUSSION

To the best of our knowledge, our patient is the first documented case presented in the literature with an isolated synovial cyst arising from the AC joint. The vast majority of publications regarding "cystic masses" over the AC joint point out that these cysts are manifestations of rotator cuff pathology. Proper management includes addressing this pathology. Table I summarises the relevant publications on this topic.

Burns and Zvirbulis (1) were the first to mention a ganglion of the AC joint, in a patient with no known rotator cuff disease. One year after its excision, there was no recurrence of the lesion. Craig (2) reported two cases of large AC joint cysts in patients with rotator cuff tears. One patient was managed conservatively because of concomitant medical problems and the other was treated by AC joint arthroplasty, acromioplasty and cuff repair. Nardini (12) reported two cases of AC joint cysts with a torn rotator cuff and mentioned another two cases of possibly isolated AC joint cysts that he encountered during his 25 years practice, without however exclusion of a rotator cuff tear. Postacchini *et al* (13) also reported three patients with large cuff tears and cysts over the AC joint. Simple cyst excision, without addressing the ruptured cuff, resulted in cyst recurrence. Groh *et al* (6) treated four patients with chronic irreparable rotator cuff tears, degenerative arthritis of the glenohumeral joint and associated cysts over the AC joint with shoulder hemiarthroplasties. Utrilla *et al* (19) reported a case of an AC joint cyst in a patient with a massive and irreparable cuff tear. Excision of the cyst, acromioplasty and closure of the rotator cuff defect with a dura mater allograft

Table I. — The published series of cysts over the acromioclavicular joint

Publications (authors)	Number of patients with ACJ cysts	Associated RCT (number)	Diagnosis : Isolated Ganglion
Burns and Zvirbulis (1), 1984	1	Not known	1*
Craig (2), 1986	2	2	2*
Nardini (12), 1991	4	2	2**
Groh <i>et al</i> (6), 1993	4	4	
Postacchini <i>et al</i> (13), 1993	3	3	
Utrilla <i>et al</i> (19), 1995	1	1	
Le Huec <i>et al</i> (8), 1996	3	3	
Segmuller <i>et al</i> (15), 1997	1	0	1
Selvi <i>et al</i> (16), 1998	2	2	
Marino <i>et al</i> (10), 1998	1	1	
Cvitanic <i>et al</i> (3), 1999	1	1	
Echols <i>et al</i> (5), 2000	1 myxoma	1	
Montet <i>et al</i> (11), 2004	1	1	
Tshering <i>et al</i> (18), 2005	9	9	

Abbreviations : ACJ = acromioclavicular joint, RCT = Rotator Cuff Tear.

* not known rotator cuff condition.

** undocumented (recalled from author's memory).

was the selected treatment. The functional result was unsatisfactory. Le Huec *et al* (8) treated three patients with AC joint cysts associated with massive cuff tears. Treatment combined excision of the cyst, removal of the distal clavicle end, as well as synovectomy of the upper part of the pathological "humero-acromial" joint (without resection of the AC ligament). At a mean follow-up of 26 months, the pain was significantly reduced and no cyst recurrence was recorded. Segmuller *et al* (15) published the first documented case of a ganglion over the AC joint, without rotator cuff disease and with concomitant mild degenerative changes in the AC joint. Excision of the ganglion cyst and the lateral end of the clavicle was performed, and 18 months after the surgery the patient was free of symptoms without cyst recurrence. Selvi *et al* (16) reported two cases of a full-thickness rotator cuff tear followed by AC joint cyst formation in patients with longstanding erosive poly-articular rheumatoid arthritis. Marino *et al* (10) reported a patient with AC joint cyst associated with a rotator cuff tear. Successful treatment included excision of the cyst as well as resection of the distal one centimeter of the clavicle, and repair of the torn cuff. Cvitanic *et al* (3) considering a cyst over the AC joint as a gan-

glion, performed aspiration of the cyst. Because of the cyst recurrence, a second aspiration was performed two months later with injection of a corticosteroid, but the cyst again recurred.. MRI exam revealed a massive cuff tear with degeneration of the AC joint. Echols *et al* (5) published a case of juxtra-articular myxoma (a benign soft tissue tumour) of the shoulder presenting as a cyst of the AC joint. Underlying rotator cuff pathology (chronic tear) was present. Open staging biopsy confirmed the diagnosis of juxtra-articular myxoma involving the AC joint, a large portion of the acromion and the humeral head. The patient was treated successfully with aggressive surgical excision of the involved tissues. Montet *et al* (11) reported a case of intramuscular ganglion, in the trapezius muscle, arising from the AC joint and associated with a massive tear of the rotator cuff. This was the first report of an AC joint cyst related to cuff pathology which had penetrated the muscle belly instead of the subcutaneous tissue. In a recently published paper, Tshering Vogel *et al* (18) presented 9 cases with AC joint cysts, all of which were associated with rotator cuff tears. The authors concluded that a soft tissue mass arising over the AC joint might be the first presentation of a chron-

ic extensive rotator cuff tear. They emphasised the value of MRI for the demonstration of this combination. Three out of 9 patients suffered from calcium pyrophosphate dihydrate crystal deposition disease, a condition which is frequently associated with rotator cuff tears.

In general, two mechanisms have been proposed to explain the pathogenesis of cysts in degenerative joint disease: the first implicates elevated intra-articular pressure which permits intrusion of synovial fluid through the joint cartilage, and the second states that the contusion secondary to the impaction of apposing osseous structures results in microfractures and vascular insufficiency, which leads to necrosis and subsequent cyst formation (14). Regarding the pathogenesis of the acromioclavicular cysts there is limited data in the orthopaedic literature. Probably, in cases with longstanding tears of the rotator cuff, synovial fluid from the glenohumeral joint leaks through the torn cuff into the AC joint (2). However, in common clinical practice, a minority of rotator cuff tears leads to cyst development. Perhaps an upward migrated humeral head, resulting from massive cuff tear, irritates the AC joint and perforates the frayed inferior joint capsule (11, 12). The synovial fluid enters and distends the superior capsule of the AC joint, and elevates the skin. With cyst enlargement the channel of communication may be compressed and the flow is impeded (3, 7). Inspissation of the synovial fluid contained in the cyst may produce a further decrease in the flow. A layer of fibrous tissue may totally occlude the communicating channel. This may explain the absence of a demonstrable communication with the glenohumeral joint of cysts during diagnostic evaluation (arthrography, CT-artrography, MRI) (3, 9). Ganglion cysts are differentiated from synovial cysts by the lack of a synovial lining (17). Their formation could be attributed to mucoid degeneration and disintegration of collagen fibers in the connective tissue. The increased liquefaction of the collagen fibers is surrounded by dense collagen bundles, which form a delimiting capsule (17).

It has been postulated by some authors that the AC joint arthritis can lead to impingement syndrome and may cause rotator cuff tear. The pro-

posed mechanism of such an hypothesis is impingement of the hypertrophic spur, at the under-surface of the acromion, on the underlying rotator cuff (4, 18). The early management of the arthritic AC joint in the presented patient could be considered as a prevention of such an evolution.

From the presented information it is obvious that the majority of AC joint cysts are manifestations of an underlying pathology (tearing) of the rotator cuff. Usually the cystic masses are located subcutaneously over the AC joint, are non tender and recur after aspiration if the rotator cuff tear is not addressed. A chronic rotator cuff tear should be the first diagnostic thought when confronted with this condition. MRI has a substantial value in the diagnostic process and can guide to the proper management. Degenerative changes in the AC joint – earlier shown on MRI – the integrity of the rotator cuff and the cystic appearance of the mass which communicates with the AC joint are the clues for the suspicion of an isolated synovial cyst. The underlying pathology in such a case is AC joint degeneration. Excision of the cyst as well as resection of the distal clavicle and the degenerated joint meniscus, are the essential steps for a successful management and prevention of cyst recurrence.

REFERENCES

1. Burns SJ, Zvirbulis RA. A ganglion arising over the acromioclavicular joint: a case report. *Orthopedics* 1984; 7: 1002-1104.
2. Craig EV. The acromioclavicular joint cyst. An unusual presentation of a rotator cuff tear. *Clin Orthop* 1986; 202: 189-192.
3. Cvitanic O, Schimandle J, Cruse A, Minter J. The acromioclavicular joint cyst: glenohumeral joint communication revealed by MR arthrography. *J Comput Assist Tomogr* 1999; 23: 141-143.
4. de Abreu MR, Chung CB, Wessely M, Jin-Kim H, Resnick D. Acromioclavicular joint osteoarthritis: comparison of findings derived from MR imaging and conventional radiography. *Clin Imaging* 2005; 29: 273-277.
5. Echols PG, Omer GE Jr, Crawford MK. Juxta-articular myxoma of the shoulder presenting as a cyst of the acromioclavicular joint: a case report. *J Shoulder Elbow Surg* 2000; 9: 157-159.
6. Groh GI, Badwey TM, Rockwood CA Jr. Treatment of cysts of the acromioclavicular joint with shoulder hemiarthroplasty. *J Bone Joint Surg* 1993; 75-A: 1790-1794.

7. Jaysen MI, Dixon AS. Valvular mechanisms in juxtaarticular cysts. *Ann Rheum Dis* 1970 ; 29 : 415-420.
8. Le Huec JC, Zipoli B, Schaeverbeke T, Moinard M, Chauveaux D, Le Rebeller A. [Acromio-clavicular joint cyst. Surgical treatment] (in French). *Acta Orthop Belg* 1996 ; 62 : 107-112.
9. Malghem J, Vandenberg BC, Lebon C, Lecouvet FE, Maldague BE. Ganglion cysts of the knee : articular communication revealed by delayed radiography and CT after arthrography. *AJR Am J Roentgenol* 1998 ; 170 : 1579-1583.
10. Marino AJ, Tyrrell PN, el-Houdiri YA, Kelly CP. Acromioclavicular joint cyst and rotator cuff tear. *J Shoulder Elbow Surg* 1998 ; 7 : 435-437.
11. Montet X, Zamorani-Bianchi MP, Mehdizade A, Martinoli C, Bianchi S. Intramuscular ganglion arising from the acromioclavicular joint. *Clin Imaging* 2004 ; 28 : 109-112.
12. Nardini C. [The significance of acromioclavicular cysts. Their association with rupture of the rotation cuff.] (in Italian). *Minerva Orthop* 1991 ; 42 : 211-216.
13. Postacchini F, Perugia D, Gumina S. Acromioclavicular joint cyst associated with rotator cuff tear. A report of three cases. *Clin Orthop* 1993 ; 294 : 111-113.
14. Resnick D. *Diagnosis of Bone and Joint Disorders*. 4th ed. WB Saunders, Philadelphia, 2002, pp 1271-1279.
15. Segmuller HE, Saies AD, Hayes MG. Ganglion of the acromioclavicular joint. *J Shoulder Elbow Surg* 1997 ; 6 : 410-412.
16. Selvi E, De Stefano R, Frati E, Manganelli S, Manca S, Marcolongo R. Rotator cuff tear associated with an acromioclavicular cyst in rheumatoid arthritis. *Clin Rheumatol* 1998 ; 17 : 170-171.
17. Treadwell EL. Synovial cysts and ganglia : the value of magnetic resonance imaging. *Semin Arthritis Rheum* 1994 ; 24 : 61-70.
18. Tshering Vogel DW, Steinbach LS, Hertel R, Bernhard J, Stauffer E, Anderson SE. Acromioclavicular joint cyst : nine cases of a pseudotumor of the shoulder. *Skeletal Radiol* 2005 ; 34 : 260-265.
19. Utrilla LA, Gomez ML, Aznar PA, Gomez CR. Rotator cuff tear and acromioclavicular joint cyst. *Acta Orthop Belg* 1995 ; 61 : 144-146.