



Hip arthroscopy : Outcome and patient satisfaction after 5 to 10 years

Jürgen LONDERS, Jan VAN MELKEBEEK

From OLV-Middelares Hospital, Deurne, Belgium

We retrospectively evaluated outcome, complications, reoperations and global patient satisfaction 5 to 10 years after an arthroscopy of the central compartment of the hip joint in 56 consecutive patients. All patients suffered from unsolved hip pain for at least 6 months, had a positive Flexion-Adduction-Internal rotation test (FADIR-test) and a normal radiograph. The mean follow-up was 72 months (range: 60 to 120 months). Thirty-seven patients were male and 19 female, with a mean age of 34 years (range, 17 to 59 years). Forty-five were improved (6 only temporarily) and 11 had no improvement (7 underwent total hip arthroplasty). Outcome and patient satisfaction differ significantly and are primarily determined by the grade of cartilage damage. Patient satisfaction 5 to 10 years after an arthroscopy of the central compartment of the hip is high : 80% (n = 45) of the patients would undergo the same procedure again.

Keywords : hip arthroscopy ; 5 to 10 year outcome ; patient satisfaction.

INTRODUCTION

Since the first report, published in 1986 (10), hip arthroscopy has been shown to be a safe procedure (1) for a variety of indications (14, 17, 18, 19). It is a useful minimally invasive procedure to diagnose intra-articular hip pathology in patients with no signs of osteoarthritis on standard radiographs, and to treat mainly by debridement labral tears and cartilage lesions and to remove loose bodies. The

technique is still evolving, as not only the central compartment but also the peripheral compartment of the hip can be inspected (6). Very recently, microfracturing chondral lesions and suturing labral tears were described (9, 15). Short-term results after simple debridement have been shown to be promising (2, 20, 22). However to our knowledge, long term follow-up studies are lacking. This study presents the outcome, complications, reoperation rate and global patient satisfaction 5 to 10 years after an arthroscopy of the central compartment of the hip for a variety of pathological conditions, in a consecutive series of 56 patients.

MATERIALS AND METHODS

Between March 1996 and March 2001, the senior author performed 56 consecutive arthroscopies of the central compartment of the hip. All 56 patients, 37 male and 19 female with a mean age of 34 years (range, 17 to 59 years), were included in the study. They had ongoing hip pain for at least 6 months, not responding to conservative treatment. Clinical examination showed a positive Flexion, Adduction and Internal Rotation test (FADIR - test) (4). Preoperative radiographs were negative for

■ Jürgen Londers, MD, Orthopaedic Resident.

■ Jan Van Melkebeek, MD, Orthopaedic Surgeon.

Correspondence : Jürgen Londers, Fr. de Merodestraat 47, B-2800 Mechelen, Belgium.

E-mail : jlonders@telenet.be.

© 2007, Acta Orthopædica Belgica.

bony pathology. In particular, there were no signs of osteoarthritis, avascular necrosis or loose bodies. Hip arthroscopy was performed in the supine position (3). The treatment of the pathology found, consisted mainly in debridement (labral tears, cartilage lesions). Mobilisation of the hip and lower extremity was started immediately under supervision of a physiotherapist and weight bearing was restricted the first week. A retrospective review of clinical records and a telephone questionnaire were used to evaluate the 56 consecutive operated patients. Patient charts were analysed for patient demographics, pre-operative examination, per-operative findings, complications and postoperative outcome at 3 months post arthroscopy. All patients were asked at that time if they had improvement, no improvement or were worse. Cartilage lesions diagnosed at the time of surgery were classified using the Outerbridge classification and categorised into two groups: Outerbridge I-II and Outerbridge III-IV. At final follow-up, 5 to 10 years after their hip arthroscopy, patients were contacted and answered a specific set of questions during a telephone interview. Was the present condition of the hip during daily and sporting activities still better, the same or worse than before arthroscopy? Were they satisfied with the result and would they undergo the same procedure again? The χ^2 test was used to evaluate the correlation between the peroperative diagnosis, the postoperative outcome and patient satisfaction.

RESULTS

No patients were lost to follow-up and all were reached at an average of 72 months post arthroscopy (range: 60-120 months). The pathology found is summarised in figure 1. One complication (2%) occurred: a scrotal haematoma which resolved after a few weeks. At 3 months follow-up, 45 patients (80%) reported subjective improvement of their complaints, 10 patients (18%) had no improvement and 1 patient (2%) was made worse (fig 2). The results after 5 to 10 years showed that 38 patients (68%) still have no complaints during daily or sporting activities and 1 patient (2%) had no complaint during daily activities but reported that his hip problem had forced him to stop recreational running. Improvement was only temporarily (6 months to 4 years) in 6 patients (11%): 2 patients with a labral tear, 2 patients with a grade I-II cartilage lesion, 1 patient with a labral tear with a grade I-II cartilage lesion and 1 patient with a loose body. Four patients (7%) had no significant relief of their preoperative hip pain. At latest follow-up, 7 patients (12%) had undergone a hip arthroplasty at an average of 27 months (range, 11-72 months) post hip arthroscopy (fig 3). The vast

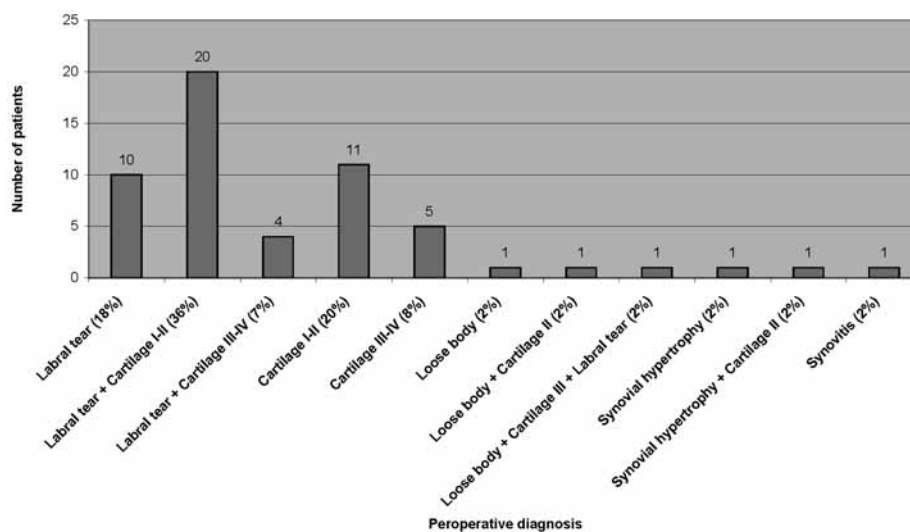


Fig. 1. — Hip pathology found at arthroscopy in 56 patients (cartilage lesions are graded according to Outerbridge)

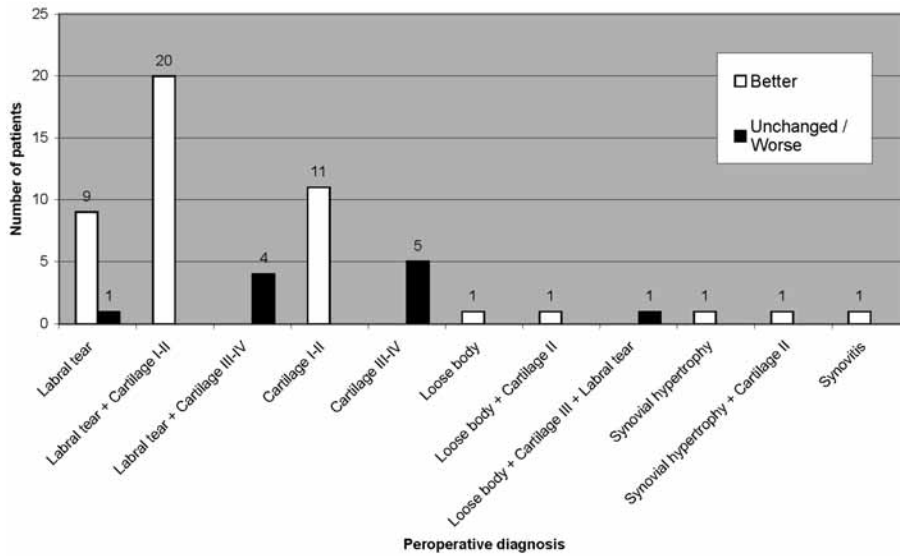


Fig. 2. — Subjective result at 3 months related to pathology

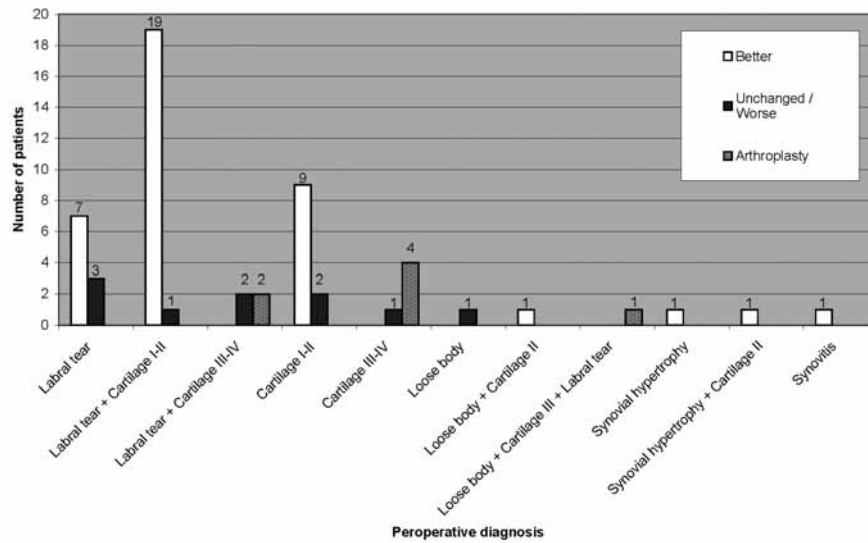


Fig. 3. — Subjective result and THA at final interview (5 to 10 years) related to pathology

majority of lesions diagnosed and treated were labral tears (n = 35.6%), 24 of them had an associated cartilage lesion and in one patient a labral tear was associated with a grade III cartilage lesion and an osteochondral loose body. After an arthroscopic debridement of the labrum and a possible associated cartilage lesion, 26 patients (74%) reported their final outcome as better and 28 (80%)

would undergo the same procedure again. Very few patients with a grade I and II cartilage lesion had a poor result. All 5 patients with a grade III-IV cartilage lesion have a bad result and 3 of them subsequently underwent a hip replacement. All 45 patients who were definitively or temporarily improved had no more than minor cartilage lesions grade II or less. Ten of the 11 patients who had no

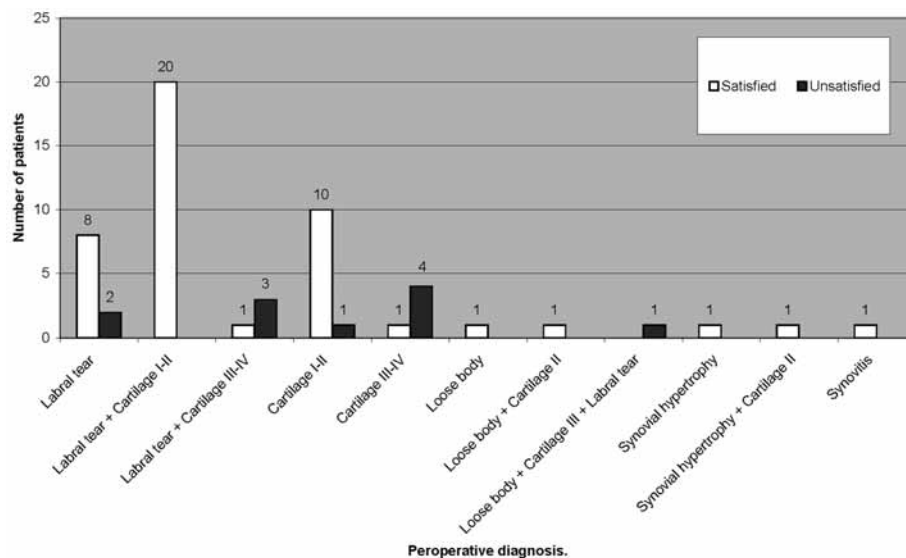


Fig. 4. — Patient satisfaction related to pathology

improvement had a grade III cartilage lesion or worse. Using the χ^2 -test the outcome of the grade I-II as compared to the grade III-IV Outerbridge cartilage lesions was significantly different ($p < 0.0001$). The degree of an associated cartilage lesion is a significant factor concerning the outcome and patient satisfaction following hip arthroscopy. Patient satisfaction is significantly related to the degree of cartilage lesion found ($p < 0.0001$). Forty-five patients (80%) would undergo the same procedure again (fig 4) : 39 patients who still had improvement at final follow-up, 5 of the 7 patients who had temporarily improvement and 1 patient who had no improvement. The 5 patients with only temporarily improvement were satisfied because they could continue their sporting activities (2 of them at a professional level) at least for a certain period. The one patient who had no benefit was satisfied because he was offered a clear diagnosis.

DISCUSSION

Since the first hip arthroscopy was described by Eriksson in 1986 (10), it has become increasingly clear that it is not only a diagnostic but also a therapeutic tool (9) in the treatment of young patients

with hip pain. In 1995 McCarthy *et al* stated that an arthroscopy of the hip is a valuable and viable procedure for patients with hip pain for at least 6 months (17). Byrd and Ganz considered the FADIR-test as the most sensitive test for intra-articular hip pathology (4, 12). Unsolved hip pain for at least 6 months with a normal radiograph and a positive FADIR-test during clinical examination were our preoperative selection criteria for hip arthroscopy. Hip arthroscopy confirmed intra-articular pathology and yielded a diagnosis in all 56 cases. Recent literature agrees that MRI arthrography is the preferred radiographic method to evaluate intra-articular hip pathology and that response to an intra-articular infiltration of an anaesthetic is a 90% reliable indicator for intra-articular abnormality (5, 13). Partial limbectomy yielded good short term results in previous studies (1, 2, 22). Our results at 3 months postoperatively are very good, except when the cartilage lesion found was a grade III or IV. Unlike previous studies (11, 22), the outcome and patient satisfaction were correlated with the specific per-operative diagnosis. We used the Outerbridge classification to subcategorize the degree of chondral damage. Our results show that a grade III-IV cartilage lesion is correlated with a bad result and poor patient

satisfaction. In agreement with the prospective short-term study of Byrd (2), we also found that chondral lesions, with or without a labral tear, are associated with a poorer result. Farjo et al. presumed already in 1999 that patients with hip pain and radiographic signs of arthritis are less likely to have long-term relief of symptoms (11). At 3 months only 1 patient with an uncomplicated labral tear had not benefited from the procedure. He was one of the early patients in this series. But even the mid-term results (5 to 10 years) are promising, as showed in our study. After an arthroscopic debridement of the labrum and a possible associated cartilage lesion, 26 patients (74%) reported their final result as better and 28 (80%) would undergo the same procedure again. The long-term consequence of a labral debridement is a concern. Robertson *et al* in a recent literature review found that the satisfaction ratio after labral debridement varied between 67% and 91% and the longest follow-up was 3.5 years (21). Some of the temporarily improved patients in our series with a labral tear and/or cartilage lesion grade I-II may have suffered from a femoroacetabular impingement (FAI) as described by Ganz *et al* in 2003 (12). Unfortunately, in the late 90's not much was known about this concept. Very recently, Kim *et al* showed that in patients with insufficient clinical improvement following an arthroscopic debridement, FAI is very likely to be the cause (16). We were not able to obtain the pre-operative radiographs that would enable us to retrospectively look for any sign of FAI in our study group. Further study must determine the superiority of suturing in some types of labral tears over debridement.

Complications are very rare. Clarke *et al* reported an overall complication rate of 1.4% (8). In our group only 1 patient (2%) had a minor complication, a scrotal haematoma which spontaneously resolved. In our heterogeneous study cohort of 56 patients, a high percentage of patients (80%) is very satisfied after an arthroscopy of the central compartment of the hip and would undergo the same procedure again, even when the 5 to 10 year outcome is considered.

We realise that this study has many shortcomings, as it is retrospective and no specific pre-

and postoperative scoring system was used. Because no reliable and validated scoring system existed for a non-arthritic hip in young patients in the past, we have tried to quantify the results by simply asking our patients if they had any benefit from the operation and if they would undergo the same procedure again. Nowadays, a recently validated non-arthritic hip score can be used for future studies (7).

CONCLUSION

A high mid-term patient satisfaction rate can be expected after arthroscopic debridement of a labral tear, debridement of a grade I-II cartilage lesion/flap, synovectomy and excision of loose bodies. Debridement of a grade III or IV cartilage lesion, according to the Outerbridge classification, gives a poor result.

REFERENCES

1. Baber YF, Robinson AH, Villar RN. Is diagnostic arthroscopy of the hip worthwhile? A prospective review of 328 adults investigated for hip pain. *J Bone Joint Surg* 1999; 81-B : 600-603.
2. Byrd JW, Jones KS. Prospective analysis of hip arthroscopy with 2-year follow-up. *Arthroscopy* 2000; 16 : 578-587.
3. Byrd JW. Hip arthroscopy. The supine position. *Clin Sports Med* 2001; 20 : 703-731.
4. Byrd JW. Hip arthroscopy : patient assessment and indications. *Instr Course Lect* 2003; 52 : 721-730.
5. Byrd JW, Jones KS. Diagnostic accuracy of clinical assessment, magnetic resonance imaging, magnetic resonance arthrography, and intra-articular injection in hip arthroscopy patients. *Am J Sports Med* 2004; 32 : 1668-1674.
6. Byrd JW. Hip arthroscopy by the supine approach. *Instr Course Lect* 2006; 55 : 325-336.
7. Christensen CP, Althausen PL, Mittleman MA, Lee J, McCarthy JC. The non arthritic hip score : reliable and validated. *Clin Orthop* 2003; 406 : 75-83.
8. Clarke MT, Arora A, Villar RN. Hip arthroscopy : complications in 1054 cases. *Clin Orthop* 2003; 406 : 84-88.
9. Crawford K, Philippon MJ, Sekiya JK, Rodkey WG, Steadman JR. Microfracture of the hip in athletes. *Clin Sports Med* 2006; 25 : 327-35.
10. Eriksson E, Arvidsson I, Arvidsson H. Diagnostic and operative arthroscopy of the hip. *Orthopedics* 1986; 9 : 169-176.

11. **Farjo LA, Glick JM, Sampson TG.** Hip arthroscopy for acetabular labral tears. *Arthroscopy* 1999 ; 15 : 132-137.
12. **Ganz R, Parvizi J, Beck M, Leunig M, Notzli H, Siebenrock KA.** Femoroacetabular impingement : a cause for osteoarthritis of the hip. *Clin Orthop* 2003 ; 417 : 112-123.
13. **Keeny JA, Peelle MW, Jackson J, Rubin D, Maloney WJ, Clohisy JC.** Magnetic resonance arthrography versus arthroscopy in the evaluation of articular hip pathology. *Clin Orthop* 2004 ; 429 : 163-169.
14. **Kelly BT, Williams RJ 3rd, Philippon MJ.** Hip arthroscopy : current indications, treatment options, and management issues. *Am J Sports Med* 2003 ; 31 : 1020-1037.
15. **Kelly BT, Weiland DE, Schenker ML, Philippon MJ.** Arthroscopic labral repair in the hip : surgical technique and review of the literature. *Arthroscopy* 2005 ; 21 : 1496-1504.
16. **Kim KC, Hwang DS, Lee CH, Kwon ST.** Influence of femoroacetabular impingement on results of hip arthroscopy in patients with early osteoarthritis. *Clin Orthop* 2007 ; 456 : 128-132.
17. **McCarthy JC, Busconi B.** The role of hip arthroscopy in the diagnosis and treatment of hip disease. *Orthopedics* 1995 ; 18 : 753-756.
18. **McCarthy JC.** Hip arthroscopy : when it is and when it is not indicated. *Instr Course Lect* 2004 ; 53 : 615-621.
19. **McCarthy JC, Lee J.** Hip arthroscopy : indications and technical pearls. *Clin Orthop* 2005 ; 441 : 180-187.
20. **O'Leary JA, Berend K, Vail TP.** The relationship between diagnosis and outcome in arthroscopy of the hip. *Arthroscopy* 2001 ; 17 : 181-188.
21. **Robertson WJ, Kadrmas WR, Kelly BT.** Arthroscopic management of labral tears in the hip. *Clin Orthop* 2007 ; 455 : 88-92.
22. **Santori N, Villar RN.** Acetabular labral tears : result of arthroscopic partial limbectomy. *Arthroscopy* 2000 ; 16 : 11-15.