



## The role of limb salvage surgery and custom mega prosthesis in multiple myeloma

Mayil Vahanan NATARAJAN, Paraskumar MOHANLAL, Jagadesh Chandra BOSE

*From the Department of Orthopaedics & Trauma, Madras Medical College & Research Institute, Govt. General Hospital, Chennai, India*

Nine patients with multiple myeloma underwent limb salvage surgery and custom megaprosthesis replacement for tumours involving long bones. The lower limb was commonly involved with an average age of 47.7 years at presentation. All patients had pathological fractures. Resection and reconstruction was done using custom megaprotheses. A proximal femoral prosthesis was used for proximal femoral tumours and an intercalary prosthesis for tumours involving the femoral shaft. One patient each had total femoral prosthesis and total knee prosthesis. With an average follow-up of 88.2 months, three patients died of their disease. One patient with total knee prosthesis had delayed deep infection requiring removal of the prosthesis and another patient with an intercalary prosthesis had a periprosthetic fracture and declined revision surgery. Radiological evidence of loosening was seen in one patient. The functional outcome was excellent in 3 and good in 3 patients. The 5-year Kaplan-Meier survival rate of the patients was 66.7%.

**Keywords** : multiple myeloma ; limb salvage ; custom prosthesis ; survival ; outcome.

### INTRODUCTION

Multiple myeloma is a primary and systemic neoplasm which represents a malignant proliferation of plasma cells and their precursors (1, 7, 14, 21). It is characterised by bone destruction resulting in pain, hypercalcaemia, osteopenia, renal failure,

recurrent bacterial infections and pathologic fractures (1, 12, 15, 20). The mainstay of treatment in most patients with multiple myeloma is chemotherapy and/or radiotherapy combined with bisphosphonates (1, 7). However surgical treatment is indicated in the treatment of certain complications like pathological fractures of extremities and vertebral compression fractures producing progressive neurological deficit or spinal instability (11, 17). As these patients have a relatively long period of survival compared to patients with other secondary bone tumours, prosthetic replacement for pathological fractures can provide better functional outcome and improve their quality of life (7, 21). We present the functional and oncological outcome of nine

---

■ Mayil Vahanan Natarajan, MS Orth, (M'as), M Ch Orth, (L'pool), PhD (Orth Onc), D Sc, Head of Department and Professor of Orthopaedics & Trauma.

*Department of Orthopaedics & Trauma, Madras Medical College & Research Institute, Govt. General Hospital, Chennai, India.*

■ Paraskumar Mohanlal, MS, MRCS (Ed), Registrar. *Medway Maritime Hospital, Gillingham, United Kingdom.*

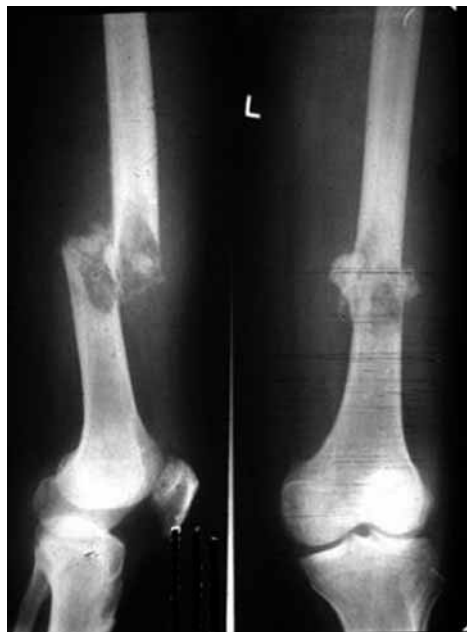■ Jagadesh Chandra Bose, MS, M Ch, Assistant Professor. *Department of Surgical Oncology, Govt. Royapettah Hospital, Chennai, India.*

Correspondence : Mayil Vahanan Natarajan, 4 Lakshmi Street, Kilpauk, Chennai, 600 010, India.

E-mail : drmayilnatarajan@gmail.com.

© 2007, Acta Orthopædica Belgica.

---



*Fig. 1.* — Pre-operative anteroposterior and lateral radiographs of a patient with multiple myeloma showing pathological fracture of the distal femur.

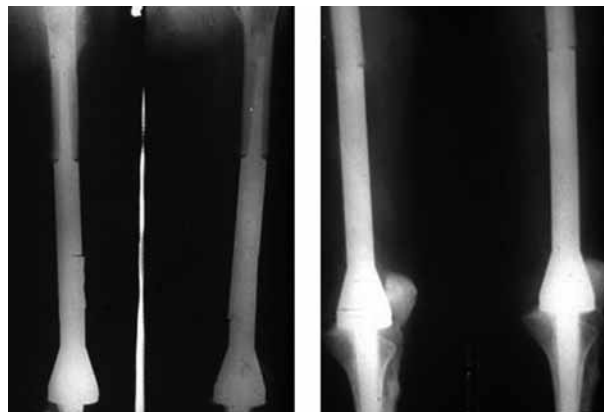patients with multiple myeloma who underwent limb salvage and custom megaprosthesis replacement for pathological fractures.

## MATERIALS AND METHODS

### Patient data

Between July 1990 and September 2004 ten patients with multiple myeloma underwent limb salvage surgery and reconstruction with custom megaprotheses. A retrospective study was performed and we present the results of nine patients with a minimum follow-up of 2 years. There were 4 males and 5 females with ages ranging from 35 to 60 years (average : 47.7). The femur was the most common location : proximal femur in 3 and femoral shaft in 3, of which one patient had extensive involvement of the shaft (figs 1 & 3). One patient each had involvement of the proximal humerus and the humeral shaft (table I).

All patients had a skeletal survey to detect multifocal involvement. Four patients each had Computed Tomography and Magnetic Resonance Imaging to assess the extent of involvement. The diagnosis was confirmed by open biopsy in four and closed biopsy in



*Fig. 2.* — Post-operative radiographs of the femur of the same patient after resection and reconstruction with a total knee prosthesis.

three. The remaining two patients were tertiary referrals with surgery done elsewhere and hence diagnostic biopsy was not required. All patients had a pathological fracture of the area involved.

### Resection and reconstruction

Resection and reconstruction was done using custom made prostheses. The material used was 316L stainless steel in 8 patients and titanium alloy in one patient. Wide margins of resection were achieved in 2 patients and marginal in 6 patients. A proximal femoral prosthesis was used to reconstruct defects for patients with proximal femoral lesion. Of the three patients with a tumour involving the femoral shaft, two had intercalary prostheses. The other patient had extensive involvement of the diaphysis and hence a total femoral prosthesis was used (fig 4). A total knee prosthesis, a proximal humeral prosthesis and an intercalary prosthesis were used for distal femoral, proximal humeral and humeral shaft tumours respectively (fig 2). All patients received chemotherapy and/or radiotherapy for treatment of other complications along with biphosphonates.

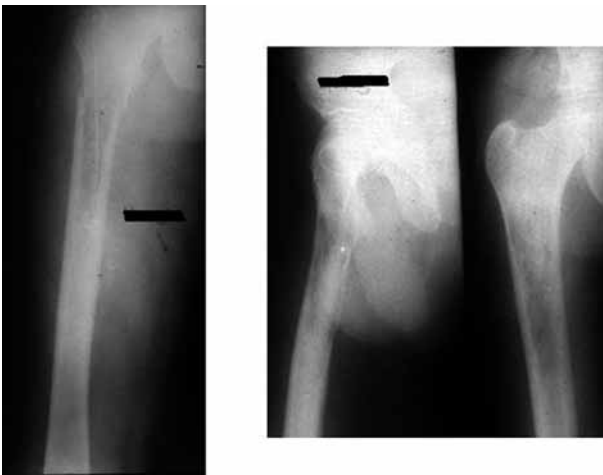
## RESULTS

Long term follow-up was done annually. The average follow-up period was 88.2 months (range : 60 to 166). Clinical examination and radiographs were performed to detect any complications. Also, functional assessment was done during each visit and the progress recorded.

Table I. — Demographic data of 9 patients with multiple myeloma treated by resection and reconstruction with custom megaprotheses

S. No	Age (Years)	Sex	Site	Biopsy	Type of Prosthesis	Margins of resection
1	60	Male	PF	Open	PFP	Marginal
2	58	Female	PF	Open	PFP	Wide
3	50	Female	PF	Closed	PFP	Wide
4	48	Female	DF	—	TKP	Marginal
5	35	Female	SF	Open	ICP	Marginal
6	49	Male	SF	Closed	ICP	Marginal
7	45	Male	SF	Open	TFP	Marginal
8	49	Male	SH	Closed	ICP	Marginal
9	36	Female	PH	—	PHP	Marginal

*Abbreviations* : PF-Proximal Femur ; DF-Distal Femur ; SF-Shaft of Femur ; SH-Shaft of Humerus ; PH-Proximal Humerus ; PFP-Proximal Femoral Prosthesis ; TKP-Total Knee Prosthesis ; ICP-Intercalary Prosthesis ; TFP-Total Femoral Prosthesis ; PHP-Proximal Humeral Prosthesis.



**Fig. 3.** — Pre-operative radiographs of a patient with multiple myeloma showing extensive involvement of the shaft of the femur.

### Complications

One patient (patient 6) with a femoral shaft lesion had extensive intra-operative bleeding requiring 6 units of blood transfusion. A patient who had a proximal femoral prosthesis (patient 2) developed superficial skin necrosis which required antibiotics and skin cover. Another patient who had a total knee prosthesis (patient 4) developed deep infection 2 years after surgery, requiring removal of the prosthesis. This patient denied further second

stage reconstruction. The patient who had an intercalary prosthesis (patient 6) had a periprosthetic fracture. He declined revision surgery and started mobilising after a period of bed rest with a brace (table II).

### Functional outcome

The functional outcome was assessed using Enneking's modified system of functional evaluation of surgical management of musculoskeletal tumours (8). This system rates combined active range of movement, pain, stability, deformity, strength, functional activity and emotional acceptance. As three patients died of disease during follow-up, the functional outcome reported was that on their last follow-up visit. According to this system, 3 patients had excellent outcome, 3 good, 2 fair and one poor outcome (table II).

All patients in our series had improved functional outcome.

### Oncological outcome

Three patients died of disease at 45, 52, 60 months of follow-up. None of the patients had local recurrence requiring amputation (table II). The Kaplan-Meier survival analysis done with death as the end point showed a 5-year survival rate of 66.7% (fig 5).

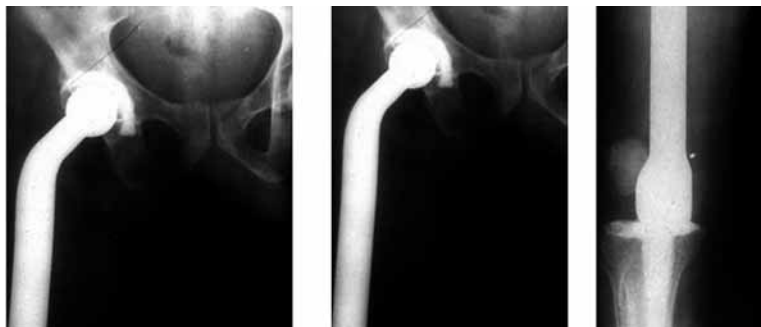

Fig. 4. — Post-operative radiographs of the femur of the patient after resection and reconstruction with total femoral prosthesis

Table II. — Follow-up and clinical outcome of 9 patients with multiple myeloma treated by resection and reconstruction with custom mega prostheses

S. No	Follow-up (months)	Complications	Functional Result	Oncological Result
1	60		Excellent	DOD
2	166	Skin necrosis	Good	CDF
3	165		Excellent	CDF
4	52		Poor	DOD
5	45	Deep Infection-prosthesis removal	Good	DOD
6	92		Fair	CDF
7	83	Intraoperative bleeding, Peri-prosthetic fracture	Fair	CDF
8	71		Good	CDF
9	60		Excellent	CDF

Abbreviations : DOD-Died of disease ; CDF-Continuously disease free.

## DISCUSSION

Multiple myeloma represents approximately 10% of all haematological cancers (1). The annual incidence is reported to be 5-10 per 100,000 population (18). It occurs as a result of unregulated, progressive proliferation of neoplastic monoclonal plasma cells (20). Although widespread disease with infiltration of the bone marrow or multiple destructive bone lesions is seen in most cases, a solitary bone lesion may be present in 5-10% of cases (2, 4, 20). Bone destruction is due to increased osteoclastic bone resorption and inhibition of osteoblastic bone formation resulting in osteolytic lesions predisposing to pathological fractures (20). Radiographs show lytic lesions or generalised osteopenia in 80% of patients with myeloma (14).

Bone scans are typically negative in multiple myeloma despite extensive bone damage (20).

Myeloma is common in elderly patients and rare in patients below 40 years of age (7, 9, 20). There is a slight male preponderance and it commonly occurs in the sixth or seventh decade of life (20). In our series, the average age was 47 years which was much less when compared to that reported in the literature. There was also a female preponderance in our series.

Treatment of multiple myeloma may be difficult and challenging. Alexanian *et al* (1) have reported that the extent of disease involvement, clinical behaviour, prognosis, complications and sensitivity to various therapeutic agents dramatically vary between patients. The natural course of the disease in the absence of treatment is progressive bone

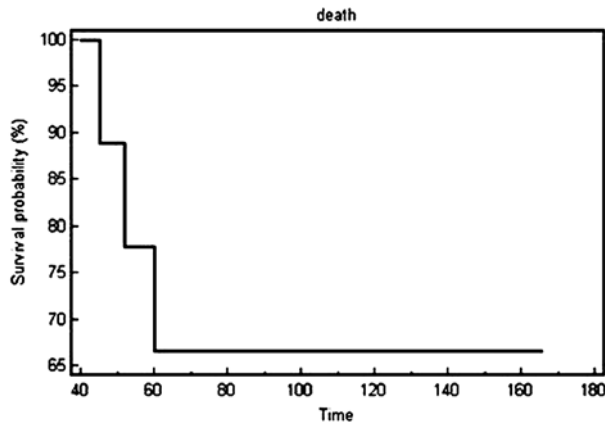


Fig. 5. — Kaplan-Meier survival graph of 9 patients with multiple myeloma treated by resection and reconstruction.

destruction, anaemia and renal failure, with infection being the most common cause of death (20). Though chemotherapy is successful in many patients, it does not produce skeletal healing, and hence there is a risk of osteopenia and subsequent pathologic fracture (14, 15). Also, use of radiation therapy is often able to relieve pain and diminish local tumour. However it does not sufficiently address a pathological fracture or associated instability which may require additional surgical stabilisation (7). The use of bisphosphonates in the treatment of multiple myeloma is promising and has been found to reduce bone destruction by its effect on bone turnover (15). Also, few studies have suggested that bisphosphonates in this situation may have an antitumour effect (5, 15, 19). Berenson *et al* (3) have reported that pamidronate improves quality of life and is an effective adjunctive treatment in the management of destructive skeletal lesions in myeloma.

All the patients in our series had pathological fractures warranting surgical stabilisation to enable early mobilisation and pain relief. Also, it is evident that pathological fractures are common in the weight bearing bones, as 7 of our patients had fractures involving the femur, necessitating resection and reconstruction. As the disease progression is slow and the long-term survival of these patients is better when compared to pathological fracture due to metastasis from other tumours (6, 21) surgical

treatment was aimed at achieving adequate margins of resection and reconstruction that can provide long term stability (10, 16).

Although surgical stabilisation has been well described for spinal compression fractures in myeloma (7, 11, 16, 17, 21), the literature is scarce regarding endoprosthetic replacement for pathological limb fractures. In our experience with 9 patients there were some major therapeutic challenges. Recurrent infection which is a major cause of morbidity in these patients (1, 15) could potentially result in an increased risk of prosthesis related infection. One patient in our series with total knee prosthesis had delayed deep infection of the prosthesis two years after surgery. He had recurrent episodes of chest infection, which was potentially the focus of infection. The prosthesis had to be removed because of a persistent discharging sinus and pain. This patient later succumbed to chest infection.

Also, as these patients are on chemotherapeutic agents and/or radiotherapy this may affect the timing of surgery and healing of the tissues. Alexanian *et al* (1) have reported that in patients with symptomatic myeloma, a delay in the institution of chemotherapy may be required in situations where emergency surgery is needed for pathologic fracture or when intensive antibiotic therapy is required for sepsis. Prior radiation to the surgical area can result in poor wound healing. A patient with a proximal femoral lesion who received pre-operative radiotherapy had skin necrosis following proximal femoral reconstruction, necessitating skin coverage. We would prefer to avoid radiation if a custom prosthesis is planned for the patient.

Furthermore, continued osteolysis and bone destruction around the prosthesis can result in loosening of prosthesis and symptoms of instability. One patient with an intercalary prosthesis of the humerus had radiological evidence of loosening at 18 months follow-up. He was asymptomatic and denied revision surgery. He was provided with a hinged elbow brace for support.

In addition dehydration, renal impairment, anaemia, chest infection and hypercalcaemia (1, 15) can have a profound effect on anaesthesia with increased morbidity in these patients and may

require a prolonged intensive care support post-operatively. Also, a dedicated rehabilitation team is required to enhance early mobilisation, prevent chest infection and help in successful recovery of the patient.

The median length of survival after diagnosis is reported to be 3 years (13, 20). Jonsson *et al* (11) have reported an average post operative survival of 2.3 years in 12 patients treated for myeloma of the spine. Durr *et al* (7) in a series of 27 patients who underwent spinal surgery for multiple myeloma have reported 59% 5-year survival rate and opined that these patients have a superior survival rate than metastatic disease. There are few reports showing long term survival. Wegener *et al* (21) have reported 16 years follow-up of one patient with cervical spine metastasis.

Treatment of pathological fractures in multiple myeloma with custom mega prostheses appears to be a feasible option as more than 65% of our patients had satisfactory functional outcome and were subjectively satisfied. They were able to mobilise early with good pain relief and had a useful functional limb. Durr *et al* (7) have reported that 73% of the 24 patients who survived after one year showed improvement in quality of life after spinal surgery in multiple myeloma.

## CONCLUSION

Limb salvage surgery with custom prostheses can be considered as a viable option for treating painful pathological fractures in multiple myeloma. It provides pain relief, early mobilisation, and good functional outcome with improved quality of life.

## REFERENCES

1. Alexanian R, Dimopoulos M. The treatment of multiple myeloma. *N Engl J Med* 1994 ; 330 : 484-489.
2. Bataille R, Sany J. Solitary myeloma : clinical and prognostic features of a review of 114 cases. *Cancer* 1981 ; 48 : 845-851.
3. Berenson JR, Lichtenstein A, Porter L *et al*. Efficacy of pamidronate in reducing skeletal events in patients with advanced multiple myeloma. Myeloma Aredia Study Group. *N Engl J Med* 1996 ; 334 : 488-493.
4. Chak LY, Cox RS, Bostwick DG, Hoppe RT. Solitary plasmacytoma of bone : treatment, progression, and survival. *J Clin Oncol* 1987 ; 5 : 1811-1815.
5. Dhodapkar MV, Singh J, Mehta J *et al*. Anti-myeloma activity of pamidronate in vivo. *Br J Haematol* 1998 ; 103 : 530-532.
6. Dürr HR, Kuhne JH, Hagena FW *et al*. Surgical treatment for myeloma of the bone. *Arch Orthop Trauma Surg* 1997 ; 116 : 463-469.
7. Dürr HR, Wegener B, Krodel A *et al*. Multiple myeloma : surgery of the spine : retrospective analysis of 27 patients. *Spine* 2002 ; 27 : 320-324.
8. Enneking WF. Modification of the system for functional evaluation of surgical management of musculoskeletal tumors. In : Bristol-Myers/Zimmer *Orthopaedic Symposium. Limb Salvage in Musculoskeletal Oncology*. Churchill Livingstone, New York, 1987, pp 626-639.
9. Ishida T, Dorfman HD. Plasma cell myeloma in unusually young patients : a report of two cases and review of the literature. *Skeletal Radiol* 1995 ; 24 : 47-51.
10. Jonsson B, Jonsson H Jr, Karlstrom G, Sjostrom L. Surgery of cervical spine metastasis : a retrospective study. *Eur Spine J* 1994 ; 3 : 76-83.
11. Jonsson B, Sjostrom L, Jonsson H Jr, Karlstrom G. Surgery for multiple myeloma of the spine : a retrospective analysis of 12 patients. *Acta Orthop Scand* 1992 ; 63 : 192-194.
12. Kyle RA, Gertz MA, Witzig TE *et al*. Review of 1027 patients with newly diagnosed multiple myeloma. *Mayo Clin Proc* 2003 ; 78 : 21-33.
13. Kyle RA, Rajkumar SV. Drug therapy : multiple myeloma. *N Engl J Med* 2004 ; 351 : 1860-1873.
14. Kyle RA. Multiple myeloma : review of 869 cases. *Mayo Clin Proc* 1975 ; 50 : 29-40.
15. Kyle RA. The role of bisphosphonates in multiple myeloma. *Ann Intern Med* 2000 ; 32 : 734-736.
16. Lofvenberg R, Lofvenberg EB, Ahlgren O. A case of occipitocervical fusion in myeloma. *Acta Orthop Scand* 1990 ; 61 : 81-83.
17. McLain RF, Weinstein JN. Solitary plasmacytomas of the spine : a review of 84 cases. *J Spinal Disord* 1989 ; 2 : 69-74.
18. Mundy GR. Myeloma bone disease. *Eur J Cancer* 1998 ; 34 : 246-251.
19. Shipman CM, Rogers MJ, Apperley JF *et al*. Bisphosphonates induce apoptosis in human myeloma cell lines : a novel anti-tumour activity. *Br J Haematol* 1997 ; 98 : 665-672.
20. Singer CR. ABC of clinical haematology : Multiple myeloma and related conditions. *B Med J* 1997 ; 314 : 960-963.
21. Wegener B, Muller PE, Jansson V *et al*. Cervical spine metastasis of multiple myeloma : a case report with 16 years of follow-up. *Spine* 2004 ; 29 : 368-372.