



Mini-external fixation of two- and three- part proximal humerus fractures

Nabil A. EBRAHEIM, Vishwas PATIL, Adeel HUSAIN

From the Medical University of Ohio, Toledo, Ohio, USA

A retrospective review of 64 patients (M 36, F 28, average age 55 years) with 29 two-part fractures and 35 three-part fractures of the proximal humerus was conducted at a Level 1 Trauma Center. All fractures were managed with the mini external fixator. Open reduction was performed in 11 cases, closed reduction in 53. The average follow-up was 21 months (range, 12-39). The final outcome, evaluated according to Neer's scoring system, was excellent in 63.4% of patients, good in 18.8%, fair in 12.7%, and poor in 5.1%. By 9 weeks, 85% of the fractures were healed and 97% by 12 weeks. Complications included non-union, superficial infection and deep infection, in two cases for each. Bicipital tendonitis occurred in five cases and secondary displacement of the fragments in four others. The small diameter of the pins used in the mini external fixator has the advantage of allowing the orthopaedic surgeon to fix the fracture in more than one plane and achieve an early acceptable range of motion. This technique appears attractive especially in polytrauma patients, as the procedure can be performed in the supine position and causes no additional blood loss.

Keywords : mini-external fixation ; proximal humerus ; two-and three parts fractures.

INTRODUCTION

External fixation of two-and three-part proximal humerus fractures has previously shown acceptable results (6, 13-15, 17). This recommendation is based on the concept that early motion prevents shoulder stiffness, the main problem encountered with

shoulder fractures. The main aim of treatment is to achieve a maximum range of motion of the shoulder with minimal complications (10, 11, 22).

We present a series of proximal humerus fracture cases managed by closed reduction or minimally invasive open reduction with mini external fixation. The objective is to assess the outcome of two-and three-part proximal humerus fractures managed by a mini external fixator device.

MATERIALS AND METHODS

Our study included 64 patients with two- and three-part proximal humerus fractures, selected from a surgical database of December 1999 to December 2004, who had at least 12 weeks of follow-up care. The age of the patients ranged from 17 to 89 years with a mean age of 55. Out of a total of 64 patients, 28 were female and 36 were male. In 48 patients, the dominant shoulder was involved. The fracture resulted from a motor-vehicle accident in 37 patients and a fall in 27 patients.

-
- Nabil A. Ebraheim, MD, Orthopaedic Surgeon.
 - Vishwas Patil, MD, Research Associate.
 - Adeel Husain, BS, MSIV.

Departments of Orthopaedic Surgery, Medical University of Ohio, Toledo, Ohio, USA.

Correspondence : Vishwas Patil, MD, Department of Orthopaedic Surgery, Medical University of Ohio, 3065 Arlington Avenue, Toledo, Ohio 43614, USA.

E-mail : vishwasorth@yahoo.com.

© 2007, Acta Orthopædica Belgica.

According to Neer's classification, 29 patients presented with a two-part fracture, and 35 patients with a three-part fracture. Out of these 64 patients there were 16 patients with one or more major comorbidities including diabetes mellitus (eight patients), pulmonary disease (two patients), coronary heart disease (three patients), Parkinson's disease (one patient) and cerebrovascular disease (two patients). All of the patients were operated upon within 72 hours from the time of injury with the aim of facilitating early closed reduction.

Operative technique

All procedures were performed by the senior author. The operative procedure was performed with the patient under general anaesthesia and in the supine position using a sandbag to elevate the shoulder. A four-step technique described by Ebraheim *et al* (3) was utilised to reduce and pin the fracture fragments. The important structures at risk are the main trunk of the axillary nerve and the posterior humeral circumflex artery from the greater tuberosity pins, the anterior branch of the axillary nerve from the proximal lateral pins, and the cephalic vein, biceps tendon, and musculocutaneous nerve from the anterior pins. Radiographic images (anteroposterior and axillary views) were obtained prior to draping and were utilised intra-operatively. The mini external fixator (Synthes, NY, USA) was the method of fixation in all patients. Two 2.5 mm terminally threaded pins were inserted in the shaft (distal fragment) and another two similar pins were inserted in the head of the humerus. The shoulder was externally rotated during placement of the greater tuberosity pins so as to move the axillary nerve and the posterior circumflex artery farther away from the humeral neck. When the greater tuberosity pins were inserted, great care was taken to prevent over-penetration of the medial cortex. In difficult cases a small incision and minimal dissection was used for direct access. The starting point for all lateral pins was at or distal to a point along the lateral aspect of the shaft equal to twice the distance from the top of the humeral head to a line perpendicular to the shaft at the inferior most margin of the articular cartilage of the humeral head (21). The fixator pins were then used as joysticks to obtain a reduction prior to attaching the frame; traction was useful during the manipulation and additional intra-operative anteroposterior and axillary views were obtained to decide acceptable reduction of the proximal humerus. Once reduction was obtained, all pins were connected to the external fixture bars using regular clamps to form a solid construct. Additional

anterior pins were utilised proximally when necessary to provide further stability, especially in three-part fractures and patients with osteoporotic bone.

Closed reduction could not be achieved in 11 patients (17%); in these cases reduction was assisted by a limited open reduction using a small skin incision with minimal dissection. A deltopectoral approach was used in 3 cases (4.7%) to reduce a button-holed surgical neck fracture, and a limited deltoid splitting approach to the subacromial space was utilised in 8 patients (12.5%) to reduce the greater tuberosity. The average operative time was 60 minutes, ranging from 35 to 90 minutes.

A sling was utilised for comfort and patients were encouraged to begin actively moving the involved extremity from post-operative day one. Pin care was instituted from post-operative day one, with twice daily cleaning of the pins with dilute hydrogen peroxide. Physical therapy was started immediately, beginning with pendulum exercises with progression to unrestricted range of motion by 6-7 weeks after fracture fixation. The decision of pin removal was made by radiological assessment of healing and functional activity. Pin removal was performed in the outpatient clinic without anaesthesia in 54 cases (86%) by 9 weeks and in the remaining 9 cases (14%) by 12 weeks. In one case, pins were removed at 6 weeks due to pin tract infection. In another case, the patient felt anxious and the pins were removed under anaesthesia.

Neer's scoring system was used for clinical evaluation. This scoring system assigns a total of 35 points for pain, 30 points for function, 25 points for motion and 10 points for reconstruction of the anatomy with a maximum score equalling 100. More than 89 points constitutes an excellent result, 80 to 89 a good result, 70 to 79 a fair result and less than 70 a poor result. Functional results calculated according to Neer's scoring system have been comparable to the Constant scoring systems (8, 23).

Radiological assessment compared the fractured shoulder and the contralateral non-fractured shoulder on both anteroposterior and axillary views. Radiographs were evaluated by an independent observer at two weeks post-operatively, 7-9 weeks postoperatively (average time of the external fixator removal) and on the final follow-up visit.

RESULTS

Follow-up of patients ranged from 12 to 39 months with an average follow-up of 21 months.

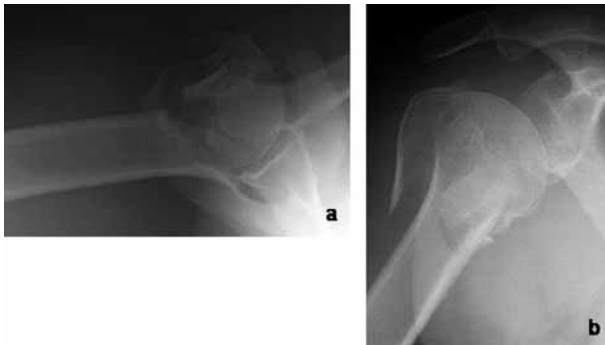

Fig. 1. — Axillary (a) and AP (b) radiographs of right shoulder showing comminuted three-part proximal humerus fracture.

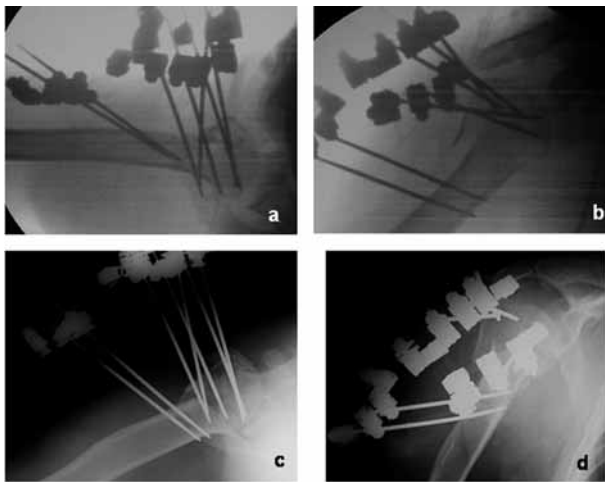


Fig. 2. — Axillary (a) and AP (b) intra-operative fluoroscopic images showing fracture reduction and external fixation pins 2-week postoperatively. Axillary (c) and AP (d) radiographs of right shoulder showing good fracture alignment and pins insertion sites.

Fracture healing was achieved after 9 weeks for 85% of patients and 12 weeks for 97%. Regarding functional results, 40 cases had an excellent score (63.4%) with a mean age of 42.6 years (fig 1-4). Thirteen cases scored good (18.8%) with a mean age of 48.2 years, 8 cases with an average age of 56.7 years graded fair (12.7%) and 3 patients (5.1%) whose average age was 52.0 years had poor functional outcome (table I).

There were two cases of non-union and four cases of infection, two of which were superficial and resolved with oral antibiotics. Another two

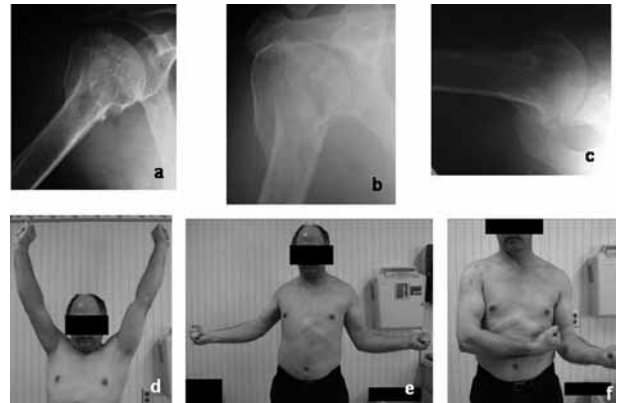


Fig. 3. — 16 month's postoperative Axillary (a) and AP (b) radiographs of right proximal humerus healed fracture. The mini external fixator has been removed. The shoulder joint space is normal. ROM is good in all directions.

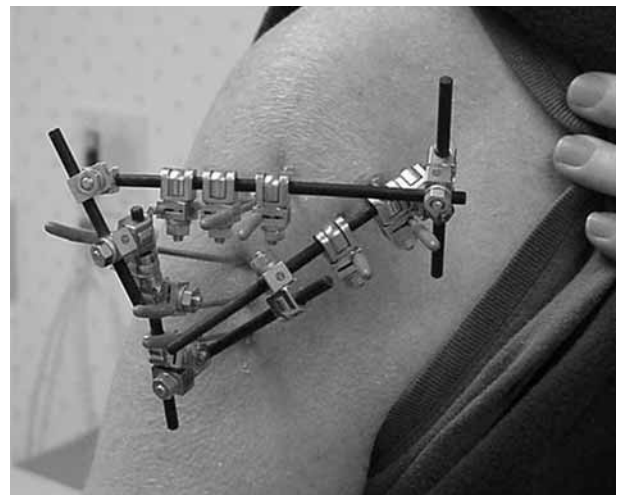


Fig. 4. — Framework of mini external fixator construct.

patients developed deep infection. One of these deep wound infections required removal of the pins at six weeks ; the patient stayed in a sling for two additional weeks and required surgical debridement, daily dressing changes and finally healed with a poor outcome. The other deep wound infection complication had a combined open reduction using the deltopectoral approach and external fixation and required removal of the hardware with repeat debridement. Non-union was encountered in this case, requiring autogenous bone grafting after the infection resolved. Healing was achieved in

Table I. — Range of motion (mean) of shoulder joint at final follow-up.

Grade	Age (mean)	Flexion (sagittal plane)	Abduction (coronal plane)	Extension	External rotation*	Internal rotation*
Excellent	42.6	173.2	168.4	44.5	48.4	81.8
Good	48.2	168.1	155.2	34.9	36.6	60.3
Fair	56.7	140.3	138.0	31.4	27.0	48.2
Poor	52.0	100.7	98.8	17.3	15.4	36.2

* From anatomical position with elbow bent.

28 weeks with a fair functional outcome. The reason of non-union in the other case could not be identified.

One case was complicated by reflex sympathetic dystrophy and resolved with sympathetic ganglion blockade. Five patients with bicipital tendonitis resolved within six weeks of removal of the external fixator and administration of anti-inflammatory medication. Four patients had secondary displacement of fragments at the first post-op visit. These displacements were minimal and hence no re-reduction was attempted. Two of these fractures had healed by 9 weeks after fixation and achieved an “excellent” final score, while the remaining two had healed by 12 weeks and were rated “good” by Neer’s score on the final assessment (table II).

DISCUSSION

The management of proximal humeral fractures continues to be a controversial subject. Previously, proximal shoulder fractures were treated with a wide range of options, namely non-operative, open reduction internal fixation, external fixation, and tension band fixation. However each procedure is not devoid of limitations or complications. A major disadvantage of non-operative treatment is failure to obtain early mobilisation which results in a high rate of shoulder stiffness and pain and malunion or non-union is likely with certain fracture types (5, 7, 25). A disadvantage of surgical internal fixation is difficulty in achieving rigid fixation in the cancellous bone of the proximal humerus. Cortical bone constitutes only a thin shell of bone and provides weak purchase for the internal fixation screws. Internal fixation has been reported to have

Table II. — Complications of treatment.

Complication	Number of cases
Non-union	2
Infection	4
Reflex sympathetic dystrophy	1
Bicipital tendonitis	5
Secondary displacement	4

increased complication rates due to hardware loosening and pullout of the screws (12, 22, 24). Additionally, the use of an internal fixation device includes intra-operative bleeding and an increased risk of avascular necrosis of the humeral head because of the disruption of the residual vascularity (22, 24). Post-operative adhesions further limit the range of motion as a result of extensive dissection needed in cases of open reduction and internal fixation (19).

Advantages of a closed reduction or minimally invasive open reduction and external fixation include the decreased risks of bleeding, post-operative fibrosis and osteonecrosis of fracture fragments. A decreased risk of osteonecrosis is seen because the ascending branch of the anterior humeral circumflex artery is not disturbed (24). Additionally, it seems to have the advantage of early mobility along with adequate anatomical reduction.

The use of external fixators in the management of proximal humeral fractures has begun to gain acceptance over the last 10 years. The idea of minimal fixation now lends to the fact that the blood supply to the head of the humerus is preserved. Hoffmann’s external fixators were used for this type of fracture by many authors (11, 14), but was

hindered by bulky Steinman pins, increasing the risk of injury to soft tissue and limiting space for application of multiple pins in different planes. The smaller pins used in the mini external fixator have less risk of soft tissue, neural and vascular injury. Multiple pins used in different planes add rotational stability to a fracture which has been reduced (2, 8, 9, 18). The principles of management for complex proximal humeral fractures are as follows: minimal soft tissue dissection to avoid the occurrence of avascular necrosis of the humeral head, adequate fixation to provide good stability for early rehabilitation, and an intact rotator cuff for an optimal functional outcome (7, 10). Closed reduction and the use of external fixators with small diameter pins achieve these principles adequately.

Chen *et al* (1) presented 19 patients managed by closed reduction and percutaneous fixation using cannulated screws in adults and percutaneous Kirschner wires in children. They recommended inserting the screws as subchondral as possible, but noted that this is a technically difficult procedure using widely separated screws, while avoiding penetration of the cartilage. In Chen's series, further displacement during follow-up occurred in one patient (5%) with secondary malunion and K-wire migration in two cases. Our series contained 4 patients with secondary displacement after 2 weeks of surgery during the follow-ups but no cases of migration, as the hardware was connected by the clamps and bars forming one construct. The final functional outcome was "excellent" in two cases and "good" in two cases of secondary displacement. The single construct provides more stability to the fracture and prevents any migration of hardware. Another advantage of the external fixation technique is the absence of internal hardware after healing, eliminating the need for additional surgery to remove the hardware.

Kristiansen *et al* (14) presented a series of 27 patients with proximal humerus fractures managed by Hoffman's external fixation system. Secondary displacement occurred in two patients, deep infection with pin loosening in two patients, and aseptic loosening was found in two patients. One case of non-union and two cases of avascular necrosis of the humeral head were evident on the

one-year follow-up radiographs. The improved results in our series may be due to the smaller diameter pins used in the mini external fixator, which allows application of pins in more than one plane, thus providing better rotational stability of the fracture with less chance of soft tissue or vascular injury.

There are some limitations to the current study. First, this is a retrospective study deriving the results from chart studies and radiographs. Second, there was a lack of control group and hence no definite comparisons with other treatment methods could be made. Third, a majority of the patients did not have data on the degree of osteoporosis, as a result of which no meaningful conclusions were determined with respect to the age of the patients, degree of osteoporosis and the clinical outcome. Further prospective studies in relation to degree of osteoporosis and the clinical outcome are necessary for recommending definite conclusions.

CONCLUSION

Small diameter pins proved an effective fixation for fractures of the proximal humerus in the current study as the functions of the deltoid muscle, rotator cuff and biceps tendon were not affected by the pins of the mini external fixator, ensuing early mobility even though the risk of imperfect fracture reduction, the small number of cases and other limitations have to be considered. It is a suitable alternative for the surgical management of two and three-part fractures of the proximal humerus with an acceptable functional outcome and an elimination of the need for subsequent surgical hardware removal. This technique appears attractive especially in polytrauma patients as the procedure can be performed in the supine position and avoiding additional blood loss.

REFERENCES

1. **Chen CY, Chao EK, Tu YK, Ueng SW, Shih CH.** Closed management and percutaneous fixation of unstable proximal humerus fractures. *J Trauma* 1998 ; 45 : 1039-1045.
2. **Durigan A Jr, Barbieri CH, Mazzer N, Shimano AC.** Two-part surgical neck fractures of the humerus : mechanical analysis of the fixation with four Schanz-type threaded

- pins in four different assemblies. *J Shoulder Elbow Surg* 2005 ; 14 : 96-102.
3. **Ebraheim N, Wong FY, Biyani A.** Percutaneous pinning of the proximal humerus. *Am J Orthop* 1996 ; 25 ; 500-506.
 4. **Hawkins R J, Switlyk P.** Acute prosthetic replacement for severe fractures of the proximal humerus. *Clin Orthop* 1993 ; 289 : 156-160.
 5. **Hodgson SA, Mawson SJ, Stanley D.** Rehabilitation after two-part fracture of the neck of the humerus. *J Bone Joint Surg* 2003 ; 85-B : 419-422.
 6. **Jaberg H, Warner JJP, Jakob RP.** Percutaneous stabilization of unstable fractures of the humerus. *J Bone Joint Surg* 1992 ; 74-A : 508-515.
 7. **Jakob RP, Miniaci A, Anson PS, Jaberg H, Osterwalder A, Ganz R.** Four-part valgus impacted fractures of the proximal humerus. *J Bone Joint Surg* 1991 ; 73-B : 295-298.
 8. **Jiang CY, Huang Q, Geng XS et al.** [Percutaneous pinning for the treatment of proximal humerus fractures.] (Chinese). *Zhonghua Wai Ke Za Zhi* 2004 ; 42 : 725-729.
 9. **Jiang CY, Wang MY, Rong GW.** [Biomechanical study of percutaneous pinning as the treatment of proximal humerus fractures.] (Chinese). *Zhonghua Wai Ke Za Zhi* 2004 ; 42 : 343-346.
 10. **Keene JS, Huizenga RE, Engber WD, Rogers SC.** Proximal humeral fractures : A correlation of residual deformity with long-term function. *Orthopedics* 1983 ; 6 : 173-178.
 11. **Ko JY, Yamamoto R.** Surgical treatment of complex fracture of the proximal humerus. *Clin Orthop* 1996 ; 327 : 225-237.
 12. **Koval KJ, Blair B, Takei R, Kummer FJ, Zuckerman JD.** Surgical neck fractures of the proximal humerus : a laboratory evaluation of ten fixation techniques. *J Trauma* 1996 ; 40 : 778-783.
 13. **Kristiansen B, Kofoed H.** Transcutaneous reduction and external fixation of displaced fractures of the proximal humerus. A controlled clinical trial. *J Bone Joint Surg* 1989 ; 705-B : 821-824.
 14. **Kristiansen B, Kofoed H.** External fixation of displaced fracture of the proximal humerus. Technique and preliminary results. *J Bone Joint Surg* 1987 ; 694-B : 643-646.
 15. **Kyle RF, Conner TN.** External fixation of the proximal humerus. *Orthopedics* 1988 ; 11 : 163-168.
 16. **Leyshon RL.** Closed treatment of fractures of the proximal humerus. *Acta Orthop Scand* 1984 ; 55 : 48-51.
 17. **Martin C, Guillen M, Lopez G.** Treatment of 2- and 3-part fractures of the proximal humerus using external fixation : A retrospective evaluation of 62 patients. *Acta Orthop* 2006 ; 77 : 215-278.
 18. **Naidu SH, Bixler B, Capo JT, Moulton MJ, Radin A.** Percutaneous pinning of proximal humerus fractures : a biomechanical study. *Orthopedics* 1997 ; 20 : 1073-1076.
 19. **Neer CS.** Displaced humeral fractures. *J Bone Joint Surg* 1970 ; 52-A : 1077-1089.
 20. **Neer II CS.** Part I : Fractures of the Shoulder. In Rockwood Jr CA, Green DP (eds), *Fractures in Adults*. 3rd ed, JB Lippincott, Philadelphia, 1991, pp 872-972.
 21. **Rowles DJ, McGrory JE.** Percutaneous pinning of the proximal part of the humerus. An anatomic study. *J Bone Joint Surg* 2001 ; 83-A : 1695-1699.
 22. **Siegel J, Dines D.** Proximal humerus malunions. *Orthop Clin North Am* 2000 ; 31 : 35-49.
 23. **Tingart M, Bathis H, Lefering R, Bouillon B, Tiling T.** [Constant Score and Neer Score. A comparison of score results and subjective patient satisfaction.] (in German) *Unfallchirurg* 2001 ; 104 : 1048-54.
 24. **Wijgman AJ, Roolker W, Pall TW, Raaymakers EL, Marti RK.** Open reduction and internal fixation of three and four-part fracture of the proximal part of the humerus. *J Bone Joint Surg* 2002 ; 84-A : 1919-1925.
 25. **Zyto K, Kronberg M, Brostrom LA.** Shoulder function after displaced fractures of the proximal humerus. *J Shoulder Elbow Surg* 1995 ; 4 : 331-336.