



## Adamantinoma

Panagiotis KITSOULIS, Antonia CHARCHANTI, Georgios PARASKEVAS, Aikaterini MARINI, Georgios KARATZIAS

*From the Laboratory of Anatomy-Histology-Embryology, Medical School, University of Ioannina, Greece*

Adamantinoma is one of the rarest low-grade malignant bone tumours, representing less than 1% of them. Fisher in 1913 named this tumour adamantinoma because of its similarity to ameloblastoma of the jaw. It usually arises in the center of long bones, and 97% of all reported cases were in long tubular bones and mainly in the tibial mid shaft (80-85%). Other long bones not uncommonly affected are the humerus, ulna, femur, fibula and radius. Ribs, spine, metatarsal and carpal bones are very rarely affected. The symptoms are not specific but most frequently the patient complains about swelling, redness, pain and sensitivity of the bone where the tumour is located. Young males are more prone to develop adamantinoma than females. The tumour usually spreads to the lungs, the regional lymph nodes, or other bones. Wide tumour excision and limb salvage reconstruction surgery, or an amputation, are the current surgical treatment options. Radiotherapy and chemotherapy have not been shown to be effective modalities of treatment.

**Keywords :** tumour ; adamantinoma ; osteofibrous dysplasia.

### INTRODUCTION

Adamantinoma of long bones is a rare, distinctive, and low-malignancy primary tumour of the appendicular skeleton. Its name is a mistake of the past as "adamantinoma" means an ameloblastoma-like tumour. Its exact origin is not yet known ; the classic form contains an epithelial and an osteofibrous component (17, 28). Adamantinoma may

appear in several osseous locations but the mid shaft of the tibia – affecting or not the fibula – is the commonest location.

In an attempt to find a specific cytogenetic profile of adamantinoma, the latest molecular and cytogenetic techniques were used. The results suggested that these tumours are consistent with epithelial or endothelial or synovial cells (7, 20, 37, 48, 49). According to Schajowicz *et al* (47) adamantinoma is a malignant or, at least, locally malignant tumour with a variety of histological patterns ; the most common is the one with circumscribed or tubular masses of epithelial cells in the middle of spindle-celled fibrous tissue.

### HISTORY

Although adamantinoma is an uncommon skeletal tumour, its origin has been a matter of debate for

- 
- Panagiotis Kitsoulis, MD, Orthopaedic Surgeon, Lecturer.
  - Antonia Charchanti, MD, Lecturer.
  - Georgios Paraskevas, MD, Lecturer.
  - Aikaterini Marini, MD Assistant in Anatomy.

*Department of Anatomy, Medical School, University of Ioannina, Ioannina, Greece.*

- Georgios Karatzias, MD, Otorhinolaryngologist.  
*General Hospital of Larissa, Thessaly, Greece.*

Correspondence : Panagiotis Kitsoulis, MD, Lecturer, Department of Anatomy-Histology-Embryology, Medical School, University of Ioannina, 21th October Street 28, 45332, Ioannina, Greece.

E-mail : pkitsoulis@hotmail.com.

© 2007, Acta Orthopædica Belgica.

---

more than seven decades. The first case of a primary bone tumour with epithelial characteristics is attributed to Maier (34) in 1900. In 1913, a German pathologist, Fischer (13), named this tumour "adamantinoma", because he noted that during embryonic development adamantine epithelium was found at the tibia as well as in the intraoral enamel. Many years later, Maier (34) referred to a tumour in the ulnar diaphysis of a young woman that had epidermoid characteristics, which raises the question how this could occur in a bone. Some researchers believed that adamantinoma has a double nature, being created by epithelial and spindle-cells elements, features suggesting a synovial sarcoma.

The first evidence for the origin of adamantinoma came from Changus *et al* (10) in 1957, who suggested that it could derive from vascular tissue. Llombart-Bosch and Ortuno-Pacheco (33) based on ultrastructural studies supported this theory.

These studies revealed that tumour cells have basement membranes, microvilli and tonofibrils forming the desmosomes which are indispensable for a cell-to-cell attachment.

Lately, investigators used immunohistochemistry to show that the cells of adamantinoma are keratin-positive, which proves an epithelial origin (44). Adamantinoma cells were also positive for alkaline phosphatase and had structures which were similar to Weber-Palade bodies, thereby suggesting an endothelial cell origin.

It was also noted that adamantinomas show immunochemical positivity for factor VIII antigens and vimentin (30).

### INCIDENCE

Adamantinoma is an extremely rare tumour representing 0.33-0.48% of primary malignant bone tumours. There is a prevalence of males over females, with a ratio of 5 to 4. Adamantinomas may appear at any age but in clinical practice the tumour appears in females between 11 and 30 years old and in males between 30 and 50 years of age (39, 53). Elderly individuals and children represent a minority of patients. Most (97%) of all the reported cases were in long tubular bones and mainly in

the tibial mid-shaft (80-85%) (3, 4). Other long bones not uncommonly affected are the humerus, ulna, femur, fibula and radius but ribs, spine, metatarsal and carpal bones are rare exceptions (41). Adamantinoma of long tubular bones shows a predilection for diaphyses, and it rarely forms more than one or two foci.

### CLINICAL FEATURES

Pain is thought to be the first symptom of a developing adamantinoma, sometimes co-existing with local swelling. Swelling is a more specific sign than pain because adamantinomas may be associated with repetitive trauma which is painful on its own (38, 42). Adamantinoma is a malignant tumour and may metastasize; although it is of low malignancy, metastases may be found in the diagnostic setup, usually in the lungs and the neighboring lymph nodes (50, 56).

### RADIOLOGIC FEATURES

The imaging of an adamantinoma is of importance in diagnosis (fig 1). Using roentgenography, adamantinoma appears as an eccentric, lobular, lytic lesion with poor or sharp delineation in the middle or distal third of the diaphysis or metaphysis of a long bone with some peripheral sclerosis. New bone formation may be also present. Furthermore, small radiolucent areas may be present around the main focus of the lesion. A periosteal reaction may be found but is usual only when a fracture exists in the same area. It is important to remember that lesions tend to appear in the tibia and not in the fibula. The characteristic "soap-bubble" picture is formed by radiolucent areas surrounded by ring-shaped dense areas (26, 29, 32, 43). Computed Tomography (CT) more accurately reveals the same osteolytic formation in the cortex of the bone, even in the soft tissues lying above. Magnetic Resonance Imaging (MRI), as a special technique for soft tissues, seems to be the gold standard examination for the differential diagnosis between adamantinoma, Ewing's sarcoma, fibrous bone dysplasia, osteosarcoma and metastatic carcinoma (4, 5, 14, 36, 46, 58).

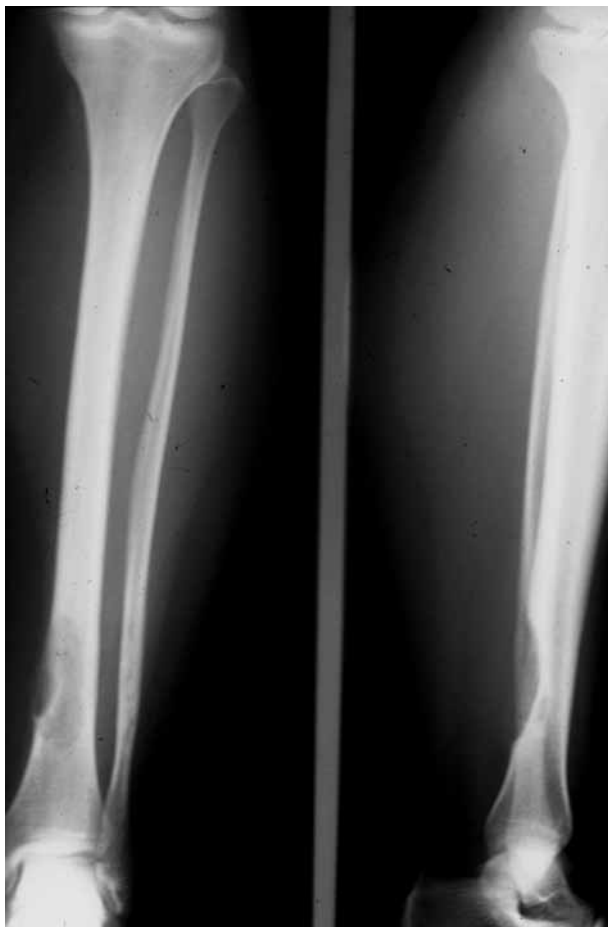

Fig. 1. — Radiologic features of adamantinoma

MRI may also reveal the exact location and volume of the tumour and clarify whether or not it has affected the surrounding soft tissues (53, 58).

Other general characteristics are its average length which is about 11 cm, as it has a longitudinal orientation, and the marked destruction of the bone medulla in contrast to ossifying fibroma which causes less damage. Additionally there is the chance of finding congenital pseudarthrosis of the tibia which leads the diagnosis to fibrous dysplasia rather than adamantinoma (1). In conclusion, it is important to use radiographs in order to diagnose an adamantinoma, and CT and MRI for the differential diagnosis, and to assess the aggressiveness and extension of the tumour.

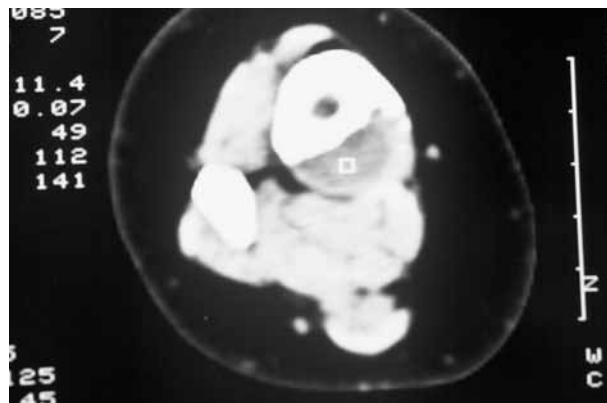


Fig. 2. — Computed Tomography

### HISTOPATHOLOGICAL FEATURES

Classic adamantinoma is composed of an epithelial and an osteofibrous component. These components may be intermingled in various proportions and following different patterns. The main histological patterns of classic adamantinoma include basaloid, tubular, spindle cell, and squamous patterns (40). The most common histological patterns are the basaloid and the tubular but all the main histological patterns may be encountered in one lesion.

The spindle cell component is more often encountered in recurrences, as well as in metastases. The osteofibrous component is composed of spindle cells showing a storiform pattern. Woven bone trabeculae are often observed in or next to the central area of the lesion, and varying amounts of transformation to lamellar bone at the periphery of the tumour. Foam cells or myxoid change may be encountered. A low number of mitoses is found. Another histological pattern, the so-called osteofibrous dysplasia-like variant, is composed mainly of osteofibrous tissue, in which small groups of epithelial cells are only observed by careful search or by using immunohistochemistry. Most classic and osteofibrous dysplasia-like adamantinomas show a “zonal” architecture (55). In classic adamantinoma, the central area is usually occupied by the epithelial component, with only a few small immature bone trabeculae present in the fibrous tissue. In osteofibrous dysplasia-like adamantinoma, the

central area is dominated by fibrous tissue with scanty and thin immature woven bone trabeculae with epithelial elements. Small groups of epithelial cells are the only features which help in the differential diagnosis between osteofibrous dysplasia-like adamantinoma and osteofibrous dysplasia.

### IMMUNOPHENOTYPIC FEATURES

The fibrous tissue shows immunohistochemical positivity for vimentin. The epithelial cells display co-expression of keratin, epithelial membrane antigen and vimentin. Epithelial cell cytokeratins 5, 14 and 19, which characterise basal cells, may be found in the epithelial cell component. In addition, cytokeratins 1, 13 and 17 are variably present. Cytokeratins 8 and 18 have not been detected. Expression of Epidermal Growth Factor and Epidermal Growth Factor receptor was found only in the epithelial component. Expression of Fibroblast Growth Factor and Fibroblast Growth Factor receptor was found in both components (6, 23, 27, 45).

### ULTRASTRUCTURAL FEATURES

Ultrastructural investigations have confirmed the epithelial nature of adamantinoma. The investigations revealed the presence of intracytoplasmic hemidesmosomes, tonofilaments and microfilaments. Regardless of histological subtype, the epithelial cells are bound by desmosomes and basement membranes have been detected around the groups of epithelial cells (33, 42, 43).

### GENETIC STUDIES

Classic and osteofibrous dysplasia-like adamantinomas display recurrent numerical chromosomal abnormalities, which include mainly a gain of chromosomes 7, 8, 12 and 19 (37). DNA flow cytometric and image cytometric studies demonstrated that in aneuploid tumours, the aneuploid population was always restricted to the epithelial component of the tumours (35, 51). Aberrations of the human suppressor gene p53 as detected by immunohistochemistry or by loss of heterozygosity

analysis are found in the epithelial component of adamantinoma. Some cases showing histological features of adamantinoma as well as Ewing sarcoma, sometimes called 'atypical' or 'Ewing-like adamantinoma' have been described (16, 20, 25, 34). Cytogenetic study using Fluorescent in situ Hybridisation and Reverse Transcription-polymerase chain reaction of two cases formerly described as atypical or Ewing-like adamantinoma demonstrated an (11;22) translocation, typical for Ewing sarcoma.

On the basis of these findings these tumours were named "adamantinoma-like Ewing sarcoma". The (11;22) translocation was not detected in adamantinoma (8).

### ORIGIN AND PATHOGENESIS

There are three basic theories with respect to the histogenesis of adamantinomas : 1. they are epithelial in origin (2, 15, 18, 57), 2. they derive from angioblasts (11, 12), 3. they are synovial tumours arising from ectopic sites (22, 32).

### TREATMENT

There is no widely accepted treatment for adamantinoma. It is generally believed that initial therapy is of critical importance and should begin with biopsy, avoiding curettage. The most popular methods are conservative surgical excision of the lesion and en-bloc excision which may include suspicious regional lymph nodes. When undertaking a radical en-bloc excision, an endoprosthesis will be required. There are many ways and methods in order to bridge the defect between the margins of the excised bone. Some of them are vascularised and non-vascularised bone grafts, custom made prostheses, intercalary allografts and more recently distraction osteogenesis (21, 24). The latter is a very reliable method and has a number of advantages as the new bone that is constructed has exactly the same biomechanical properties as the pre-existent bone (9). The healing time is less, unless the new bone fails to unite with the adjacent bones.

Furthermore, during this procedure, surgeons use an external fixator, which decreases the

likelihood of infections and is easily removable. Certainly the greatest advantage of this procedure is that the excision can be in normal bone margins, which decreases the probability of local recurrence that is very usual as adamantinoma is a genuinely multicentric tumour.

According to latest studies, the death incidence of adamantinoma ranges from 12% to 17% and the probability of metastasising comes up to approximately 20%.

### CONCLUSION

In conclusion, adamantinoma is a rare tumour of the long bones and belongs to the tumours with low malignancy. Histologically, it is formed of epithelial and mesenchymal cells but generally appears with a great variation in histologic types. The most common site of adamantinoma is the mid-shaft of the tibia and the shaft of other long bones. It usually metastasises to the lungs, to the neighbouring lymph nodes and to other bones. Radiotherapy and chemotherapy are not effective and the suggested treatment, especially of large defects without accompanying metastasis, is wide resection of the neoplasm. Bridging the defect that results from the resection is the most challenging problem. Various methods and techniques have been applied and encouraging outcomes have been reported. Some of them are vascularised and non-vascularised bone grafts, custom made prostheses, intercalary allografts and more recently, distraction osteogenesis, as well as amputation in some cases.

### REFERENCES

1. **Adler CP.** Case report 587 : adamantinoma of the tibia mimicking osteofibrous dysplasia. *Skeletal Radiol* 1990 ; 19 : 55-58.
2. **Baker PL, Dockerty MB, Coventry MB.** Adamantinoma (so-called) of the long bones ; review of the literature and report of three new cases. *J Bone Joint Surg* 1954 ; 36-A : 704-720.
3. **Bertoni F, Zucchi V, Mapelli S, Bacchini P.** Case report 506 : Adamantinoma of the soft tissues of leg. *Skeletal Radiol* 1988 ; 17 : 522-526.
4. **Bloem JL, van der Heul RO, Schuttevaer HM, Kuipers D.** Fibrous dysplasia vs adamantinoma of the tibia : differentiation based on discriminant analysis of clinical and plain film findings. *Am J Roentgenol* 1991 ; 156 : 1017-1023.
5. **Bohndorf K, Nidecker A, Mathias K et al.** [The radiologic findings in adamantinoma of the long tubular bones.] (in German). *Rofo Fortschr Geb Rontgenstrahl Neuen Bildgeb Verfahr* 1992 ; 157 : 239-244.
6. **Bovee JV, van den Broek LJ, de Boer WI, Hogendoorn PC.** Expression of growth factors and their receptors in adamantinoma of long bones and the implication for its histogenesis. *J Pathol* 1998 ; 184 : 24-30.
7. **Bridge JA, Dembinski A, DeBoer J et al.** Clonal chromosomal abnormalities in osteofibrous dysplasia. Implications for histopathogenesis and its relationship with adamantinoma. *Cancer* 1994 ; 73 : 1746-1752.
8. **Bridge JA, Fidler ME, Neff JR et al.** Adamantinoma-like Ewing's sarcoma : genomic confirmation, phenotypic drift. *Am J Surg Pathol* 1999 ; 23 : 159-165.
9. **Campanacci M, Giunti A, Bertoni F et al.** Adamantinoma of the long bones. The experience at the Istituto Ortopedico Rizzoli. *Am J Surg Pathol* 1981 ; 5 : 533-542.
10. **Changus GW, Speed JS, Stewart FW.** Malignant angioblastoma of bone ; a reappraisal of adamantinoma of long bone. *Cancer* 1957 ; 10 : 540-559.
11. **Elliott GB.** Malignant angioblastoma of long bone. So-called "tibial adamantinoma". *J Bone Joint Surg* 1962 ; 44-B : 25-33.
12. **Filippou DK, Papadopoulos V, Kiparidou E, Demertzis NT.** Adamantinoma of tibia : a case of late local recurrence along with lung metastases. *J Postgrad Med* 2003 ; 49 : 75-77.
13. **Fischer B.** Uber ein primäres Adamantinoma der Tibia. *Virchows Arch [B]* 1913 ; 12 : 422-441.
14. **Fukunaga M, Ushigome S.** Periosteal Ewing-like adamantinoma *Virchows Arch* 1998 ; 433 : 385-389.
15. **Hatori M, Watanabe M, Hosaka M et al.** A classic adamantinoma arising from osteofibrous dysplasia-like adamantinoma in the lower leg : a case report and review of the literature. *Tohoku J Exp Med* 2006 ; 209 : 53-59.
16. **Hauben E, van den Broek LC, Van Marck E, Hogendoorn PC.** Adamantinoma-like Ewing's sarcoma and Ewing's-like adamantinoma. The t (11;22), t (21;22) status. *J Pathol* 2001 ; 195 : 218-221.
17. **Hazelbag HM, Fleuren JG, Van den Broek LJ et al.** Adamantinoma of the long bones : keratin subclass immunoreactivity pattern with reference to its histogenesis. *Am J Surg Pathol* 1993 ; 17 : 1225-1233.
18. **Hazelbag HM, Fleuren GJ, Cornelisse CJ et al.** DNA aberrations in the epithelial cell component of adamantinoma of long bones. *Am J Pathol* 1995 ; 147 : 1770-1779.
19. **Hazelbag HM, Wessels JW, Mollevangers P et al.** Cytogenetic analysis of adamantinoma of long bones : further indications for a common histogenesis with osteofibrous dysplasia. *Cancer Genet Cytogenet* 1997 ; 97 : 5-11.

20. Hicks JD. Synovial sarcoma of the tibia. *J Pathol Bacteriol* 1954 ; 67 : 151-161.
21. Hoshi M, Matsumoto S, Manabe J *et al.* Surgical treatment for adamantinoma arising from the tibia. *J Orthop Sci* 2005 ; 10 : 665-670.
22. Huvos AG, Marcove RC. Adamantinoma of long bones. A clinicopathological study of fourteen cases with vascular origin suggested. *J Bone Joint Surg* 1975 ; 57-A : 148-154.
23. Ishida T, Iijima T, Kikuchi F *et al.* Clinicopathological and immunohistochemical study of osteofibrous dysplasia, differentiated adamantinoma, and adamantinoma of long bones. *Skeletal Radiol* 1992 ; 21 : 493-502.
24. Johansen S, Wennberg E. Adamantinoma tibiae : A report of a new case. *Acta Orthop Scand* 1980 ; 51 : 971-973.
25. Jundt G, Remberger K, Roessner A *et al.* Adamantinoma of long bones. A histopathological and immunohistochemical study of 23 cases. *Pathol Res Pract* 1995 ; 191 : 112-120.
26. Kahn LB. Adamantinoma, osteofibrous dysplasia and differentiated adamantinoma. *Skeletal Radiol* 2003 ; 32 : 245-258.
27. Kanamori M, Antonescu CR, Scott M *et al.* Extra copies of chromosomes 7, 8, 12, 19 and 21 are recurrent in adamantinoma. *J Mol Diagn* 2001 ; 3 : 16-21.
28. Knapp RH, Wick MR, Scheithauer BW *et al.* Adamantinoma of bone : An electron microscopic and immunohistochemical study. *Virchows Arch A Pathol Anat Histopathol* 1982 ; 398 : 75-86.
29. Kumar D, Mulligan ME, Levine AM, Dorfman HD. Classic adamantinoma in a three year-old. *Skeletal Radiol* 1998 ; 27 : 406-409.
30. Lederer H, Sinclair AJ. Malignant synovioma simulating "adamantinoma of the tibia". *J Pathol Bacteriol* 1959 ; 67 : 163-168.
31. Letourneau JG, Day DL, Crass JR *et al.* Adamantinoma involving the distal tibia and fibula. *Am J Roentgenol* 1987 ; 148 : 1043-1047.
32. Lipper S, Kahn LB. Case report 235. Ewing-like adamantinoma of the left radial head and neck. *Skeletal Radiol* 1983 ; 10 : 61-66.
33. Lombart-Bosch A, Ortuno-Pacheno G. Ultrastructural findings supporting the angioblastic nature of the so-called adamantinoma of the tibia. *Histopathology* 1978 ; 2 : 189-200.
34. Maier C. Ein primäres myelogenes platten Epithelcarcinom der Ulna. *Bruns Beitr Klin Chir* 1900 ; 26 : 553.
35. Mandahl N, Heim S, Rydholm A *et al.* Structural chromosome aberrations in an adamantinoma. *Cancer Genet Cytogenet* 1989 ; 42 : 187-190.
36. Meister P, Konrad E, Hubner G. Malignant tumour of humerus with features of "adamantinoma" and Ewing's sarcoma. *Pathol Res Pract* 1979 ; 166 : 112-122.
37. Mills SE, Rosai J. Adamantinoma of the pretibial soft tissue. Clinicopathologic features, differential diagnosis and possible relationship to intraosseous disease. *Am J Clin Pathol* 1985 ; 83 : 108-114.
38. Moon NF, Mori H. Adamantinoma of the appendicular skeleton – updated. *Clin Orthop* 1986 ; 204 : 215-237.
39. Mori H, Shima R, Nakanishi H *et al.* Adamantinoma of the tibia : a case report and a statistical review of reported cases. *Acta Pathol Jpn* 1981 ; 31 : 701-709.
40. Mori H, Yamamoto S, Hiramatsu K *et al.* Adamantinoma of the tibia. Ultrastructural and immunohistochemical study with reference to histogenesis. *Clin Orthop* 1984 ; 190 : 299-310.
41. Nerubay J, Chechick A, Horoszowski H, Engelberg S. Adamantinoma of the spine : A case report. *J Bone Joint Surg* 1988 ; 70-A : 467-469.
42. Pieterse AS, Smith PS, McClure J. Adamantinoma of long bones : clinical, pathological and ultrastructural features. *J Clin Pathol* 1982 ; 35 : 780-786.
43. Resnick D. Tumours and tumour-like lesions of bone : imaging and pathology of specific lesions. In : Resnick D (ed). *Diagnosis of Bone and Joint Disorders*, 3<sup>rd</sup> ed. Philadelphia : W.B. Saunders Co., 1995 ; pp 3882-3884.
44. Rosai J. Adamantinoma of the tibia. Electron microscopic evidence of its epithelial origin. *Am J Clin Pathol* 1969, 51 : 786-792.
45. Rosai J, Pinkus GS. Immunohistochemical demonstration of epithelial differentiation in adamantinoma of the tibia. *Am J Surg Pathol* 1982 ; 6 : 427-434.
46. Rosen RS, Schwinn CP. Adamantinoma of limb bone. Malignant angioblastoma. *Am J Roentgenol Radium Ther Nucl Med* 1966 ; 97 : 727-732.
47. Schajowicz F. Adamantinoma of long bones. In : Schajowicz F (ed). *Tumours and Tumour-Like Lesions of Bones and Joints*. Springer, New York, 1981, pp 384-391.
48. Schofield DE, Conrad EU, Liddell RM, Yunis EJ. An unusual round cell tumour of the tibia with granular cells. *Am J Surg Pathol* 1995 ; 19 : 596-603.
49. Sherman MG, Damron TA, Yang Yi. CD99 positive adamantinoma of the ulna with ipsilateral discrete osteofibrous dysplasia. *Clin Orthop* 2003 ; 408 : 256-261.
50. Soucacos PN, Hartofilakidis GK, Touliatos AS, Theodorou V. Adamantinoma of the olecranon : A report of a case with serial metastasizing lesions. *Clin Orthop* 1995 ; 310 : 194-199.
51. Sozzi G, Miozzo M, Di Palma S *et al.* Involvement of the region 13q14 in a patient with adamantinoma of the long bones. *Human Genet* 1990 ; 85 : 513-515.
52. Torriani M, Dertkigil SS, Etchebehere M, Amstalden EM. Magnetic resonance imaging of tibial classic adamantinoma at 2 tesla. *J Comput Assist Tomogr* 2002 ; 26 : 855-859.
53. Unni KK, Dahlin DC, Beabout JW, Ivins JC. Adamantinomas of long bones. *Cancer* 1974 ; 34 : 1796-1805.
54. Van Haelst UJ, de Haas van Dorsser AH. A perplexing malignant bone tumour. Highly malignant so-called

- adamantinoma or non-typical Ewing's sarcoma. *Virchows Arch Pathol Anat Histol* 1975 ; 365 : 63-74.
- 55. Vanhoenacker F, Van Ongeval C, Ceulemans R et al.** Adamantinoma of the tibia : MRI documentation. *J Belge Radiol* 1993 ; 76 : 154-156.
- 56. Weiss SW, Dorfman HD.** Adamantinoma of long bone. An analysis of nine new cases with emphasis on metastasizing lesions and fibrous dysplasia-like changes *Hum Pathol* 1977 ; 8 : 141-153.
- 57. Young JW, Aisner SC, Resnick CS et al.** Case report 660 : adamantinoma of tibia. *Skeletal Radiol* 1991 ; 20 : 152-156.
- 58. Zehr RJ, Recht MP, Bauer TW.** Adamantinoma. *Skeletal Radiol* 1995 ; 24 : 553-555.