

ARTHROSCOPIC SUBACROMIAL DECOMPRESSION FOR ADVANCED (STAGE II) IMPINGEMENT SYNDROME : A STUDY OF 52 PATIENTS WITH FIVE YEARS FOLLOW-UP

K. DOM¹, F. VAN GLABBEEK¹, R. P. VAN RIET¹, O. VERBORGT¹, F. L. WUYTS²

The authors report a prospective five-year follow-up study of 52 patients who had arthroscopic subacromial decompression for advanced (stage II : type 1 and 2) rotator cuff disease. All patients were assessed preoperatively, at six months and at five years postoperatively using the Constant-Murley score and the revised American Shoulder and Elbow Surgeons (ASES) score. From six months until five years postoperatively, 45 (out of 52) patients showed a further progressing improvement and relief of symptoms. This is established by a significant ($p < 0.001$) increase of the mean Constant-Murley score from 76.4 at six months postoperatively to 84.9 at five years postoperatively.

INTRODUCTION

Acromioplasty was popularised by Neer as the surgical treatment for chronic impingement syndrome, which is based on the belief that mechanical abutment of the rotator cuff between the rigid coraco-acromial arch above, and the humeral head below, is responsible for tendon attrition (1, 3, 21, 22). Several authors have reported favourable results with arthroscopic subacromial decompression for stage II impingement syndrome (3, 4, 10, 12, 18, 24, 25, 27, 35, 38, 40). Compared to open acromioplasty, arthroscopic subacromial decompression has many advantages (21, 23, 25, 32, 36, 38, 40). Patients treated arthroscopically returned more quickly to activities of daily living and work, regained flexion and strength more rapidly, had shorter hospitalisations and used less analgesics (36, 40, 44).

In contrast to Neer's strict mechanical theory, recent studies suggest that intrinsic factors and programmed cell death may play an equally important role in the pathogenesis of degenerative cuff tendinopathy (45). Also, Goldberg *et al* observed good function and improvement in comfort after cuff repair without acromioplasty (15).

The primary objective of this study was to analyse long-term (six months to 5 years) functional outcome after arthroscopic decompression for stage II disease. This was evaluated using the Constant-Murley score and the revised American Shoulder and Elbow Surgeons (ASES) score (6, 12, 30, 33). We hypothesise that dealing with the mechanical abutment of the rotator cuff by performing an acromioplasty results in improved functional outcome up to five years post-operatively and that this procedure remains the gold standard for the surgical treatment of advanced (stage II) impingement syndrome.

MATERIALS AND METHODS

Subacromial decompression for stage II rotator cuff disease, as classified by Neer (22), was performed in 52 patients, between September 1996 and May

¹ Department of Orthopaedics and Traumatology, University Hospital Antwerp.

² Department of Physics and Department of ENT, University of Antwerp.

Correspondence and reprints : K. Dom.

1997 (29). Patients were scored preoperatively, at six months and five years postoperatively, according to the rating system of the ASES and the Constant – Murley score (2, 6, 30). Only patients with an arthroscopically visualised impingement syndrome without a full-thickness rotator cuff tear were included in the study. Patients who had preoperative AC-joint tenderness, arthritis of the glenohumeral joint, cartilaginous loose bodies, instability of the shoulder, previous surgery and cervical spine disease were excluded from this study.

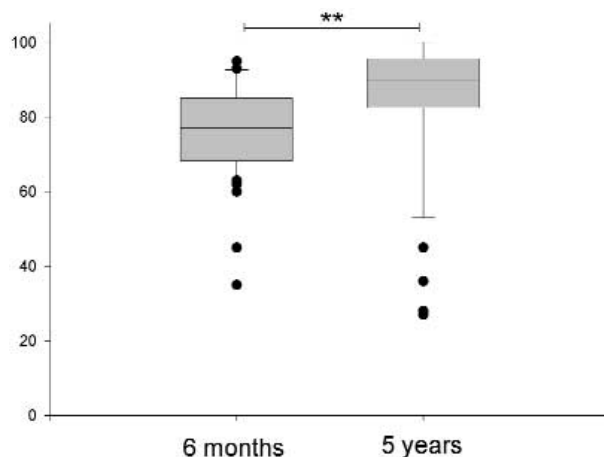
At clinical examination all 52 patients had a typical positive Neer and Hawkins test (22, 23, 41, 42) and continued to have pain with increasing intensity or frequency, before surgery.

Preoperative standard radiographs of the shoulder and an outlet view (3, 12) were taken and evaluated for presence of calcification. Calcifications within the rotator cuff were demonstrated in 15 cases. These were insertional calcifications of the degenerative type (type D) (20, 28, 31, 42). The acromial shape was evaluated according to Rockwood *et al* (3, 32, 35, 37). The acromial shape was noted to be type I in 12 cases, type II in 32 and type III in 8 cases.

Thirty women and 22 men with an average age of 52 years (range, 23 to 73 years) were included. The average duration of symptoms was 18.2 months (range, 3 months to 7 years). The dominant side was affected in 34 of the 52 patients (65%). Eleven patients (31%) showed a history of significant trauma, without residual glenohumeral instability.

All patients had been treated conservatively, including multiple periods of physiotherapy, anti-inflammatory medication and zero to seven steroid injections in the subacromial space, for at least six months (3). Acromioplasty was performed, transforming the undersurface of the acromion into a flat type I acromion. Spurs on the undersurface of the AC-joint were resected. Any downward protrusion of the acromioclavicular joint was also debrided. Coraco-acromial ligament release was accomplished by sectioning the anterior margin of the acromion rather than cutting the ligament itself. After the operation, the patient used a sling for comfort and followed a postoperative rehabilitation program described by Neer and several other authors (8, 10, 12, 21, 26, 27, 38).

The average duration of follow-up was 61.3 months (range, 57 to 65 months). ASES and Constant-Murley scores at 6 months and five years postoperatively were compared as well as the individual elements of this score to show the evolution over time. The Wilcoxon matched-pairs signed ranks test evaluated these scores.



** $p < 0.01$.

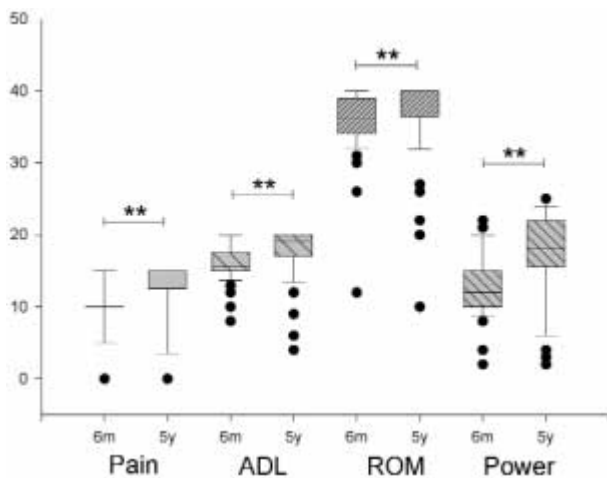
Fig. 1. — Boxplot showing Constant score six months and five years postoperatively. Upper and lower lines of the box show 75th and 25th percentiles respectively. Median values are shown by the middle line. Vertical bars show the 10th and 90th percentiles. Dots show individual outlying points.

RESULTS

The average postoperative Constant score at six months was 76.4 points (20). This improved to 84.9 points at five years postoperatively. This improvement is significant ($p < 0.001$) (fig 1). The Constant-Murley score at five years was excellent (91-100) for 25 patients, good (81-90) for 18 patients, fair (71-80) for two patients and poor for 7 patients.

The mean values (\pm standard error) of the individual components of the Constant score (pain, ADL, ROM and strength) all increased between 6 months and five years postoperatively (fig 2). The score for pain improved from 9.4 ± 0.5 to 12.6 ± 0.7 points ($p < 0.001$). Activities of daily living (ADL) improved from 15.9 ± 0.3 to 17.6 ± 0.5 ($p < 0.001$), range of motion improved from 35.5 ± 0.6 to 37.1 ± 0.8 ($p = 0.003$) and strength improved from 12.9 ± 0.6 to 17.4 ± 0.8 ($p < 0.001$).

The ASES score was 76.3 ± 2.2 at six months postoperatively and improved to 86.4 ± 2.5 at five years. The ASES score for pain improved from 2.8 ± 0.3 at six months postoperatively to 1.2 ± 0.3 at five years postoperatively ($p < 0.001$). The score for ADL activities improved from 23.1 ± 0.7 to 25.9 ± 1.0 ($p < 0.001$) (fig 3).



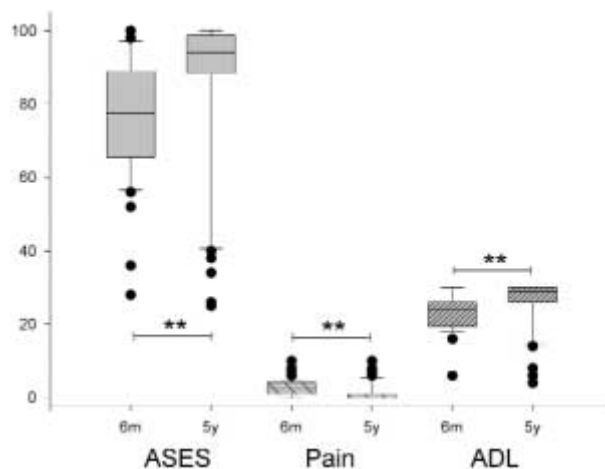
** $p < 0.01$.

Fig. 2. — Boxplot showing pain, ADL, ROM and power of the Constant score at six months and five years postoperatively. Upper and lower lines of the box show 75th and 25th percentiles respectively. Median values are shown by the middle line. Vertical bars show the 10th and 90th percentiles. Dots show individual outlying points.

DISCUSSION

This study clearly shows that after arthroscopic subacromial decompression for advanced (stage II) impingement syndrome 45 of 52 patients showed a continuing satisfactory improvement and relief of symptoms until five years postoperatively. The mean Constant-Murley score significantly increased from 76.4 at six months to 84.9 at five years postoperatively. The mean values of the individual components (pain, ADL, ROM and strength) of this score also showed significant increase from 6 months to five years postoperatively. The same trend was observed for the ASES score.

Arthroscopic acromioplasty is an efficient technique, which is better tolerated, especially in the early postoperative period (< 3 months), than open acromioplasty (18, 24, 25, 36). Moreover, the arthroscopic technique has the advantage to evaluate the extent, size and depth of a rotator cuff tear (11). Other advantages of the arthroscopic procedure include faster shoulder rehabilitation (25), better range of motion (25), shorter operative time (25), medical and economic advantages for patient and health care systems (36). After three months, open



** $p < 0.01$.

Fig. 3. — Boxplot showing modified ASES score at six months and five years postoperatively. Upper and lower lines of the box show 75th and 25th percentiles respectively. Median values are shown by the middle line. Vertical bars show the 10th and 90th percentiles. Dots show individual outlying points.

acromioplasty and arthroscopic acromioplasty have comparable results (19, 24, 40). Some authors will perform an open repair of the rotator cuff if more than 50% of the thickness of the cuff is torn (43) or if the arthroscopic debridement of the lesion failed (5, 40).

Despite multiple reports of successful results (3, 4, 10, 12, 18, 24, 25, 27, 35, 38, 40), some authors find the arthroscopic subacromial decompression procedure technically demanding with a long learning curve (5, 9, 12, 13, 16, 17, 35, 37). In order to facilitate the learning process some “tricks” have been proposed. Drawing the bony outlines of the clavicle, AC-joint, acromion and scapular spine once the patient is positioned is a prerequisite before the procedure is started (17). Hawkins uses the finger tip as an aid to evaluate the subacromial decompression in order to avoid unsatisfactory results as a consequence of inadequate decompression (16). Sampson (37) uses the “cutting-block” technique to make sure that enough bone is resected from the anterior acromial undersurface, using the posterior aspect as a cutting block guide. Although technically more demanding Gartsman has shown in an anatomical study on human cadavers that a

subacromial decompression can be performed with as much efficacy as an open procedure (14).

We included in our study the patients with type D insertional calcifications of the rotator cuff according to Mole *et al* (20), which are small, dense calcifications in continuity with the tuberosity. Also included were the patients with a clinically asymptomatic AC-joint having inferior osteophytes which were removed during the subacromial decompression procedure and were clearly involved in the impingement process (12, 13, 19).

Neither the aetiology of degenerative rotator cuff tendinopathy nor its natural history are fully understood. Several recent studies suggest that intrinsic factors, such as hypovascularity and programmed cell death may play an equally important role in the process of tendon degeneration (45). Moreover, Matsen *et al* showed in patients with open cuff repair that not performing an acromioplasty results in better comfort and functional improvement, hereby suggesting that acromioplasty is not necessary in the treatment of degenerative cuff tendinopathy (15).

The five year results shown in this study were excellent to good in most cases (83%). Seven patients scored a poor result. Of these, three patients (6%) had a partial tear of more than 50% of the thickness and developed a full thickness rotator cuff tear, requiring surgical repair. This finding is consistent with the literature, suggesting that partial tears with more than 50% involvement of the total thickness of the cuff should be surgically explored and repaired (7, 9, 39, 43).

The goal of this study was to compare our short-term (29) versus long-term results after arthroscopic subacromial decompression. No papers describe this evolution and only few studies with a similar long term follow-up and statistical power have been reported (34, 39, 43). On average, we found an ongoing improvement in shoulder function expressed by both the Constant-Murley and ASES scores. In other words, the five-year results show that, on average, improvement can still be expected six months after surgery and later on. Our study also demonstrated that decompression and debridement of a partial thickness rotator cuff tear (less than 50%) can give a good functional end result accor-

ding to the Constant (84.9) and ASES (86.4) scores after five years of follow-up. In the literature similar trends are found although with sometimes different scoring systems (9, 27, 34, 39, 43). In conclusion, this study suggests that functional improvement and comfort after arthroscopic subacromial decompression for advanced (stage II) impingement syndrome may still increase from 6 months up to five years postoperatively.

Acknowledgment

We would like to acknowledge the efforts of Prof. Dr. P. Van Schil in preparing the manuscript.

REFERENCES

1. Beach WR, Caspari RB. Arthroscopic management of rotator cuff disease. *Orthopedics* 1993 ; 16 : 1007-1015
2. Beaton DE, Richards RR. Measuring function of the shoulder. *J Bone Joint Surg* 1996 ; 78-A : 882-890
3. Bigliani LU, Levine WN. Current concepts review. Subacromial impingement syndrome. *J Bone Joint Surg* 1997 ; 79-A : 1854-1868
4. Caspari RB, Thal R. A technique for arthroscopic subacromial decompression. *Arthroscopy* 1992 ; 8 : 23-30
5. Checroun AJ, Dennis MG, Zuckerman JD. Open versus arthroscopic decompression for subacromial impingement. A comprehensive review of the literature from the last 25 years. *Bull Hosp Joint Disease* 1998 ; 57 : 145-151
6. Constant CR, Murley AH. A clinical method of functional assesment of the shoulder. *Clin Orthop* 1987 ; 214 : 160-164
7. Cordasco FA, Backer M, Craig EV, Klein D, Warren RF. The partial-thickness rotator cuff tear : Is acromioplasty without repair sufficient ? *Am J Sports Med* 2002 ; 30 : 257-260
8. Ellman H. Arthroscopic treatment of impingement of the shoulder. *Instructional Course Lectures* 1989 ; 38 : 177-185
9. Ellman H, Kay SP. Arthroscopic subacromial decompression for chronic impingement. Two- to five-year results. *J Bone Joint Surg* 1991 ; 73-B : 395-398
10. Esch JC, Ozerkis LR, Helgager JA, Kane N, Lilliot N. Arthroscopic subacromial decompression : results according to the degree of rotator cuff tear. *Arthroscopy* 1988 ; 4 : 241- 249
11. Gartsman GM. Arthroscopic management of rotator cuff disease. *J Am Acad Orthop Surg* 1998 ; 6 : 259-266
12. Gartsman GM. Arthroscopic acromioplasty for lesion of the rotator cuff. *J Bone Joint Surg* 1990 ; 72-A : 169-180
13. Gartsman GM. Arthroscopic treatment of rotator cuff disease. *J Shoulder Elbow Surg* 1995 ; 4 : 228-241

14. Gartsman GM, Blair ME, Noble PC, Bennett JB, Tullos HS. Arthroscopic subacromial decompression. An anatomical study. *Am J Sports Med* 1988 ; 16 : 48-50
15. Goldberg BA, Lippitt SB, Matsen FA. Improvement in comfort and function after cuff repair without acromioplasty. *Clin Orthop* 2001 ; 390 : 142-150
16. Hawkins RJ, Plancher KD, Sademmi SR, Brezenoff LS, Moor TJ. Arthroscopic subacromial decompression. *J Shoulder Elbow Surg* 2001 ; 10 : 225-230
17. Jonsson-Lillkrona U, Salomonsson B. Arthroscopic subacromial decompression (ASAD). In : *Surgical Techniques in Orthopaedics and Traumatology*. Editions Scientifiques et Médicales Elsevier, Paris, 2002, pp 55-190-C-10
18. Lindh N, Norlin R. Arthroscopic decompression versus open acromioplasty. A two-year follow-up study. *Clin Orthop* 1993 ; 290 : 174-176
19. Matthews LS, Blue JM. Arthroscopic subacromial decompression. Avoidance of complications and enhancement of results AAOS Instructional course lectures 1998 ; 47 : 29-33
20. Mole D, Kempf JF, Gleyze P, Rio B, Bonnet F, Walch G. Résultats du traitement arthroscopique des tendinopathies non rompues de la coiffe des rotateurs. 2^e partie : les calcifications de la coiffe des rotateurs. *Rev Chir Orthop* 1993 ; 79 : 532-541
21. Neer CS. Anterior acromioplasty for the chronic impingement syndrome in the shoulder. *J Bone Joint Surg* 1972 ; 54-A : 41-50
22. Neer CS. Impingement lesions. *Clin Orthop* 1983 ; 173 : 70-77
23. Neer CS, Marberry TA. On the disadvantages of radical acromioplasty. *J Bone Joint Surg* 1981, 63-A, 416-419
24. Neviasser TJ, Williams GR, Yamaguchi K, McCluskey G. Arthroscopic decompression of the shoulder. Instructional Course Lecture 429, AAOS 4-8 February 1999, Anaheim, USA
25. Norlin R. Arthroscopic subacromial decompression versus open acromioplasty. *Arthroscopy* 1989 ; 5 : 321-323
26. Nutton RW, McBirnie JM, Philips C. Treatment of chronic rotator-cuff impingement by arthroscopic subacromial decompression. *J Bone Joint Surg* 1997 ; 79-B : 73-76
27. Olsewski JM, Depew AD. Arthroscopic subacromial decompression and rotator cuff debridement for stage II and stage III impingement. *Arthroscopy* 1994 ; 10 : 61-68
28. Patte D, Goutallier D. Calcifications. *Rev Chir Orthop* 1988 ; 74 : 277-278
29. Petr  D, Verborgt O, Van Glabbeek F, Verstreken J. Treatment of advanced impingement syndrome by arthroscopic subacromial decompression. *Acta Orthop Belg* 1998 ; 3 : 257-262
30. Richards RR, An KN, Bigliani LU *et al.* A standardised method for assessment of shoulder function. *J Shoulder Elbow Surg* 1994 ; 3 : 347-352
31. Rochwerger A, Franceschi JP, Viton JM, Roux H, Mattei JP. Surgical management of calcific tendinitis of the shoulder : an analysis of 26 cases. *Clin Rheumatol* 1999, 18, 313-316
32. Rockwood CA, Lyons FR. Shoulder impingement syndrome : Diagnosis, radiographic evaluation and treatment with a modified Neer acromioplasty. *J Bone Joint Surg* 1993 ; 75-A : 409-422
33. Romeo AA, Bach BR, O'Halloran KL. Scoring systems for shoulder conditions. *Am J Sports Med* 1996 ; 24 : 472-473
34. Roye RP, Grana WA, Yates CK. Arthroscopic subacromial decompression : two- to seven-year follow-up. *Arthroscopy* 1995 ; 11 : 301-306
35. Ryu RK. Arthroscopic subacromial decompression : A clinical review. *Arthroscopy* 1992 ; 8 : 141-147
36. Sachs RA, Stone ML, Devine S. Open vs. arthroscopic acromioplasty : A prospective, randomized study. *Arthroscopy* 1994 ; 10 : 248-254
37. Sampson TG, Nisbet JK, Glick JM. Precision acromioplasty in arthroscopic subacromial decompression of the shoulder : Technical note. *Arthroscopy* 1991 ; 7 : 301-307
38. Speer KP, Lohnes PAC, Garret WE. Arthroscopic subacromial decompression : Results in advanced impingement syndrome. *Arthroscopy* 1991 ; 7 : 291-296
39. Stephens RS, Warren RF, Payne LZ, Wickiewicz TL, Altchek DW. Arthroscopic acromioplasty : a 6- to 10-year follow-up. *Arthroscopy* 1998 ; 14 : 382-388
40. Van Holsbeek E, DeRycke J, Declercq G, Martens M, Verstreken J, Fabry G. Subacromial impingement : Open versus arthroscopic decompression. *Arthroscopy* 1992 ; 8 : 173-178
41. Valadie III AL, Jobe CM, Pink MM, Ekman EF, Jobe FW. Anatomy of provocative tests for impingement syndrome of the shoulder. *J Shoulder Elbow Surg* 2000 ; 1 : 36-46
42. Walch G. Periarthritis of the shoulder. Symptomatology and classification. *Rev Chir Orthop* 1988 ; 74 : 279-281
43. Weber SC. Arthroscopic debridement and acromioplasty versus mini-open repair in the treatment of significant partial-thickness rotator cuff tears. *Arthroscopy* 1999 ; 15 : 126-131
44. Wilk EW, Andrews JR. Rehabilitation following arthroscopic subacromial decompression. *Orthopedics* 1993 ; 16 : 349-358
45. Yuan J, Murrell GAC, Wei AQ, Wang MX. Apoptosis in rotator cuff tendinopathy. Presented at : 47th Annual Meeting Orthopaedic Research Society, February 2001, San Francisco