



Kirschner wire migration causing spinal cord injury one year after internal fixation of a clavicle fracture

Patrick FRANSEN, Sylvie BOURGEOIS, Jacques ROMMENS

*From the Clinique du Parc Léopold, Brussels, Belgium and
the Hôpital de Braine l'Alleud-Waterloo, Braine L'Alleud, Belgium*

K-wire migration after internal fixation of the clavicle has rarely been reported to cause spinal cord injuries.

A 30-year-old man presented with progressive paraparesis, hypaesthesia under a Th4 level and electric pain in the neck and arms. CT of the spine revealed a migrated K-wire from a one-year-old clavicle osteosynthesis, penetrating the spinal canal through the Th2 nerve root foramen, and perforating the spinal cord with a transversal trajectory.

Surgical removal of the K-wire was performed after exposing both ends. Laminectomy allowed visual control of the entry point and correction of cerebrospinal fluid leakage. The pain disappeared and the patient recovered a normal gait after 6 weeks.

The use of two incisions is advocated in such cases : one lateral to allow wire removal, and one medial for dural repair and early intradural bleeding control. Regular follow ups, K-wire removal after fracture healing as well as bending the wire end in a walking stick shape should minimise the risk of migration

Keywords : K-wire migration ; clavicle fracture ; spinal cord injury.

INTRODUCTION

Migration of Kirschner wires (K-wires) used classically for clavicle osteosynthesis has occasionally been reported to cause injuries to the lungs (1, 2), the oesophagus (7) or to major vessels such as the brachiocephalic artery (7), the subclavian

artery (1) or the aorta (1, 4). Spinal cord injury is more uncommon and only three cases have been reported (3, 5, 6). We report the case of a patient with spinal cord injury caused by a migrated K-wire, one year after its initial implantation.

CASE REPORT

A 30-year-old man with a history of intravenous drug abuse currently controlled by oral methadone, presented with progressive weakness and numbness in the lower part of the body and electric pain in the neck and arms, increased by coughing. The symptoms had been developing over one month during which he had been examined in an emergency unit where his symptoms had been

■ Patrick Fransen, MD, Consultant in Neurosurgery.
Department of Neurosurgery, Clinique du Parc Léopold, Brussels, Belgium.

■ Sylvie Bourgeois, MD, Consultant in Neurology.
Department of Neurology, Hôpital de Braine l'Alleud-Waterloo, Braine L'Alleud, Belgium.

■ Jacques Rommens, MD, Consultant in Radiology.
Department of Radiology, Clinique du Parc Léopold, Brussels, Belgium.

Correspondence : Patrick Fransen, Centre Neurochirurgical de Bruxelles, Clinique du Parc Léopold, 38 rue Froissart, 1040 Brussels, Belgium. E-mail : p.fransen@neurobrussels.be.

© 2007, Acta Orthopædica Belgica.

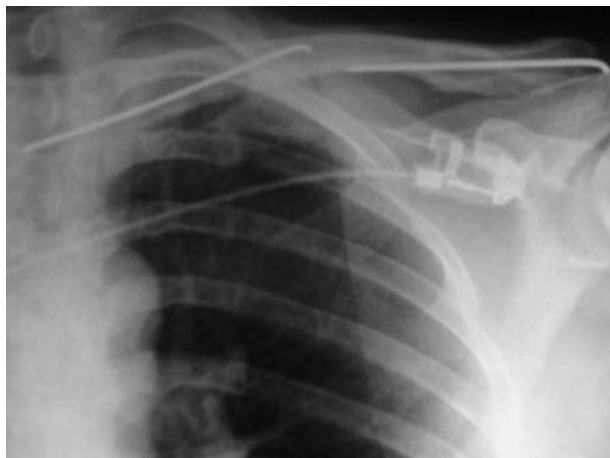

Fig. 1. — Chest radiograph, AP view. Note the migrated K-wire projecting in front of the spine, and its initial location with another K-wire still in place.

interpreted as drug withdrawal signs. Upon admission, his gait was limited to a few steps and was impossible without crutches.

Neurological examination showed a bilateral pyramidal syndrome, paraparesis, and hypaesthesia under a Th4 level. Somatosensory evoked potentials showed no identifiable cortical response after lower limbs stimulation. Chest radiograph (fig 1), confirmed by CT scanning of the upper thoracic spine (figs 2, 3), revealed a migrated K-wire penetrating the spinal canal through the Th2 nerve root foramen, and perforating the spinal cord with a transversal trajectory. A more thorough anamnesis revealed that the patient had undergone internal fixation of a clavicle fracture one year earlier. K-wires had been used to stabilise the fracture. A second K-wire was still in its original place in the clavicle. The clinical evolution had been uneventful since the operation.

Immediate surgical removal of the K wire was decided. First, a laminectomy of Th1 and Th2 allowed perfect exposure of the K-wire entry point into the dura. Under radiological control, the lateral end of the K-wire was exposed. Gentle traction on the wire allowed its complete removal (fig 4). Visual control of the entry point showed no intradural bleeding, but extensive CSF leakage

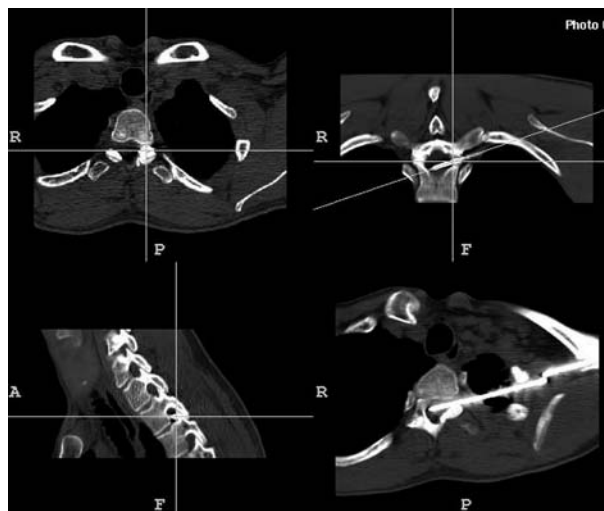


Fig. 2. — Thoracic spine CT scan : Transversal, lateral and oblique views showing the entry point of the K-wire into the dura and its transversal trajectory over the entire width of the spinal canal.

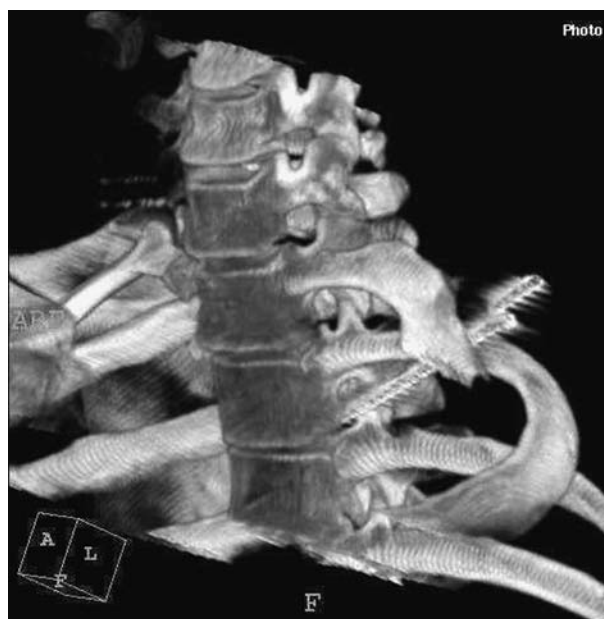

Fig. 3. — 3-D reconstruction showing the Kirschner wire trajectory and its entry point in the spinal canal (left scapula and part of the left first rib have been digitally removed).

which was immediately sealed with fibrin glue. The electric pain disappeared immediately after surgery and immediate physiotherapy was initiated. Six weeks after the operation, the patient had

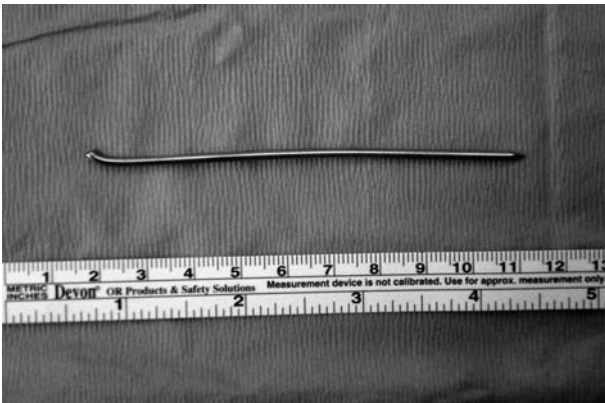


Fig. 4. — Kirschner wire after removal. Note that the migration may have been made possible by an insufficiently curved wire.

recovered a normal gait and only presented with moderate lower limbs hypoaesthesia. He returned to work 8 weeks after surgery.

DISCUSSION

The present case illustrates not only an uncommon complication of clavicle osteosynthesis, but from a technical point of view the great care that should be taken during removal of the wire from the spinal cord.

First, involvement of major blood vessels should be assessed preoperatively by CT scan or angiogram to avoid massive or fatal bleeding after removal of the wire. The lung and pleura should also be assessed.

During surgery, the wire should be pulled gently and along its axis. Lateral mobilisation of the wire should be avoided as it could cause more damage to the spinal cord. Removal of the wire should be done under permanent visual control. In this patient, the laminectomy performed over the wire area allowed immediate detection of a dural tear with CSF leakage, and its immediate sealing. In other similar cases, visual control would immedi-

ately show any intradural bleeding. This approach allows dural incision and early removal of intradural haematomas. For these reasons, we advocate the use of two incisions, one at the lateral end of the wire to allow a firm grip and to perform axial traction, and one at the medial end including a laminectomy to control its removal.

This uncommon complication also stresses the need for regular postoperative follow-up every two to four weeks after clavicle osteosynthesis, when K-wires are used. The patient should be informed about the risk of osteosynthesis material migration. The Kirschner wires should be removed as soon as bone healing is achieved, typically six weeks after surgery, unless radiological signs of nonunion are present. During internal fixation of the fracture, the distal end of the wire should be bent in a walking stick shape at least at a 90° angle to prevent migration.

REFERENCES

1. **Grauthoff H, Klammer HL.** Complications due to migration of a Kirschner wire from the clavicle. *Rofo* 1978 ; 125 : 591-594.
2. **Hegemann S, Kleining R, Schindler HG, Holthusen H.** Kirschner wire migration in the contralateral lung after osteosynthesis of a clavicular fracture. *Unfallchirurg* 2005 ; 108 : 991-993.
3. **Loncan LI, Semprer DF, Ajuria JE.** Brown-Sequard syndrome caused by a Kirschner wire as a complication of clavicular osteosynthesis. *Spinal Cord* 1998 ; 36 : 797-799.
4. **Nordback I, Markkula H.** Migration of Kirschner pin from clavicle into ascending aorta. *Acta Chir Scand* 1985 ; 151 : 177-179.
5. **Priban V, Toufar P.** A spinal cord injury caused by a migrating Kirschner wire following osteosynthesis of the clavicle : A case review. *Rozhl Chir* 2005 ; 84 : 373-375.
6. **Regel JP, Pospiech J, Aalders TA, Ruchholtz S.** Intraspinial migration of a Kirschner wire 3 months after clavicular fracture fixation. *Neurosurg Rev* 2002 ; 25 : 110-112.
7. **Wada S, Noguchi T, Hashimoto T et al.** Successful treatment of a patient with penetrating injury of the esophagus and brachiocephalic artery due to migration of Kirschner wires. *Ann Thorac Cardiovasc Surg* 2005 ; 11 : 313-315.