



## Glenoid osteolysis after arthroscopic labrum repair with a bioabsorbable suture anchor

Marco SPOLITI

From S. Camillo-Forlanini Hospital, Rome, Italy

**Bioabsorbable suture anchors are commonly used for arthroscopic repair of rotator cuff and labrum lesions. They provide soft-tissue attachment to bone. They have been introduced to avoid complications such as artefacts on MRI scans, commonly seen with metal anchors. However, bioabsorbable implants may lead to other problems such as local osteolysis, cyst formation, soft tissue inflammation and release of implant fragments into the joint space. The author describes the case of a professional female volleyball player, who presented osteolysis of the superior pole of the glenoid after arthroscopic repair of a SLAP lesion with a PLLA suture anchor. This is the first reported case of glenoid osteolysis after arthroscopic insertion of a bioabsorbable suture anchor. The author feels that the cause of osteolysis was a biological response to mechanical stress.**

**Keywords :** osteolysis ; SLAP lesion ; shoulder ; bioabsorbable ; suture anchor ; arthroscopy.

They produce minimal artefacts on MRI scans. They dissolve spontaneously and are replaced with bone (9), but they may also cause osteolysis, cyst formation, soft tissue inflammation and release of implant fragments into the joint space (4, 12, 18). Glueck *et al* (7) described a case of extensive osteolysis of the humeral head after rotator cuff repair with a PLDLA suture anchor. The authors describe the case of a patient who presented an excavation of the superior pole of the glenoid after arthroscopic repair of a SLAP lesion with a PLLA suture anchor. The patient was informed that his data would be submitted for publication and gave his agreement.

### CASE REPORT

In May 2002 a 25-year-old female competitive volleyball player presented with pain in the right shoulder since 4 months after a fall on the outstretched arm, especially at sports. She had a full range of motion. No signs of rotator cuff lesion

### INTRODUCTION

Many bioabsorbable implants are available for the treatment of rotator cuff and labral injuries. They consist of polylactic acid polymers (PLLA, PDLA and PDLLA) (15) and others. These implants have the same fixation strength as metal anchors.

---

■ Marco Spoliti, MD, Orthopaedic Surgeon.

S. Camillo-Forlanini Hospital, Rome, Italy.

Correspondence : Marco Spoliti, S; Camillo Forlanini Hospital, Rome, Italy.

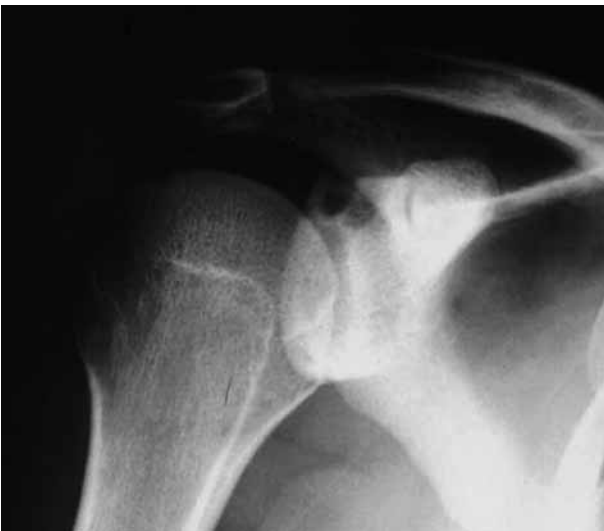E-mail : marcospoliti@tiscali.it.

© 2007, Acta Orthopædica Belgica.

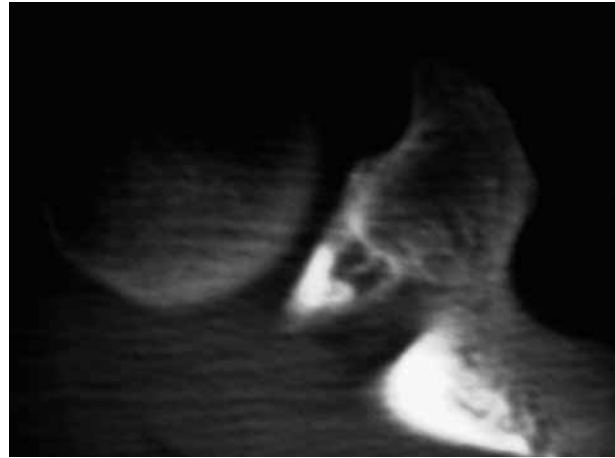
---

were found. There was no evidence of instability. The O'Brien test and the crank test were positive. Plain radiographs were practically normal. MRI scans showed a SLAP lesion.

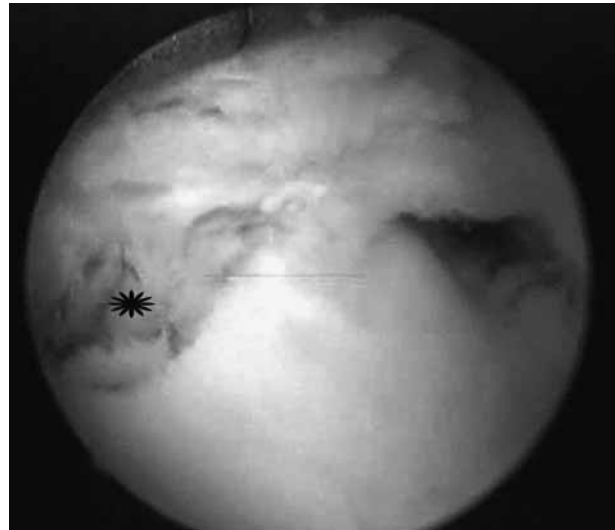Appropriate conservative therapy, including non-steroidal anti-inflammatory drugs, physiotherapy and rest, was started without result. Subsequently, the patient underwent an arthroscopy, which revealed a type II SLAP lesion. Arthroscopic repair was performed with a PLLA double loaded bioabsorbable suture anchor. The postoperative course was uneventful and the patient restarted playing volley 4 months after surgery. Eight months after the operation the shoulder pain recurred at sporting. The O'Brien test was again positive. Medication and physical therapy did not bring relief. Ten months after surgery radiographs and CT-scans showed a large lytic lesion in the superior pole of the glenoid in the area of the suture anchor (fig 1, 2). A second arthroscopy was then performed, 12 months after the first one. Partial failure of the repair was noted. The labrum and the sutures were debrided; a cavity was now seen in the superior pole of the glenoid in the area of the initial suture anchor (fig 3). This time a non-absorbable suture anchor was used for repair. Histologic examination of the tissue harvested



**Fig. 1.** — Antero-posterior radiograph with externally rotated arm showing osteolysis around the absorbable anchor positioned in the superior pole of the glenoid.



**Fig. 2.** — CT-scan : coronal view showing osteolysis of the glenoid.



**Fig. 3.** — Arthroscopic view of the superior pole of the glenoid, from a posterior portal, showing a bony hole (star).

from the bony defect in the superior pole of the glenoid showed a foreign body granuloma.

At follow-up, 6 months later, the patient was symptom free and there was no evidence of recurrence.

## DISCUSSION

Bioabsorbable anchors are commonly used in rotator cuff and labral arthroscopic repair, for soft-tissue attachment to bone. The use of bio-

absorbable implants has been introduced to avoid complications such as artefacts on MRI scans, commonly seen with metal anchors (1, 12, 18). Furthermore they facilitate revision surgery, help avoid the sequelae associated with permanent devices which can dislodge, and do not need to be removed (17). They consist of various polylactic acid polymers : PLDLA , PLLA and PDLA. The duration of the resorption process of the anchors is variable and depends on the polymer composition (3). It ranges from 6 months for PDLA anchors to 2 or 3 years for PLLA anchors (2, 16). Ideally, anchors will degrade, as soft tissue healing progresses, and gradually will allow more stress to be applied as the tissue can tolerate it (17). When considering the use of absorbable suture anchors it is very important to know the rate of healing response of the soft tissue to the bone, because it determines how rapidly the surgical construct can tolerate stress. In fact healing may not occur if fixation of the soft tissue to the bone is insecure (13, 14).

Bioabsorbable implants may lead to complications such as local osteolysis, cyst formation, soft tissue inflammation and release of implant fragments into the joint space (4, 12, 18). All these complications may compromise the outcome of repair. The literature provides ample information about failure of bioabsorbable devices used in the knee and the shoulder. Cummins *et al* (5) described migration of portions of a bioabsorbable screw into the subacromial space after rotator cuff repair. Freehill *et al* (6) reported synovitis due to PLLA tacks used for arthroscopic shoulder stabilization. Martinek *et al* (10) described a case of osteolytic tibial enlargement in association with pretibial cyst formation, after ACL reconstruction and PLDLA interference screw fixation. Müller *et al* (11) reported 7 cases of osteolysis after open anterior shoulder stabilization with PLDLL anchors. The author describes, for the first time in literature, a case of osteolysis of the superior pole of the glenoid after arthroscopic repair of a SLAP lesion with a PLLA suture anchor. A similar excavation of the glenoid was already described after open shoulder stabilization (11).

The cause of this osteolysis is not clear, but it has been interpreted by some authors as a foreign-body

reaction leading to loosening of the implant (6). Käab *et al* (8) considered other reasons for osteolysis, such as micromotion of the anchor due to the attachment of the ligaments and others, alteration of the implant due to production process or sterilization, and heat necrosis induced by drilling. It is possible that in the case reported here the anchor developed small microcracks due to stress, which speeded up the degradation of the polymer. In this way, decrease of pH of the surrounding tissues might have led to osteolysis and foreign body reaction. In other words, the osteolysis was a biological response to mechanical stress.

After all, many studies have demonstrated that bioabsorbable devices are a good option for the fixation of capsuloligamentous structures to bone. The low incidence of complications and the multiple advantages explain their extensive use in orthopaedic surgery (8, 17).

## REFERENCES

1. **Benedetto KP, Fellingner M, Lim TE *et al***. A new bioabsorbable interference screw : Preliminary results of a prospective, multicenter, randomized clinical trial. *Arthroscopy* 2000 ; 16 : 41-48.
2. **Bergsma JE, De Bruijn WC, Rozema FR, Bos RR, Boering G**. Late degradation tissue response to poly(L-lactide) bone plates and screws. *Biomaterials* 1995 ; 16 : 25-31.
3. **Bostman OM, Pihlajamäki HK**. Late foreign body reaction to an intraosseous bioabsorbable polylactic acid screw. *J Bone Joint Surg* 1998 ; 80-A : 1791-1794
4. **Burkhart SS**. Letter to the editor. *Am J Sports Med* 2005 ; 33 : 11.
5. **Cummins CA, Strickland S, Appleyard RC, Szomor ZL, Marshall J, Murrell GAC**. Rotator cuff repair with bioabsorbable screws : An in vivo and ex vivo investigation. *Arthroscopy* 2003 ; 19 : 239-248.
6. **Freehill MQ, Harms DJ, Huber SM, Atlihan D, Buss DD**. Poly-L-lactic acid tack synovitis after arthroscopic stabilization of the shoulder. *Am J Sports Med* 2003 ; 31 : 643-647.
7. **Glueck D, Wilson TC, Johnson DL**. Extensive osteolysis after rotator cuff repair with a bioabsorbable suture anchor : a case report. *Am J Sports Med* 2005 ; 33 : 742-744.
8. **Kaab MJ, Rahn BA, Weiler A, Curtis R, Perren SM, Schneider E**. Osseous integration of poly-(L-co-D/L-lactide) 70/30 and titanium suture anchors : an experimental

- study in sheep cancellous bone. *Injury* 2002 ; 33 suppl 2 : B37-B42.
9. **Kelly JD.** Disintegration of an absorbable rotator cuff anchor six weeks after implantation. *Arthroscopy* 2005 ; 21 : 495-497.
  10. **Martinek V, Seil R, Lattermann C, Watkins SC, Fu FH.** The fate of the poly-L-lactic acid screw after anterior cruciate ligament reconstruction. *Arthroscopy* 2001 ; 17 : 73-76.
  11. **Müller M, Kääh MJ, Villiger C, Holzach P.** Osteolysis after open shoulder stabilization using a new bioresorbable bone anchor : a prospective, non-randomized clinical trial. *Injury* 2002 ; 33 : 30-36.
  12. **McGuire DA, Barber FA, Elrod BF, Paulos LE.** Bioabsorbable interference screws for graft fixation in anterior cruciate ligament reconstruction. *Arthroscopy* 1999 ; 15 : 463-473.
  13. **Mc Farland EG, Park HB, Keyurapan E, Gill HS, Selhi S.** Suture anchors and tacks for shoulder surgery, Part 1. *Am J Sports Med* 2005 ; 33 : 1918-1923.
  14. **Meyer DC, Gerber C.** Failure of anterior shoulder instability repair caused by eyelet cutout of absorbable suture anchors. *Arthroscopy* 2004 ; 20 : 521-523.
  15. **Morgan CD, Gehrman RM, Jayo MJ, Johnson CS.** Histologic findings with a bioabsorbable anterior cruciate ligament interference screw explant after 2.5 years in vivo. *Arthroscopy* 2002 ; 18 : E47.
  16. **Stahelin AC, Weiler A, Rufenacht H, Hoffmann R, Geissmann A, Feinstein R.** Clinical degradation and biocompatibility of different bioabsorbable interference screws : a report of six cases. *Arthroscopy* 1997 ; 13 : 238-244.
  17. **Warne WJ, Arciero RA, Savoie FH 3rd, Uhorchak JM, Walton M.** Nonabsorbable versus absorbable suture anchors for open Bankart repair. A prospective, randomized comparison. *Am J Sports Med* 1999 ; 27 : 742-746.
  18. **Weiler A, Windhagen HJ, Raschke MJ et al.** Bio-degradable interference screw fixation exhibits pull-out force and stiffness similar to titanium screws. *Am J Sports Med* 1998 ; 26 : 119-127.