



Modified Essex-Lopresti / Westheus reduction for displaced intra-articular fractures of the calcaneus Description of surgical technique and early outcomes

Anand PILLAI, Prabhudeva BASAPPA, Stefan EHRENDORFER

From the Wishaw General Hospital, Lanarkshire, United Kingdom

We describe a modification of the classical Essex-Lopresti manoeuvre for the indirect reduction and stabilisation of displaced intra-articular fractures of the calcaneus. The radiological and functional results achieved using this technique in 15 patients is presented.

Ten tongue-shaped and 8 joint depression type fractures were treated by the new method, incorporating the use of an additional traction pin. The pre and postoperative Böhler angles as well as the correction achieved were documented. Functional assessment was carried out using the Maryland Foot Score.

The mean pre-operative Böhler angle in the joint depression group was 5.5 degrees, and in the tongue shaped fracture group 5 degrees. The mean post-operative Böhler angle in the joint depression group was 15.8 degrees, and in the tongue shape group was 23.25 degrees. At a mean follow-up of 28 months the joint depression group scored 51/100 on the foot score, and the tongue shaped fracture group 77/100. The mean correction achieved as well as the mean overall functional scores were significantly better in the tongue shaped group.

The technique described has much promise in the management of selected displaced intra-articular fractures of the calcaneus (true tongue shaped / Sanders II), and may also have a limited role in other fracture types in patients with significant comorbidities, soft tissue compromise and poor healing potential.

Keywords : calcaneus ; fracture ; ORIF ; foot ; trauma.

INTRODUCTION

Calcaneus fractures are the most common of all tarsal fractures (60%), and account for almost 2% of all adult fractures (16). Controversy still exists on the best form of treatment for these fractures. Historically most fractures were treated non operatively because open reduction and internal fixation was associated with high complication rates and did not result in significantly improved outcomes (1-5, 8, 12, 14, 19-21). With better understanding of fracture patterns and improved surgical and fixation techniques, there appears to be a renewed interest in the surgical treatment of displaced intra-articular fractures of the calcaneus (4, 5, 17, 24).

The technique of percutaneous indirect reduction and fixation of calcaneus fractures using an axial pin was first introduced by Westheus in 1934. The technique was further developed by Gissane, who designed a special spike and handle to facili-

-
- Anand Pillai, MS, MRCS, Specialist Registrar.
 - Prabhudeva Basappa, MS, MRCS, Senior House Officer.
 - Stefan Ehrendorfer, FRCS, Consultant.

Wishaw General Hospital, Lanarkshire, ML2 0DP, United Kingdom.

Correspondence : A. Pillai, 3/2. 63 Avenuepark Street
Glasgow, Scotland G20 8LN, United Kingdom.

E mail : Aorthopod@aol.com.

© 2007, Acta Orthopædica Belgica.

tate its use. The credit for describing the entire surgical technique in sequence and for the introduction of a shoe plaster to incorporate the pin and to hold the reduction goes to Essex-Lopresti (6). The technique has been further modified to include a full below-knee cast, percutaneous cancellous screws, and arthroscopically assisted methods (7, 9, 13, 18, 22, 23). The effectiveness of this technique in the restoration of Böhler's angle and calcaneal height in tongue shaped / Sanders type II fractures is well documented (22, 23).

We describe a modification of the classical Essex-Lopresti manoeuvre for the indirect reduction and stabilisation of displaced intra-articular fractures of the calcaneus and discuss the radiological and functional results achieved in a consecutive series of 15 patients.

MATERIALS AND METHODS

Fifteen patients with displaced intra-articular fractures of the calcaneus treated with the new technique described were prospectively followed-up. Open injuries and patients with associated fractures were not included in the study. Initial radiographic assessment of all patients included standardised anterior-posterior, lateral, and axial views of the calcaneus. Further evaluation was done in all cases by computerised tomography. All radiographic measurements were made on digitised films on Picture Archival Communications System (PACS (Siemens), Magic Web).

Fractures were classified according to the Essex-Lopresti system into tongue shaped (TS) and joint depression types (JD). All surgical procedures were carried out by the senior author (SE). Böhler's angle was measured preoperatively and post operatively, and the correction achieved was documented. All measurements were independently verified by all the authors. Radiographic follow-up was performed at 6 weeks, 12 weeks, 6 months and 12 months. Functional assessment was carried out using the Maryland Foot Score.

Surgical Technique

With the patient in the supine position, the affected limb was prepped and draped from the knee down. A 1-cm stab incision was made on the medial aspect of the calcaneus, just anterior to the insertion of the Achilles tendon. Blunt deep dissection was carried out carefully

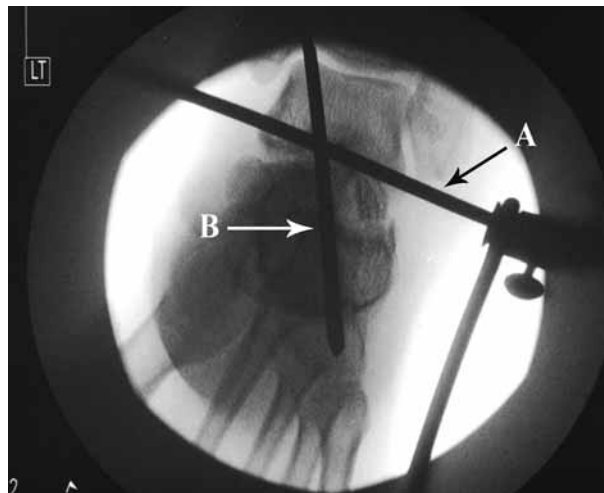


Fig. 1. — Intraoperative axial fluoroscopy view

avoiding tendons and neuro-vascular structures. A 4-mm Steinman pin was then introduced by hand from the medial wound and brought out laterally through another stab incision proximal and just anterior to the tendo Achillis insertion. The pin was attached and secured to a Böhler stirrup (fig 1). The leg was then flexed at the knee, and externally rotated at the hip into a figure of four- position, bringing the foot parallel to the surgical table. Longitudinal traction was then applied through the Bohler's stirrup in the line of the tibia, achieving an indirect reduction of the fracture. An assistant was required at this stage to apply counter-traction and to support the limb. The reduction could then be checked by a lateral view of the foot taken through the table by an image intensifier. If a radiolucent table is not available, then the foot can be hung off the side of the table with traction still applied by the stirrup in the figure of four- position. The reduction achieved was then stabilised by a second 4-mm Steinmann pin inserted using a power driver under fluoroscopic control from the postero/lateral aspect of the calcaneus (fig 2). For this a third stab incision was made below the insertion of the Achilles tendon, and the pin introduced into the major posterior fragment (posterior tuberosity fragment in tongue shaped fractures, and posterior body fragment in joint depression fractures), parallel with the lateral border of the calcaneus and into the cuboid across the calcaneocuboid joint. Further fine adjustments of the reduction were made if necessary by manipulating the fracture fragment directly with this pin, before it was passed into the cuboid. The heel was then compressed between the

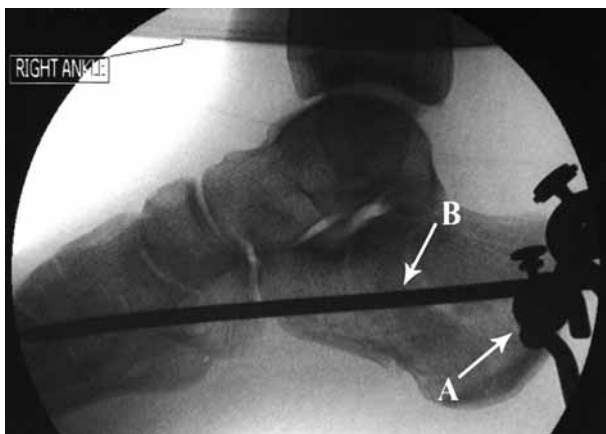


Fig. 2. — Intraoperative lateral fluoroscopy view

surgeon's palms to reduce any lateral wall displacement. The first Steinman pin along with the Bohler's stirrup was removed, and the second Steinman pin cut short outside the skin. Sterile dressings were applied and the pin was incorporated in a below-knee lightweight cast. AP, lateral and axial views were then taken to confirm and document the final position achieved. A non-inflated pneumatic tourniquet was routinely placed around the thigh, to be used if the procedure had to be converted to an open reduction.

The pin and cast were maintained for 6 weeks and the patient was kept non-weight bearing. The pins were routinely removed in the clinic with sedation. Following pin extraction, patients were referred to the physiotherapy department for foot and ankle mobilisation. Patients were maintained non-weight bearing for a total of ten weeks post-operatively. This was followed by gradual weight bearing as tolerated.

RESULTS

The study included 18 fractures in 15 patients (3 bilateral injuries). The mean age was 39.1 years (range : 19 to 63). There was a clear male predominance (M:F = 4:1). The most common mode of injury was a fall from a height (80%). Radiologically, 10 fractures were of the tongue type and 8 of the joint depression type. All patients underwent the procedure uneventfully. Only one patient developed superficial wound infection at the pin sites, which required oral antibiotics. There were no deep infections. Nine patients (60%) were

smokers (10 cigarettes or more per day), and all were advised to quit or to cut down, with varying levels of compliance. Two patients were insulin dependent diabetics. All patients retained their pins for 6 weeks, and none required any secondary surgical procedure.

The mean pre-operative Böhler angle in the joint depression group was 5.5 degrees (range : 0 to 20), and in the tongue shaped fracture group 5 degrees (range : 0 to 15). There was no statistically significant difference between the preoperative Bohler's angle measurement between the two groups ($p = 0.8719$ Mann-Whitney/Wilcoxon two sample test). The mean postoperative Böhler angle in the joint depression group was 15.8 degrees (range : 10 to 30). The mean postoperative Böhler angle in the tongue shape group was 23.25 degrees (range : 10 to 32). The mean correction achieved in the joint depression group was 10.5 degrees and in the tongue shaped group 19 degrees. The degree of correction achieved in the tongue shaped group was significantly better than in the joint depression group ($p = 0.0025$). There was no late collapse noted in any patient.

The mean duration of follow-up was 28 months (range : 24 to 48). All patients were available for final review. The mean Maryland Foot Score was 67.3/100, with 67% of patients achieving fair to excellent results. The mean functional score was 77 (42-87/100) for the tongue shaped group and 51 (42-73/100) for the joint depression group. The overall functional outcome in was significantly better in the tongue shaped group in comparison to the joint depression group ($p = 0.0027$). The final functional outcome correlated well with the post-operative Böhler angle achieved.

None of the patients in this series were on benefits or were involved in workers compensation claims.

DISCUSSION

The purpose of this paper is to describe a modified Essex-Lopresti / Westheus reduction technique for displaced intra-articular fractures of the calcaneus. The original technique requires the patient to be prone, and reduction is achieved by traction

applied to the talus by lifting the leg off the operating table with the knee flexed, and manoeuvring the fragment with a Gissane os calcis spike (6). The reduction is held by incorporating the spike in a plaster cast. Modifications of the original technique have been reported with the patient supine and also in the lateral positions (13).

There are several advantages to the technique we propose :

- 1) Supine position of the patient. Patients with calcaneal fractures may indeed have other associated injuries, the most common being fractures of the spine and the pelvis. In such patients achieving a prone or even lateral position may be difficult.
- 2) The figure of four- position makes imaging with a modern C-arm easy. If a radiolucent table is not available, then the foot can be simply brought over the edge of the table, or even made to rest on the C arm itself.
- 3) Traction is applied by means of a pin passed proximal to the os calcis, and no leverage is applied to the intraosseous pin. This may prevent loosening and pin site infection.
- 4) The technique allows the axial pin to be introduced by power under image guidance.
- 5) Advancing the pin into the cuboid, provides additional stability to the fixation.
- 6) The technique is suitable for use with cannulated cancellous screws.

Böhler's tuber joint angle is commonly assessed when evaluating calcaneal fractures. A severe heel fracture will result in significant decrease or loss of the angle. A number of studies clearly indicate that Böhler's angle is a good predictor of long term functional outcome in calcaneal fractures (4, 5, 15). Patients with angles less than 15 degrees did significantly worse than those with greater angles. This was the reason for choosing Böhler's angle as the measure of surgical reduction in our patients. In our group of patients, a mean correction of 10.5 degrees was achieved in the JD group and 19 degrees in the TS group. A mean post operative Böhler angle of greater than 15 degrees was achieved in both groups of patients. The plain radiograph fracture classification by Essex-Lopresti

based on the configuration of the secondary fracture line through the posterior facet, as used in our study was also found to be highly prognostic ($p = 0.035$) (4, 5).

Compared to open procedures, percutaneous reduction and fixation offers lower complication rates, shorter operating times and more rapid healing due to the undisturbed soft tissue envelope (1, 8, 11). For carefully selected patients, this technique provides good results comparable with open reduction and internal fixation. Ten out of 15 patients in our series were either smokers or diabetics, who would be considered high risk for open reduction and internal fixation (4, 5). The overall infection rate in our series is only 6%, and we did not encounter any additional complications in this vulnerable group.

Eighty percent (12 patients) of our patients were male and 40% (6 patients) were involved in heavy manual work. Both factors are considered to lead to poor outcomes after open fixation.

The scope of percutaneous techniques for the treatment of intra-articular fractures of the calcaneus is limited. The goals of this approach are to improve the alignment of the calcaneus and reduction of the posterior facet. In tongue-shaped fractures, the posterior articular facet is contiguous with the posterior tuberosity. Direct manipulation of the facet is possible by traction and a pin inserted into the posterior tuberosity. This allows the fracture to be reduced accurately percutaneously (10). In joint depression type, the posterior articular facet is depressed, rotated and often impacted into the posterior body fragment. Since direct manipulation of the facet is not possible, by a pin inserted into the posterior body fragment, it becomes difficult to achieve an accurate reduction by this technique (10). Our results thus support earlier observations that the percutaneous technique is best suited for tongue shaped fractures (22, 23). The mean correction achieved as well as the mean overall functional scores were significantly better in this group. However, our results clearly show that a correction of the Böhler angle was achieved in both tongue shaped and joint depression types of fractures by the technique described. The addition of a second traction pin allows greater forces to be

applied across the subtalar joint to disimpact the fracture fragments. Also passing the pin past the calcaneo-cuboid joint affords greater stability to the fixation. Hence we must disagree with previous reports that the method is suitable only for tongue shaped calcaneal fractures.

Deciding how to manage a displaced intra-articular fracture of the calcaneus is challenging. Assessment of the fracture, patient status, and functional needs are paramount in dictating treatment. Although our report is only from a single unit, and involves a relatively small number of patients, we feel that the technique described has much promise in the management of selected displaced intra-articular fractures (true tongue shaped / Sanders II) and may also have a limited role in other fracture types in patients with significant co-morbidities, soft tissue compromise and poor healing. However the technique allows only limited exposure and control of fracture fragments, and if anatomical reduction is sought then open reduction should be preferred.

REFERENCES

1. **Abidi NA, Dhawan S, Gruen GS et al.** Wound healing risk factors after open reduction and internal fixation of calcaneal fractures. *Foot Ankle Int* 1998 ; 19 : 856-861.
2. **Bridgeman SA, Dunn KM, McBride DJ, Richards PJ.** Interventions for treating calcaneal fractures. *Cochrane Database Syst Rev* 2002 ; 2 : CD001161.
3. **Buckley RE, Meek RN.** Comparison of open vs. closed reduction of intraarticular calcaneal fractures : a matched cohort in workmen. *J Orthop Trauma* 1992 ; 6 : 216-222.
4. **Buckley R, Tough S, McCormack R et al.** Operative compared with non operative treatment of displaced intra-articular calcaneal fractures. A prospective, randomised, controlled multicenter trial. *J Bone Joint Surg* 2002 ; 84-A : 1733-1744.
5. **Buckley R, Tough S.** Displaced intra-articular calcaneal fractures. *J Am Acad Orthop Surg* 2004 ; 12 : 172-178.
6. **Essex-Lopresti P.** The mechanism, reduction technique, and results in fractures of the os calcis. *Br J Surg* 1952 ; 39 : 395-419.
7. **Fernandez DL, Koella C.** Combined percutaneous and "mimimal" internal fixation displaced articular fractures of the calcaneus. *Clin Orthop* 1993 ; 290 : 108-116.
8. **Folk JW, Starr AJ, Early JS.** Early wound complications of operative treatment of calcaneus fractures : analysis of 190 fractures. *J Orthop Trauma* 1999 ; 13 : 369-372.
9. **Gavlik JM, Rammelt S, Zwipp H.** Percutaneous, arthroscopically-assisted osteosynthesis of calcaneus fractures. *Arch Orthop Trauma Surg* 2002 ; 122 : 424-428.
10. **Hammesfahr R, Fleming L.** Calcaneal fractures : A good prognosis. *Foot Ankle* 1981 ; 2 : 161-171.
11. **Howard JL, Buckley R, McCormack R et al.** Complications following management of displaced intraarticular calcaneal fractures. A prospective randomised trial comparing open reduction internal fixation with non operative management. *J Orthop Trauma* 2003 ; 17 : 241-249.
12. **Jarvholm U, Komer L, Thoren O, Wildund LM.** Fractures of the calcaneus. A comparison of open and closed treatment. *Acta Orthop Scand* 1984 ; 55 : 652-656.
13. **King RE.** Axial pin fixation of fractures of the os calcis (Method of Essex-Lopresti). *Orthop Clin N Am* 1973 ; 4 : 185-188.
14. **Kundel K, Funk E, Brutscher M, Bickel R.** Calcaneal fractures : operative versus non-operative treatment. *J Trauma* 1996 ; 41 : 839-845.
15. **Loucks C, Buckley R.** Böhler's angle : correlation with outcome in displaced intraarticular calcaneal fractures. *J Orthop Trauma* 1999 ; 13 : 554-558.
16. **Nicklebur S, Dixon TB, Probe R.** Calcaneus fractures. EMedicine, July 21, 2004. <http://www.emedicine.com/orthoped/topic33.htm>.
17. **Palmer I.** The mechanism and treatment of fractures of the calcaneus. Open reduction with the use of cancellous grafts. *J Bone Joint Surg* 1948 ; 30-A : 2-8.
18. **Rammelt S, Amlang M, Barthel S, Zwipp H.** Minimally-invasive treatment of calcaneal fractures. *Injury* 2004 ; 35 Suppl 2 : SB55-63.
19. **Randle JA, Kreder HJ, Stephan D et al.** Should calcaneal fractures be treated surgically ? A meta analysis. *Clin Orthop* 2002 ; 377 : 217-227.
20. **Thermann H, Krettek C, Hufner T et al.** Management of calcaneal fractures in adults. Conservative versus operative treatment. *Clin Orthop* 1998 ; 353 : 107-124.
21. **Thordarson DB, Krieger LE.** Operative vs. non operative treatment of intraarticular fractures of the calcaneus : a prospective randomised trial. *Foot Ankle Int* 1996 ; 17 : 2-9.
22. **Tornetta P 3rd.** Essex-Lopresti reduction for calcaneal fractures revisited. *J Orthop Trauma* 1998 ; 12 : 469-473.
23. **Tornetta P 3rd.** Percutaneous treatment of calcaneal fractures. *Clin Orthop* 2000 ; 375 : 91-96.
24. **Zwipp H, Tscherne H, Thermann H, Weber T.** Osteosynthesis of displaced intraarticular fractures of the calcaneus. Results in 123 cases. *Clin Orthop* 1993 ; 290 : 76-86.