



Influence of labral tears on the outcome of acetabular augmentation procedures in adult dysplastic hips Prospective assessment with a minimum follow-up of 12 years

Julien GIRARD, Kristina SPRINGER, Donatien BOCQUET, Anne COTTEN, Antoine DUQUENNOY, Henri MIGAUD

From the Hôpital Roger Salengro, CHU Lille, Lille, France

Lesions of the acetabular labrum have been suspected to be one factor responsible for failures of Chiari osteotomy. We undertook a prospective investigation to address this question. Twenty-six adult patients (mean age 34.5 years) with 26 dysplastic hips were enrolled consecutively. All the hips studied showed arthritic changes. The labrum was inspected by arthroscopy during surgery (19 shelf acetabuloplasties and 7 Chiari procedures). All hips were followed for a minimum of 12 years (12-14 years).

Sixteen dysplastic hips (62%) were found to have labrum tears. Computed tomography (CT)-arthrography findings were similar to arthroscopic observations in 13 hips. Coxometry results showed that the acetabular roof angle (HTE), cervico-diaphyseal angle (CDA) and lateralisation were higher in cases with acetabular labral tears. On the other hand, the ventral center-edge angle (VCEA) was lower in hips with labral tears. During the follow-up period, eight hips which had undergone a Chiari osteotomy were converted to total hip replacement.

Adult dysplastic hips are at risk for presenting labral tears. Clinical signs appear to have limited diagnostic value. Coxa valga, a small lateral center edge angle and a high acetabular roof angle were found in this study to be associated with a higher incidence of labral tears. Contrary to previous data reported in retrospective studies, the results of the present prospective investigation suggest that labral tears do not compromise the outcome of acetabulum enlargement procedures.

Keywords : hip dysplasia ; labral tears ; acetabular augmentation.

INTRODUCTION

The clinical signs of acetabular labral tears were described by Klaue *et al* (13) and Fitzgerald (6) in the early 1990s. These specific clinical tests were promoted to diagnose labral tears, but the value of the data was not assessed in prospective, controlled clinical studies. Likewise, labrum lesions have been suspected to be a factor in failure of Chiari osteotomy (1, 22) ; this was however postulated on the basis of retrospective studies. To answer these questions, a prospective investigation was conducted, and the results are reported here. The goals of the present study were : to assess the reliability of

-
- Julien Girard, MD, Staff Orthopaedic Surgeon.
 - Kristina Springer, MD, Resident.
 - Donatien Bocquet, MD, Resident.
 - Anne Cotten, MD, Professor of Radiology.
 - Antoine Duquenooy, MD, Professor of Orthopaedic Surgery.
 - Henri Migaud, MD, Professor of Orthopaedic Surgery.
- Centre Hospitalier Universitaire de Lille, Hôpital Roger Salengro, Service d'Orthopédie C, 59037 Lille Cedex, France.
Correspondence : Julien Girard, Orthopaedic Department, Centre Hospitalier Universitaire de Lille, Hôpital Roger Salengro, Service d'Orthopédie C, 59037 Lille Cedex, France.
E-mail : j_girard_lille@yahoo.fr.
© 2007, Acta Orthopædica Belgica.
-

clinical and computed tomography (CT)-arthrography signs in diagnosing acetabular labrum tears ; to determine the frequency of labral tears and the radiographic features of dysplastic hips at high risk for labrum lesions ; and to establish, after a minimum follow-up of 12 years, whether labral tears have any effect on the outcome of acetabular enlargement procedures.

PATIENTS AND METHODS

Twenty-six adult patients (average age : 34.8 years (range, 20-59) with 26 dysplastic hips (Lateral center-edge angle (LCEA) $< 20^\circ$ in all cases with femoral dysplasia (cervico diaphyseal angle (CDA) $> 140^\circ$) in 17 cases) were enrolled consecutively between April 1991 and May 1993 in a prospective clinical trial. The inclusion criteria were : adult age and surgical indication for augmentation (Chiari (1) or hip shelf arthroplasty (15)) procedures for acetabular hip dysplasia (LCEA $< 20^\circ$) with or without arthritis.

A complete hip exploration was performed with plain radiography and CT-arthrography preoperatively, and hip arthroscopy during surgical correction of hip dysplasia. The augmentation procedure was hip shelf acetabuloplasty in 19 cases (when LCEA $> 0^\circ$) and Chiari osteotomy in 7 cases (when LCEA $\leq 0^\circ$) (20).

Hip arthroscopy, undertaken to assess the labrum during surgical correction of dysplasia (19), was performed via two portals (lateral and antero-lateral) on all the patients in the supine position. Hip distraction was confirmed by fluoroscopy. Labrum tears were noted by location and type (9). Their diagnosis and anatomic topography were based on arthroscopic visualisation in four areas (antero-superior, antero-inferior, postero-superior and postero-inferior). The torn portion of the labrum was excised under arthroscopic control.

Clinical acetabular dysplasia before the onset of osteoarthritis leads to distinct symptoms (6). The clinical presentation of labral tears in acetabular dysplasia, called acetabular rim syndrome, was assessed by Klaue *et al* (13). Five clinical signs were investigated : 1) giving way, 2) hip locking, 3) hip clicking, 4) pain caused by passive flexion-adduction-internal rotation, 5) pain caused by hyperextension-external rotation. One point was given for each sign observed (range 0 to 5 points).

Radiographic evaluation consisted of antero-posterior view, false hip profile, conventional arthrography and CT-arthrography. Several radiological measurements were made : lateral center-edge angle (LCEA) (25),

acetabular roof angle (HTE) (18), cervico-diaphyseal angle (CDA), ventral center-edge angle (VCEA) (16) and hip lateralisation, assessed by the distance between the medial aspect of the femoral head and the teardrop. These were analyzed by a musculoskeletal radiologist and a surgeon. Arthrosis was classified according to de Mourgues and Patte's criteria (3) (Grade 1 : no sign of arthrosis ; Grade 2 : bone cyst or sclerosis without joint space narrowing ; Grade 3 : less than 50% joint space narrowing ; and Grade 4 : more than 50% joint space narrowing).

Continuous variables were assessed by simple regression analysis and ANOVA. Non-parametric tests (Mann-Whitney or Wilcoxon, or F-test) were performed when the samples were small. Differences were considered significant when the probability value was less than 0.05. Survival analysis was undertaken according to Kaplan-Meier (11), using conversion to total hip replacement (THR) as the endpoint. Survival rates were compared by the log rank test. Survival rates are given with 95% confidence intervals.

RESULTS

No patient was lost to follow-up, but 2 died from unrelated causes during follow-up : one died 5 years after the index procedure (hip shelf) without THR conversion, and the other died from breast cancer dissemination 4 years after the index procedure (hip shelf was converted to THR because of pathological fracture of the femoral neck). All of the remaining 24 hips were followed for a minimum of 12 years (range, 12-14).

Pre-operatively, all hips presented arthritic changes (table I) : Grade 2 in 10 hips and loss of joint space in 16 hips (9 Grade 3 and 7 Grade 4).

At arthroscopic labral assessment, 16 dysplastic hips had labral tears (62%), which were mainly located at the superior aspect of the labrum (69%). The lesion type was : 1 ulcer, 8 degenerative and 7 bucket-handle tears. Clinical labral symptoms were observed more often in hips without labrum tears ($p < 0.05$). In fact, the specific clinical labral score was 2.3 ± 0.8 points (1-4) for hips without labral tears and 1.4 ± 1.5 points (0-5) in hips with labral tear.

The value of CT-arthrography for labral tear diagnosis was excellent (fig 1). Indeed, the CT-

Table I. — Arthritic changes noted in radiographs of dysplastic hips with or without labral tears

	Labral tear (n = 16)	Labrum intact (n = 10)
Grade 2 Bone densification (n = 10)	7	3
Grade 3 Joint space narrowing < 50% (n = 9)	5	4
Grade 4 Joint space narrowing > 50% (n = 7)	4	3

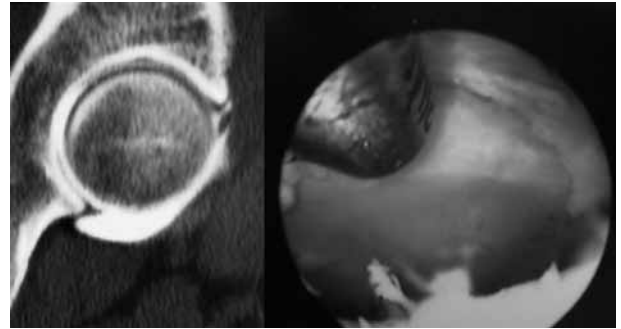


Fig. 1. — CT-arthrography findings were similar to arthroscopic observations in 81% of cases. In this particular case, CT-arthrography shows a degenerative labral tear discovered by hip arthroscopy.

Table II. — Preoperative radiographic factors predictive of labral tears

	Labrum+	Labrum-	p
LCEA (°)	4.6 ± 10	10.2 ± 8.6	NS
HTEA (°)	26.2 ± 5.7	19 ± 7.2	p = 0.01
VCEA (°)	3.3 ± 14	12.1 ± 10.2	p = 0.05
CDA (°)	140 ± 4.6	133 ± 5.5	p = 0.03
Head-U index (lateralisation in mm)	18 ± 4.6	14 ± 3.2	p = 0.05

LCEA : lateral center-edge angle ; VCEA : ventral center-edge angle ; HTEA : acetabular roof angle ; CDA : cervico-diaphyseal angle.

arthrography findings were similar to the intraoperative findings in 13/16 hips (81%). CT-arthrography underestimated the severity of labrum tears in 3 cases. There were no false positives with CT-arthrography.

Preoperative radiological features forecasting labral tears are summarized in table II. Preoperative radiological findings were predictive of labral tears. HTE and CDA were higher in labral tear cases ($p < 0.05$). On the other hand, LCEA was lower in hips affected by labral tears ($p < 0.05$). Hip lateralisation was higher in labral tear cases ($p < 0.05$). After the index procedure, all hips had LCEA and VCEA angles greater than or equal to 25°.

At follow-up, 8 hips had been converted to THR : 2 out of 10 hips (20%) with no labral tear at the time of surgery, and 6 out of 16 hips (37.5%) with labral tears. This difference was not significant ($p = 0.42$). The indication for THR conversion was groin pain associated with global space joint narrowing in all cases. THR conversion was neces-

sary after a mean time period of 9.3 years (range 4 to 11 years). Of the 8 conversions, 6 were in patients with a hip shelf procedure, and 2 in patients with Chiari osteotomy. The difference was not significant ($p = 0.8$).

At 150 months, the Kaplan-Meier survival rate (with THR conversion as an endpoint) was 80% (0.80 ± 0.13) (95% confidence interval) for hips without labral tears, and 62.5% (0.625 ± 0.12) (95% confidence interval) for hips with labral tear (fig 2). The difference was not statistically significant ($p = 0.4$).

There was no difference in the severity of preoperative osteoarthritis in hips with or without labrum tears ($p = 0.67$). Three THR conversions occurred in Grade 2 hips, 2 in Grade 3, and 3 in Grade 4.

DISCUSSION

Chiari osteotomy and shelf acetabuloplasty aim at improving femoral head coverage in dysplastic

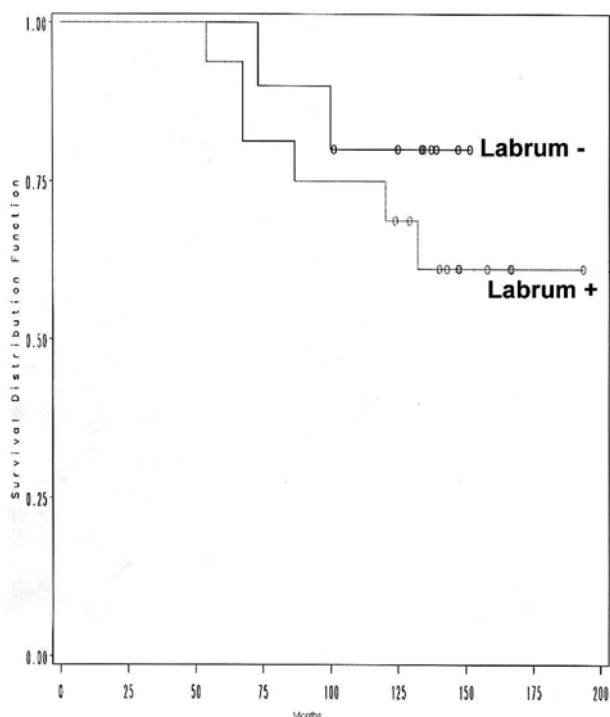


Fig. 2. — Kaplan-Meier survival in months (with THR conversion as the endpoint) for hips with or without labral tears ($p = 0.4$).

hips (1, 5, 15). The focus is on restoration of hip biomechanics and prevention of early-onset osteoarthritis (5). As these surgical techniques are extra-articular, labral lesions can be ignored during an isolated osteotomy. Ilizaliturri *et al* (10) found labral lesions in all their arthroscopic cases, in dysplastic hips previously treated by Chiari osteotomy. Fibrous cartilage was found at the osteotomy place in only 30% of cases; in other cases, the femoral head was exposed down to bone in the joint line. Many authors contend that the medialised acetabular rim leaves the labrum in the center of the load-bearing area (10, 14). Acetabular overload creates mechanical labral damage and, in association with cartilage lesions, leads to early osteoarthritis (4).

Detachment of the labrum, the first step towards osteoarthritis, has been suggested to be a cause of failure after Chiari osteotomy (22). In our study, pre-existing labral lesions appeared to be present at surgery in 62% of dysplastic hips. The association between labral lesions and hip dysplasia or bony

hip abnormality is well documented and varies from 30% (13) to 87% (24). The loss of congruity between the femoral head and the acetabulum leads to rapidly-progressing osteoarthritis, and the only solution to prevent this degeneration is to resect the damaged labrum and to perform an acetabular osteotomy (4). With both these actions, acetabular overload seems to be controlled without the re-emergence of labral lesions and arthritis progression. We did not find any correlation between the presence of labral tears at surgery and later osteoarthritis.

According to Nishina *et al* (22), Chiari pelvic osteotomy with an untreated labral tear has a poor clinical outcome and is associated with 50% clinical failure. These data confirm that labral tearing (or a detached labrum) is the most important factor influencing clinical outcome. As discussed by Yamamoto *et al* (26), our results showed that clinical groin symptoms disappeared after arthroscopic treatment of the labral lesion.

In our study, we found that THR conversion occurred in 3 Grade 2 hips at an average of 8.8 years. THR conversion in Grade 4 hips was necessary at an average of 4.6 years. Our study found no correlation between the presence of labral tears and the progression of osteoarthritis severity (8, 22). On the other hand, Klaue *et al* (14) cautioned that surgical treatment of labral tears in dysplastic hips could lead to early osteoarthritis. Our study shows that with longer follow-up there is no correlation between the presence and the treatment of labral tears and progression of osteoarthritis.

Hip snapping, clicking and locking are common symptoms of the “acetabular rim syndrome” described by Klaue *et al* (13). They seem to be secondary to overload of the acetabular rim, and are exacerbated by hip flexion with adduction and internal rotation. True locking of the hip is a pathognomonic sign of labral tearing (7). According to many authors, painful clicking seems to be associated with a detached labrum (6, 13, 17, 22). These clinical tests to diagnose labral tears were never assessed in a prospective manner. In our study, we did not find any correlation between these specific signs and the presence of labral tears. In fact,

symptoms classically attributed to labral tears in dysplastic hips may manifest in various areas (the greater trochanteric area or the groin) in association with a feeling of instability or stretching of the abductors (6, 7). The number and variability of clinical signs which have been attributed to labral tears could explain the poor specificity of clinical examination.

In our study, CT-arthrography demonstrated excellent sensitivity (81%) for labral tear in correlation with an intra-operative diagnosis. Simple arthrography is interesting as it gives an immediate response to local anaesthetic injection and shows labral tears with 88% sensitivity (6). Magnetic resonance imaging (MRI) of the hip, which is a non-invasive method, can identify labral tears with accuracy similar to MR-arthrography (21, 23). In fact, the sensitivity of labral lesion detection correlated with surgical observation was reported to be 95% for MRI (21) and 71% (12) to 91% (2) for MR-arthrography. Furthermore, MR-arthrography showed a specificity of 44% (12) to 71% (2). In fact, despite the high power of labral lesion detection, all these imaging studies revealed that negative imaging does not exclude real intra-articular pathologies (12).

We noted radiological risk factors for labral tears in dysplastic hips. Coxa valga, a low VCE angle, a high THE angle and a marked hip lateralisation seem to increase the risk of labral tears. However, one should consider that, contrary to other radiological data on bone dysplasia, hip lateralisation could be secondary to the instability created by labral lesions.

CONCLUSION

In this study, labral tears were found by arthroscopy in two-thirds of adult dysplastic hips with radiological signs of osteoarthritis. Clinical signs of labral tears, as described in the literature, appeared to be of limited diagnostic value. CT-arthrography appeared as a reliable tool for the pre-operative diagnosis of labral tears. Coxa valga, a low ventral center-edge angle (VCE) and a high acetabular roof angle (THE) appeared to be associated with a higher incidence of labral tears. There

was no difference in the severity of preoperative osteoarthritis in hips with or without labrum tears. Unlike previous retrospective studies, the current prospective investigation suggests that the presence of labral tears does not negatively influence the outcome of acetabulum enlargement procedures. Surgical correction of the hip dysplasia by an extra-articular acetabular osteotomy associated with treatment of an existing labral tear however appears to be a good approach.

REFERENCES

1. Chiari K. Medial displacement osteotomy of the pelvis. *Clin Orthop* 1974 ; 98 : 55-71.
2. Czerny C, Hofmann S, Urban M *et al.* MR arthrography of the adult acetabular capsular-labral complex : Correlation with surgery and anatomy. *AJR Am J Roentgenol* 1999 ; 173 : 345-349.
3. de Mourgues G. [Results of a 10-year experience with osteotomy of the femur neck in mild secondary coxarthrosis in the adult. Indication for varization osteotomy]. (French) *Rev Chir Orthop* 1978 ; 64 : 525-605.
4. Dorrell JH, Catterall A. The torn acetabular labrum. *J Bone Joint Surg* 1986 ; 68-B : 400-403.
5. Fawzy E, Mandellos G, De Steiger R *et al.* Is there a place for shelf acetabuloplasty in the management of adult acetabular dysplasia ? A survivorship study. *J Bone Joint Surg* 2005 ; 87-B : 1197-1202.
6. Fitzgerald RH Jr. Acetabular labrum tears. Diagnosis and treatment. *Clin Orthop* 1995 ; 311 : 60-68.
7. Garbuz DS, Masri BA, Haddad F *et al.* Clinical and radiographic assessment of the young adult with symptomatic hip dysplasia. *Clin Orthop* 2004 ; 418 : 18-22.
8. Hasewaga Y, Iwata H, Mizuno M *et al.* The natural course of osteoarthritis of the hip due to subluxation or acetabular dysplasia. *Arch Orthop Trauma Surg* 1992 ; 111 : 187-191.
9. Ide T, Hokari Y. Arthroscopic findings of labrum. *J Joint Surg* 1994 ; 13 : 317-326.
10. Ilizaliturri VM Jr., Chaidez PA, Valero FS *et al.* Hip arthroscopy after previous acetabular osteotomy for developmental dysplasia of the hip. *Arthroscopy* 2005 ; 21 : 176-181.
11. Kaplan E, Meier P. Non parametric estimation from incomplete observation. *J Am Stat Assoc* 1958 ; 53 : 457-481.
12. Keeney JA, Peelle MW, Jackson J *et al.* Magnetic resonance arthrography versus arthroscopy in the evaluation of articular hip pathology. *Clin Orthop* 2004 ; 429 : 163-169.
13. Klauw K, Durnin CW, Ganz R. The acetabular rim syndrome. A clinical presentation of dysplasia of the hip. *J Bone Joint Surg* 1991 ; 73-B : 423-429.

14. **Klaue K, Sherman M, Perren SM et al.** Extra-articular augmentation for residual hip dysplasia. Radiological assessment after Chiari osteotomies and shelf procedures. *J Bone Joint Surg* 1993 ; 75-B : 750-754.
15. **Lance C.** [Constitution of an osteoplastic shelf in congenital dislocation and subluxation of the hip]. (French) *Presse Med* 1925 ; 33 : 945-948.
16. **Lequesne M, de Seze S.** [The false profile of the pelvis. A new radiologic view for the study of the hip. Its value in dysplasias and various hip pathologies]. (French). *Rev Rhumat* 1961 ; 28 : 643-652.
17. **Leunig M, Podeszwa D, Beck M et al.** Magnetic resonance arthrography of labral disorders in hips with dysplasia and impingement. *Clin Orthop* 2004 ; 418 : 74-80.
18. **Massie WK, Howorth MB.** Congenital dislocation of the hip. Part I. Method of grading results. *J Bone Joint Surg* 1950 ; 32-A : 519-531.
19. **McCarthy J, Noble P, Schuck M, Aluisio F, Wright J, Lee J-A.** Acetabular and labral pathology. In : McCarthy JC (ed). *Early Hip Disorders. Advances in Detection and Minimally Invasive Treatment*. Springer, New York, 2003, pp 113-133.
20. **Migaud H, Chantelot C, Giraud F et al.** Long-term survivorship of hip shelf arthroplasty and Chiari osteotomy in adults. *Clin Orthop* 2004 ; 418 : 81-86.
21. **Mintz DN, Hooper T, Connell D et al.** Magnetic resonance imaging of the hip : detection of labral and chondral abnormalities using noncontrast imaging. *Arthroscopy* 2005 ; 21 : 385-393.
22. **Nishina T, Saito S, Ohzono K et al.** Chiari pelvic osteotomy for osteoarthritis. The influence of the torn and detached acetabular labrum. *J Bone Joint Surg* 1990 ; 72-B : 765-769.
23. **Troum OM, Crues JV, 3rd.** The young adult with hip pain : diagnosis and medical treatment, circa 2004. *Clin Orthop* 2004 ; 418 : 9-17.
24. **Wenger DE, Kendell KR, Miner MR et al.** Acetabular labral tears rarely occur in the absence of bony abnormalities. *Clin Orthop* 2004 ; 426 : 145-150.
25. **Wiberg G.** Shelf operation in congenital dysplasia of the acetabulum and in subluxation and dislocation of the hip. *J Bone Joint Surg* 1953 ; 35-A : 65-80.
26. **Yamamoto Y, Ide T, Nakamura M et al.** Arthroscopic partial limbectomy in hip joints with acetabular hypoplasia. *Arthroscopy* 2005 ; 21 : 586-591.