



## A technique for accurate and safe injection of steroid in trigger digits using ultrasound guidance

Shashi Kanth GODEY, Waqar A. BHATTI, James S. WATSON, Ardeshir BAYAT

*From South Manchester University Hospitals*

**Steroid injections have long been the main stay of conservative treatment of trigger digits. This procedure gives variable results, which is dependent on a number of factors. The injection of the steroid in the right place improves the success rate and also prevents complications associated with the procedure. We describe a technique using ultrasound for accurate injection of steroid to maximise its beneficial effects in treatment of trigger digits.**

**Keywords :** trigger finger ; steroid injection ; ultrasound guidance.

Stenosing tenosynovitis of the fingers and thumb is a common upper extremity problem. The cause of this condition remains uncertain. It causes symptoms, ranging from mild discomfort and stiffness to a painful finger that becomes locked in flexion. The treatment options vary from splintage, steroid injection to surgical release of the pulley. The main stay of conservative treatment is injection of steroid into the tendon sheath. Nonetheless, reported results are variable and can be disappointing with fewer than 50% of the patients gaining long-term relief of symptoms. The aim of the injection treatment is to instill steroid with or without local anaesthetic into the lumen of the tendon sheath and around the A1 pulley. Kamhin *et al* showed that the injection reaches this point in only 49% of the cases (1). More recently, better results have been reported when particular attention has been paid to

the injection technique with cure rates of up to 84% (2). There are complications associated with invasive treatment of trigger fingers which include infection and digital nerve damage. Steroid injection appears to be more successful in a semi acute setting and less useful in more advanced cases. The relative resistance of long-standing tenosynovitis to steroid injection may be explained by the occurrence of fibrocartilaginous metaplasia within the A1 pulley.

We report the use of ultrasound-guided injection of steroid for trigger finger. The procedure is done in an outpatient setting. Following initial localisation using an ultrasound (fig 1), 0.5 ml of 1%

---

■ Shashi Kanth Godey, MBBS, MS (Ortho), MRCSed, MRCSI, Senior House Officer in Plastic Surgery.

■ James Stewart Watson, MRCP, FRCS, Consultant Plastic Surgeon.

■ Ardeshir Bayat, MRCS, PhD Specialist Registrar/MRC Clinician Scientist.

*Department of Plastic and Reconstructive Surgery, South Manchester.*

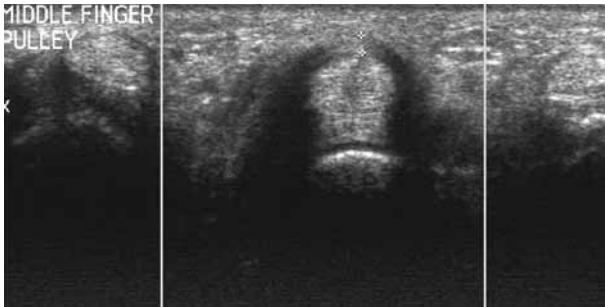
*University Hospitals NHS Trust, Wythenshawe, Manchester, United Kingdom.*

■ Waqar A. Bhatti, FRCR Consultant Radiologist.  
*Department of Radiology, South Manchester University Hospitals NHS Trust, United Kingdom.*

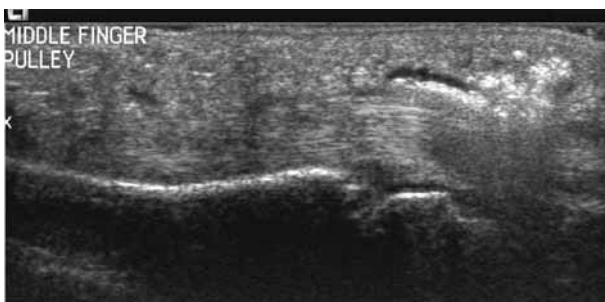Correspondence : Shashi Kanth Godey, 32, Arley House, 1, Amberly Drive, Manchester M23 2RP, United Kingdom.

E mail : shashikanthg@yahoo.com.

© 2006, Acta Orthopædica Belgica.

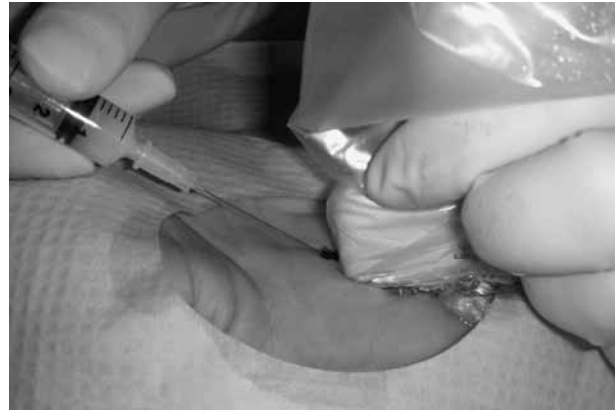

**Fig. 1.** — Thickened A1 pulley over the flexor sheath



**Fig. 2.** — Showing the site of steroid injection around the flexor sheath in the region of the A1 pulley.

Xylocaine is injected subcutaneously. The patient is further assessed by ultrasound and a suitable entry point is marked. Skin is prepared with Chlorhexidine or Betadine. The area is isolated with a holed drape and further procedure carried under strict aseptic conditions. A 27-gauge needle is used. The surgeon, under further ultrasound guidance advances the needle to check its position with respect to the sheath and the A1 pulley (fig 2). When the needle is placed correctly within the



**Fig. 3.** — Steroid injection under ultrasound guidance after localising the entry point.

sheath, the steroid is injected (fig 3). The correct placement of the needle ensures accurate delivery of steroid into the flexor sheath around the tendon and A1 pulley which is further confirmed on the ultrasound. The patient is further assessed in the clinic 6 weeks and 6 months later to assess the results of the injection.

We propose that with more accurate placement of the needle and delivery of the steroid at the right place we aim to achieve good response rate and reduce the complication rate in comparison with the blind technique which is traditionally followed.

## REFERENCES

1. **Kamhin M, Engel J, Heim M.** The fate of injected trigger fingers. *Hand* 1983 ; 15 : 218-220.
2. **Marks MR, Gunther SF.** Efficacy of cortisone injection in treatment of trigger fingers and thumbs. *J Hand Surg* 1989 ; 14-A : 722-727.