

CASE REPORT

PACINIAN CORPUSCLES HYPERPLASIA – AN UNCOMMON CAUSE OF DIGITAL PAIN

A. KUMAR, A. J. DARBY, C. P. KELLY

The authors present two cases of hyperplasia of Pacinian corpuscles, one in the hand and another in the foot. In the hand the corpuscles were located along the radial border of the pulp of the little finger and presented with localised sharp pain. In the foot, it presented as metatarsalgia in association with Morton's neuroma of the second web space. Both patients underwent exploration and excision of the lesion with complete resolution of symptoms.

INTRODUCTION

Pacinian "neuromas" (hyperplasia) are rare lesions of unknown aetiology. In 1998, Reznik *et al* were able to review 29 reported cases in the hand and added a further two cases of their own (6). Pacinian neuromas of the foot are even more uncommon. We report another two cases. Case 1 is unusual because of its distal location in the pulp of the finger. Case 2 was associated with a Morton's neuroma.

CASE STUDIES

Case 1

A 32-year-old male patient had a six months' history of spontaneous onset of sharp pain along the radial border of the pulp of the left little finger. There was no recent or remote history of trauma. On examination, there was pinpoint tenderness on the radial side of the pulp of the left little finger. There was no palpable mass and the overlying skin was normal. The digit had full range of movements

at the interphalangeal joints with normal sensation and vascularity.

Owing to persistent and incapacitating symptoms the tender area was explored. A multinodular mass $0.8 \times 0.3 \times 0.2$ cm. was found attached to the branching digital nerve (fig 1). Microscopic examination showed a small nerve surrounded by Pacinian corpuscles and a diagnosis of Pacinian "neuroma" was made. Postoperatively, the patient had normal sensation with complete resolution of symptoms.

Case 2

A 65-year-old lady presented with a six months' history of a painful left foot. She had sharp radiating pain along the adjacent sides of the second and third toes, particularly worse on standing and walking. On examination there was tenderness between the heads of the second and third metatarsals and on applying pressure, pain radiated into the toes. A clinical diagnosis of Morton's neuroma was made and she was initially treated conservatively. However, due to persistent symptoms, the second web space was explored through a dorsal incision. A lump of fibro-fatty tissue was identified at the bifurcation of the digital nerve, which was excised

The Robert Jones & Agnes Hunt Orthopaedic Hospital, Oswestry, Shropshire, SY10 7AG, UK.

Correspondence and reprints : A. Kumar, 99, Lea House, Bushey Fields Road, Dudley DY1 2LU, UK. E-mail : arun28@aol.com.

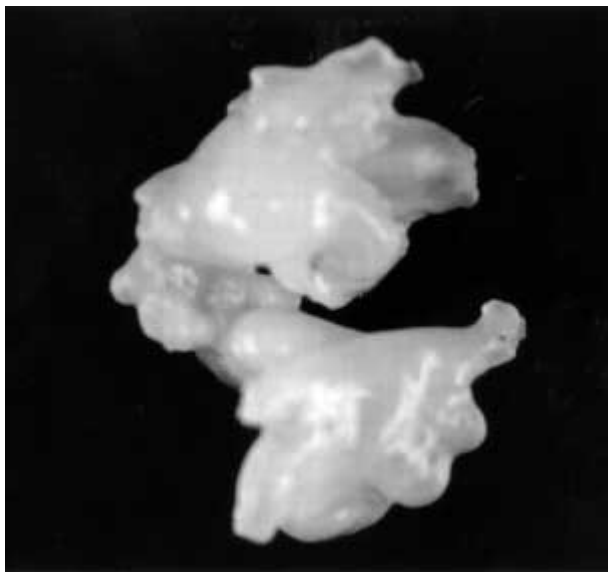


Fig. 1. — Case 1. Photograph of the excised multinodular neuroma. Each nodule represents a Pacinian corpuscle.

and sent for examination. Histology confirmed the diagnosis of Morton's neuroma. However, the adjacent tissue contained a normal nerve bundle surrounded by numerous large Pacinian corpuscles (fig 2) and this appearance was considered that of a Pacinian "neuroma". The patient made an uneventful recovery with complete resolution of symptoms.

DISCUSSION

Pacinian corpuscles are specialised nerve endings with a lamellated structure and are regarded as pressure and vibration receptors. Pacinian neuromas are uncommon benign lesions and comparatively few cases have been recorded in the literature. Although often referred to as neuromas they are not neoplastic and are more properly defined as a hyperplasia or hypertrophy of Pacinian corpuscles (6). The hyperplastic corpuscles may show a degree of pericapsular fibrosis and may be associated with increased numbers of small nerve fibres showing both endoneural and perineural fibrosis (2). Local trauma has been implicated in the pathogenesis of some cases but others have been reported without any such history (6). Rhode and

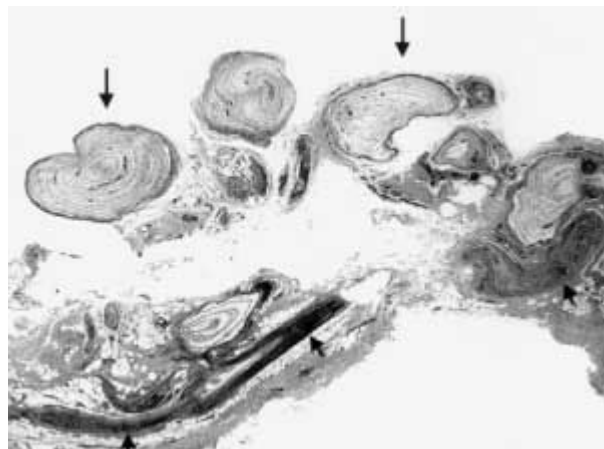


Fig. 2. — Case 2. Photomicrograph of the Pacinian neuroma showing a nerve bundle (short arrows) and several adjacent lamellated Pacinian corpuscles (long arrows).

Jennings have divided these lesions into four subtypes (7). Type A has one enlarged corpuscle attached to the epineurium of normal appearing digital nerve. Type B has grape like clusters of normal sized corpuscles attached to the digital nerve by a fine filament. In type C a series of enlarged corpuscle is located in tandem beneath the epineurium, appearing as a branch of a nerve. The type D lesion has multiple hyperplastic Pacinian corpuscles along the entire length of a digital nerve. The first three types, of which types A and B are the commonest, respond well to simple surgical excision. Type D hyperplasia is less amenable to surgical excision and may require digital neurectomy or ray amputation for pain relief (4).

Although several reports of Pacinian neuromas or hyperplasia in the hand have been published, it is an uncommon lesion in the foot where only a few cases have been reported (3, 10). In the hand most corpuscles cluster close to nerves and vessels in the metacarpophalangeal joint area and in the proximal phalanges of the three central digits. The distal phalanges contain more corpuscles than the middle phalanges (9). Most of the previously reported cases of Pacinian hyperplasia were close to the common digital nerve of the index, middle and ring fingers (5, 7) and only a few cases have been reported adjacent to the distal phalanx (2, 8). In the foot, Pacinian corpuscles are mostly found along the

digital nerves and arteries below the transverse metatarsal ligament and between this ligament and the mooring ligament of the web. They seem to be concentrated in the area of the ball of the foot, which is weight bearing during both normal and tip toe standing (1). Hyperplasia or hypertrophy of Pacinian corpuscles in the foot can produce metatarsalgia and symptoms similar to Morton's neuroma (3, 10). In our case, clinical significance of occurrence of pacinian neuroma with Morton's neuroma is uncertain but it is definitely an uncommon finding.

Hyperplasia of Pacinian corpuscles is an unusual cause of digital pain. This diagnosis should be considered in the differential diagnosis of painful lesions of hand and feet along with glomus tumour, osteoid osteoma, neuroma of digital nerve, and subungual exostosis.

Acknowledgement

We are thankful to Mr R. Perkins, FRCS, Consultant Orthopaedic Surgeon, Princess Royal Hospital, Telford to allow us to include one of his patients in this paper.

REFERENCES

1. **Bojsen-Moller F, Flagstad KE.** Plantar aponeurosis and internal architecture of the ball of the foot. *J Anat* 1976 ; 121 : 599-611
2. **Fletcher CDM, Theaker JM.** Digital Pacinian neuroma : a distinctive hyperplastic lesion. *Histopathology* 1989 ; 15 : 249-256
3. **Goldman F, Garner R.** Pacinian corpuscles as a cause for metatarsalgia. *J Am Podiatry Assoc* 1980 ; 70 : 561-567
4. **Hart WR, Thompson NW, Hildreth DH, Abell MR.** Hyperplastic Pacinian corpuscles : a cause of digital pain. *Surgery* 1971 ; 70 : 730-735
5. **Jones NF, Eadie P.** Pacinian corpuscle hyperplasia in the hand. *J Hand Surg* 1991 ; 16-A : 865-869
6. **Reznik M, Thiry A, Fridman V.** Painful hyperplasia and hypertrophy of pacinian corpuscles in the hand. *Am J Dermatopathol* 1998 ; 20 : 203-207
7. **Rhode CM, Jennings WD.** Pacinian corpuscle neuroma of digital nerves. *South Med J* 1975 ; 68 : 86-89
8. **Schuler FA, Adamson JE.** Pacinian neuroma, an unusual cause of finger pain. *Plast Reconstr Surg* 1978 ; 62 : 576-579
9. **Stark B, Carlstedt T, Hallin RG, Risling M.** Distribution of human pacinian corpuscles in the hand. A cadaver study. *J Hand Surg* 1998 ; 23-B : 370-372
10. **Toth SP.** Vater-Pacinian corpuscle. A case report. *J Am Podiatry Assoc* 1975 ; 65 : 247-249