



Osseous lipoma : eleven new cases and review of the literature

Ahmet KAPUKAYA, Mehmet SUBASI, Nevzat DABAK, Emin OZKUL

From the University of Dicle, Diyarbakir, Turkey

This study describes the clinical features, radiological appearance, and treatment of 11 new cases of osseous lipoma and reviews 301 other cases in the literature. Osseous lipomas are classified by the site of origin : either within bone (intraosseous lipoma) or on the surface of bone (juxtacortical). Intraosseous lipomas include intramedullary and intracortical lesions. Surface lipomas include subperiosteal and parosteal lesions. The authors added their cases to those found in the literature.

Intramedullary osseous lipoma (n = 262) : the most common presenting symptoms were pain and swelling (69%). The most frequent localisations were the calcaneus (24%) and the femur (22%). On plain radiographs, these lesions consisted of a well-circumscribed radiolucent area with central calcification and a sclerotic rim, occasionally with cortical expansion. Computed tomography (CT) and magnetic resonance imaging (MRI) showed that the lesions had attenuation values and a signal intensity identical to that of adipose tissue. In symptomatic lesions and in cases with impending fracture, operative treatment was indicated.

Parosteal lipoma (n = 47) : the most common presenting symptoms were local swelling and pain (58%). This lesion was most frequent in the radius (31%) and in the femur (23%). The classic radiographic appearance of parosteal lipoma was that of an exostosis-like bony prominence capped with a radiolucent layer of fat. CT-scan and MRI showed similar features.

Intracortical (n = 2) and subperiosteal lipomas (n = 1) : only a few cases were found in the literature. Their localisation differs from that of the other osseous lipomas.

The differential diagnosis of osseous lipoma in general is extensive and should include benign and malignant tumours. Combination of radiological and histological data is essential to determine whether an osseous lipoma is actually present.

Keywords : osseous lipoma ; intramedullary osseous lipoma ; parosteal lipoma ; intracortical lipoma ; subperiosteal lipoma ; tumour ; bone.

INTRODUCTION

Osseous lipomas have been classified according to their site of origin : either within bone (intraosseous) or on its surface (juxtacortical). Intraosseous lipomas are subdivided into central (or intramedullary) and intracortical lipomas. Surface osseous lipomas are subdivided into parosteal and subperiosteal lipomas.

-
- Ahmet Kapukaya, M.D., Professor.
 - Mehmet Subasi, M.D., Associate Professor.
 - Nevzat Dabak, M.D., Professor.
 - Emin Ozkul, M.D., Assistant Professor.

Department of Orthopaedic Surgery, University of Dicle, Diyarbakir, Turkey.

Correspondence : Mehmet Subasi, Dicle University Faculty of Medicine Department of Orthopaedic Surgery, Diyarbakir, Turkey. E-mail : msubasi@dicle.edu.tr.

© 2006, Acta Orthopædica Belgica.

In recent years, most features of these lesions have been well described, although some of them are still controversial. The incidence of osseous lipoma was thought to be less than 0.1% of all primary bone tumours (65). However, the real incidence seems to be much greater than previously thought, because many lipomas remain undiagnosed.

The aetiology is obscure. Hypotheses range from primary benign neoplasm to reactive bone lesion following trauma or bone infarction (9, 44, 45, 65). Some authors claim that there is no sex predilection, while others mention a preponderance of males (26, 27, 44).

The largest reported series are those of Milgram (45) and Campbell *et al* (10), respectively with 66 and 35 cases of solitary lipoma. This paper discusses the aetiology, clinical features, radiological appearance, differential diagnosis, and treatment rationale of 11 new cases of osseous lipoma added to 301 other cases found in the literature.

MATERIALS AND METHODS

Eleven cases of osseous lipoma were treated in two Turkish orthopaedic centers (table I). There were 6 men and 5 women. Their mean age was 37.6 years (range : 17 to 51). Serum levels of cholesterol and triglycerides were determined in all cases. The diagnosis was based on radiological and histological data.

The literature was searched via Medline, back to 1965. Additional cases were identified from the refer-

ences listed in case reports. Reports in another language than English or with insufficient details were excluded. This led to a subtotal of 301 cases. Finally, the authors added their own 11 cases, totalising 312 lipomas for a review study (262 central, 47 parosteal, 2 intracortical and 1 subperiosteal).

RESULTS

Personal cases (n = 11)

Table I summarises the clinical data. There were 9 intramedullary lipomas and 2 parosteal lipomas. Nine patients complained of pain without trauma, and two of these also had local swelling ; two lipomas were found incidentally. The serum cholesterol and the triglyceride levels were normal in all patients. Plain radiographs (figs 3a, 4a, 4b) showed a radiolucent area in all 9 intramedullary lipomas ; calcification or ossification was seen in 7, marginal sclerosis in 6, septum-like structures in 3. On the other hand, standard radiographs showed an irregular osseous protuberance with a radiolucent cap in the 2 patients with parosteal lipomas (fig 7a). In all patients, computed tomography (fig 3b) displayed an intramedullary or parosteal low-density area, identical to normal fat tissue. T2-weighted MRI images indicated a high-intensity signal, identical to that of normal fat tissue. The technetium-99m scan showed a normal uptake in 3 patients, a slightly increased uptake in 6, and a markedly increased uptake in 2. All 11 tumours were staged according

Table I. — Demographic data of the 11 personal cases of osseous lipoma

Patients	Age (years)	Gender	Location	Site of origin	Clinical appearance	Treatment	Follow-up (months)
1	17	M	Femur	Superficial (Parosteal)	Pain, swelling	Excision	29
2	51	F	Tibia	Central	Pain	Curettage, bone graft	62
3	16	M	Scapula	Superficial (Parosteal)	Pain, swelling	Excision	32
4	43	M	Humerus	Central	Incidental finding	Curettage, bone graft	21
5	42	M	Humerus	Central	Incidental finding	Curettage, bone graft	43
6	47	M	Tibia	Central	Pain	Curettage, bone graft	33
7	44	F	Femur	Central	Pain	Curettage, bone graft	21
8	41	F	Calcaneus	Central	Pain	Curettage, bone graft	40
9	45	M	Calcaneus	Central	Pain	Curettage, bone graft	14
10	47	F	Calcaneus	Central	Pain	Curettage, bone graft	19
11	21	F	Calcaneus	Central	Pain	Curettage, bone graft	24

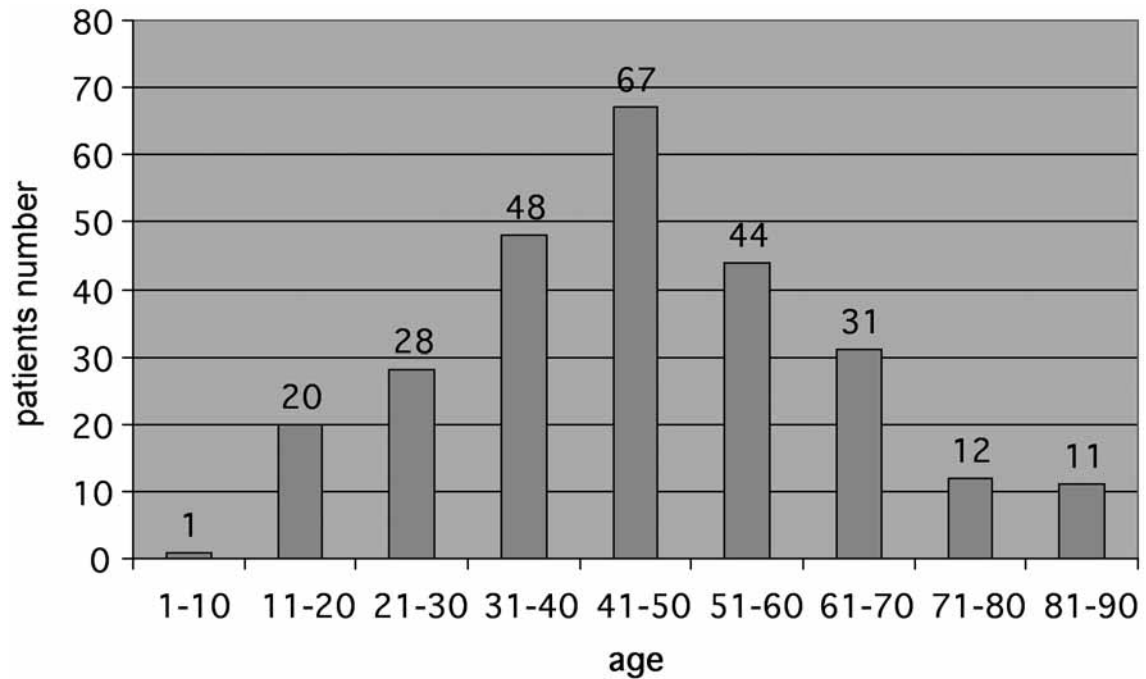


Fig. 1. — Distribution of intramedullary lipomas according to age

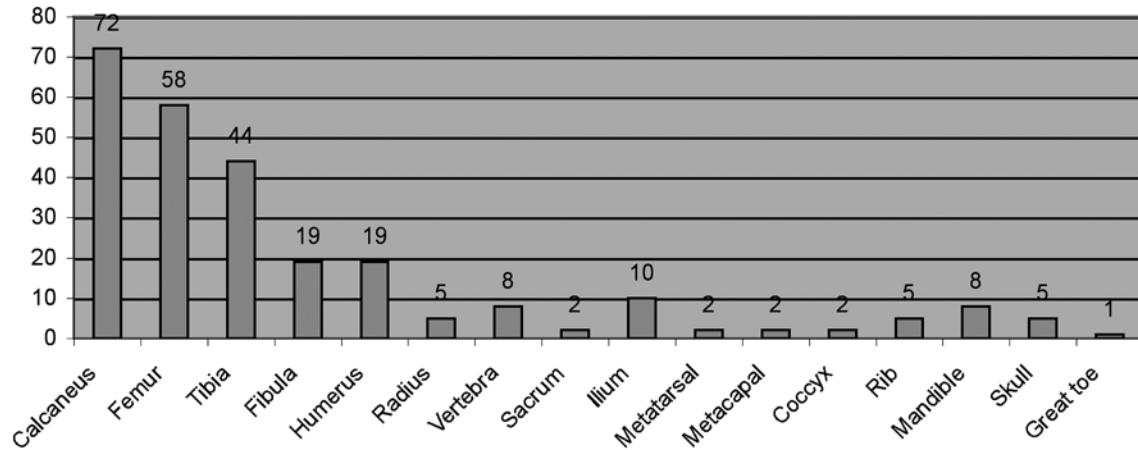


Fig. 2. — Localisation of intramedullary lipomas

to Milgram's classification (45). Milgram (44, 45) described 3 stages. Stage I : radiographically there is a purely radiolucent zone with expansion of the original cortex ; microscopically there are viable lipocytes, interspersed with thin bone trabeculae. Stage II : the radiological aspect may be the same, but there are often localised calcifications ; histo-

logically, there is a mixed pattern of viable and necrotic lipocytes besides central calcification and ossification. Stage III : radiographically there is considerable ossification around the calcified fat of the outer rim of the lesion ; histologically there is complete fat necrosis. In the current series there were 5, 4, and 2 tumours in stages I, II and III,

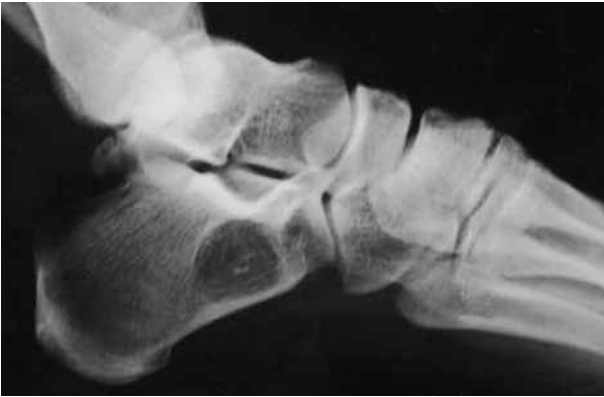

Fig. 3a. — Standard lateral view of the calcaneus : intraosseous lipoma ; the target-like calcification, which represents infarct-like changes in the lesion, is typical.

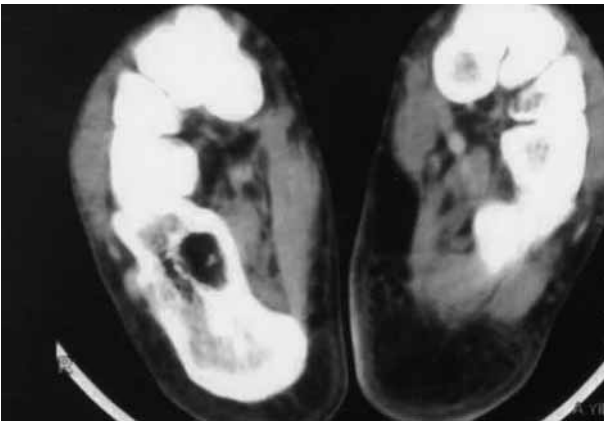


Fig. 3b. — Axial CT-scan : typical of adipose tissue

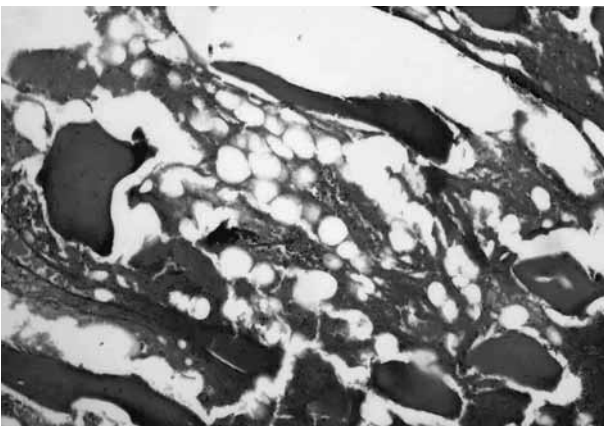


Fig. 3c. — Photomicrograph (HE, $\times 100$) : necrotic trabeculae ; adipose tissue.

respectively. The operative treatment was curettage in all but one patient, who underwent excision of a parosteal lipoma. The defect was filled with autogenous bone grafts in all patients. There were no recurrences after a mean observation period of 30.7 months (range : 14 to 62). The two patients with a humeral intraosseous lipoma continued to complain of pain after surgery, but it appeared that their pain had another origin.

Review of the literature, including 11 personal cases (n = 312)

Central (intramedullary) osseous lipoma (n = 262)

The mean age of the 262 patients was 41 years (range : 4 to 85) (fig 1). There were 155 men (59%) and 107 women (41%). One hundred and thirty patients complained of pain, 24 had noted a swelling, and 5 had a pathological fracture : altogether 60% symptomatic patients. In 63, or 24%, the lesion was found incidentally, and in the 40 remaining patients, or 15%, no symptoms were mentioned by the various authors.

The lipomas were most frequently localised (fig 2) in the calcaneus (72 patients), the femur (58 patients), the tibia (44 patients), the fibula (19 patients) and the humerus (19 patients). Central lipomas are usually solitary, although there have been cases with multiple or bilateral (both calcanei for instance) involvement (21, 26, 45, 63, 64, 73).

On plain radiographs (fig 3a, 4a, 4b), the tumour appeared as a well-circumscribed radiolucent lesion, often surrounded by a thin, well-defined partial or complete sclerotic border. Central calcification or ossification was often seen. Lobulation was sometimes present. A mild bony expansion could be seen, but rarely (1, 10, 69).

The CT-scan (fig 3b) showed an almost uniform density, equal to that of fat, but heterogeneity resulting from myxoid degeneration and dystrophic calcification could be observed (29, 40, 70). Marginal sclerosis and cortical irregularity were often observed. Perforation of the cortex was rare. The primary role of MRI in identifying an intraosseous lipoma was to visualise fat within the lesion. Indeed, intraosseous lipomas have homogeneous, high-intensity signals,

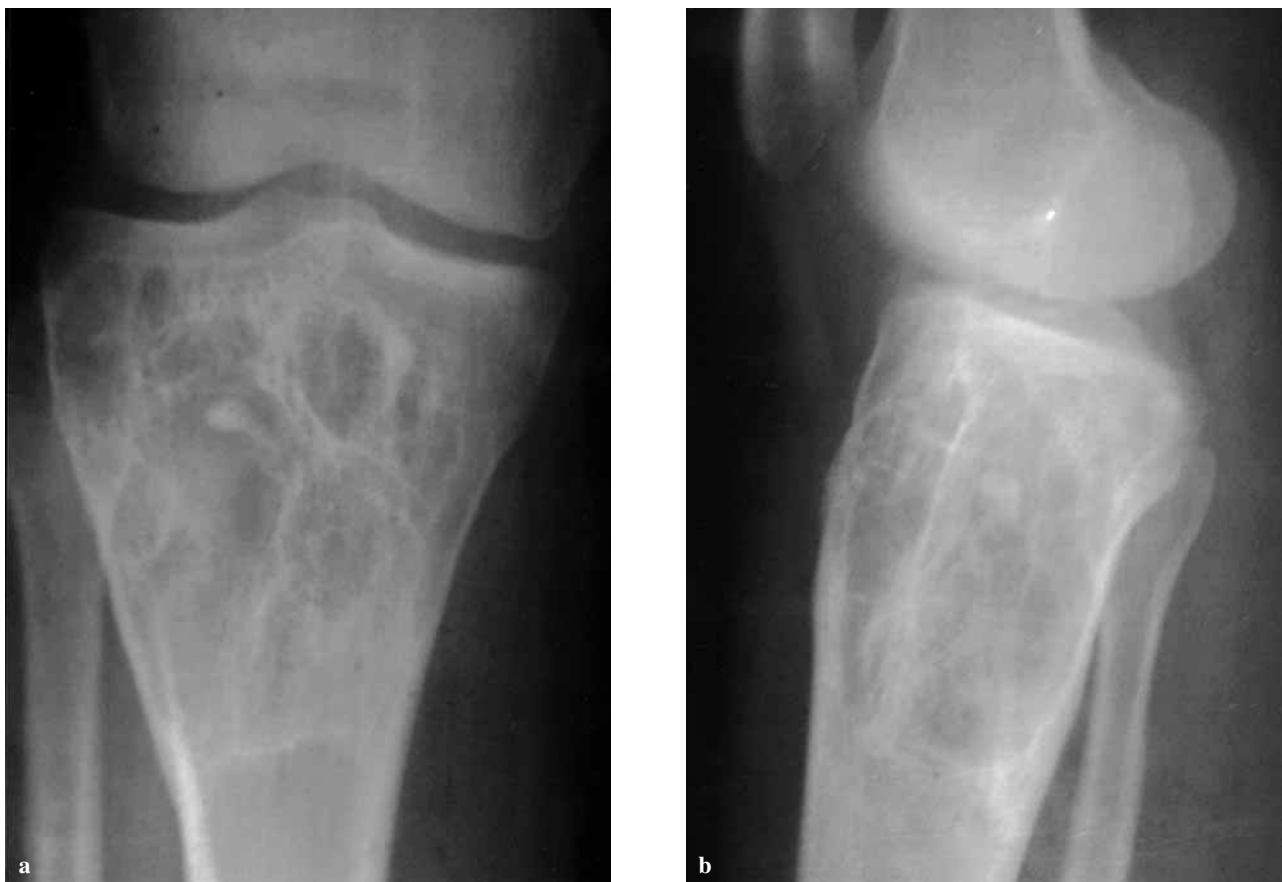

Fig. 4 *a,b*. — AP (a) and lateral (b) plain radiographs of the proximal tibia in a 51-year-old woman : intraosseous lipoma

identical to that of normal fat tissue, on both T1- and T2-weighted images (14, 61). The technetium-99m scan showed a normal or slightly increased uptake (25, 39).

Intracortical lipomas (n = 2)

There have been only two reports of intracortical lipoma. Downey *et al* (18) and Yamamoto *et al* (72) each described a cortical lipoma of the right femur, respectively in a 34-year-old and a 74-year-old woman. One of the tumours was an incidental finding. The other case had a 2-month history of gradually increasing right thigh pain. Radiographs showed in both cases a well-defined osteolytic septated lesion, expanding the cortical outline of the diaphysis. There was no radiological evidence of continuity between the tumour and the intramedullary space. The biopsy showed mature

adipose tissue and coarse bony trabeculae in both cases.

Parosteal lipoma (n = 47)

Parosteal lipoma is the most frequent osseous lipoma after intramedullary lipoma. The incidence of this tumour is 15% of all osseous lipomas in the current review study, and 0.45% of all bone tumours. The mean age of the 47 patients at the time of surgery was 47.7 years (fig 5). There were 23 men and 24 women.

Parosteal lipomas almost always occur in the extremities and are almost always solitary. The most frequent localisations were the radius (15 cases) and the femur (11 cases) (fig 6), especially the metaphyseal regions of the long bones (fig 7a), although the diaphysis could also be

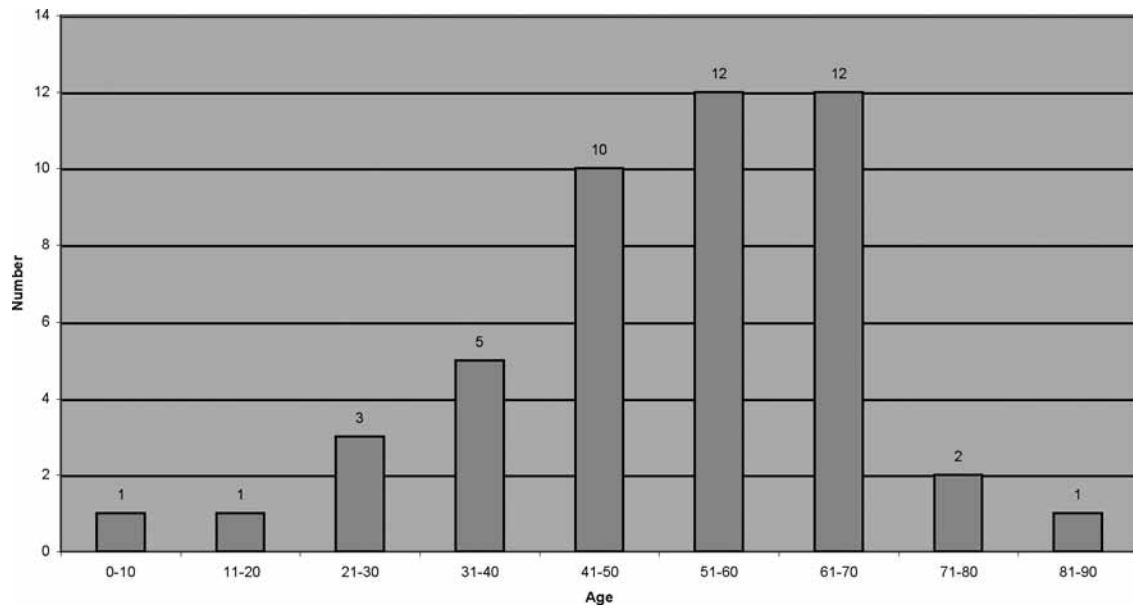


Fig. 5. — Distribution of parosteal lipomas according to age

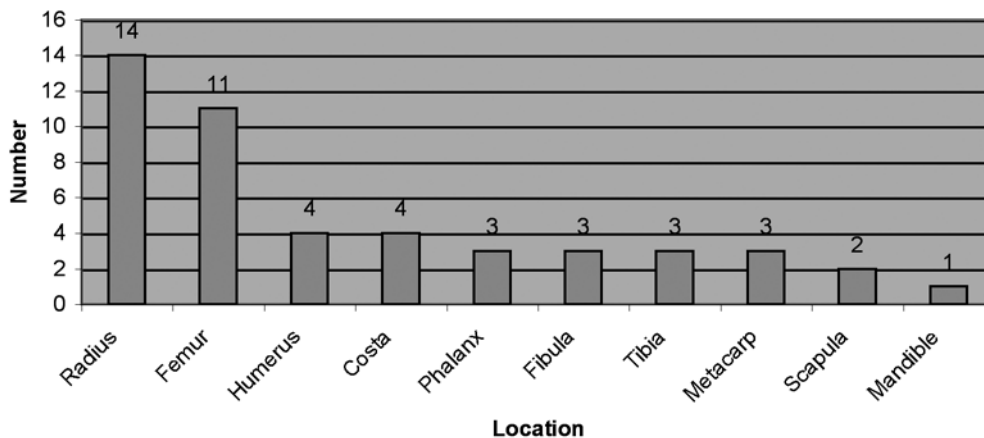


Fig. 6. — Localisation of parosteal lipomas

involved. Only one report on multiple parosteal lipomas was found (19).

The typical clinical presentation was that of a slowly growing, large, non-tender, palpable mass, not fixed to the skin. Fifteen patients complained of a mass, 13 of a mass and pain, and 8 of motor and sensory deficits ; the lipoma was an incidental finding in the 11 other patients. Neurologic deficits commonly occurred in the proximal forearm, often involving the posterior interosseous nerve (5, 6, 15,

20, 22, 43, 60). These lipomas also compressed other nerves (*e.g.* the sciatic, median, or ulnar nerve) and caused motor and sensory deficits (5). A parosteal lipoma could be large enough to limit joint motion.

Radiographically (fig 7a), the most characteristic feature was that of a parosteal radiolucent zone, which capped a cortical erosion, a cortical hyperostosis, or most frequently an exostosis-like formation (2, 3, 24, 31). The bony changes included fine linear densities, calcification, cortical thickening,

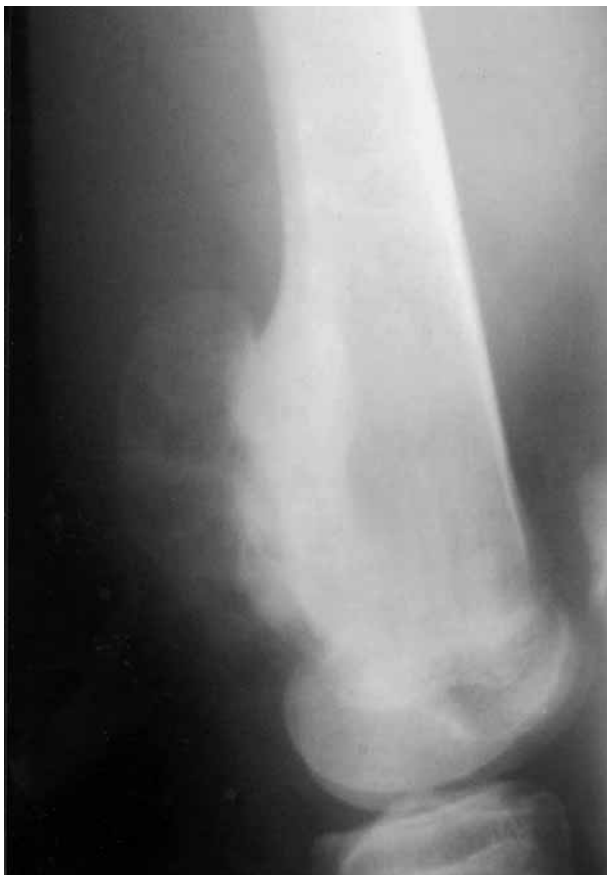

Fig. 7a. — Lateral radiograph of the left femur : irregular bony protuberance capped with a translucent mass having the same density as adipose tissue.

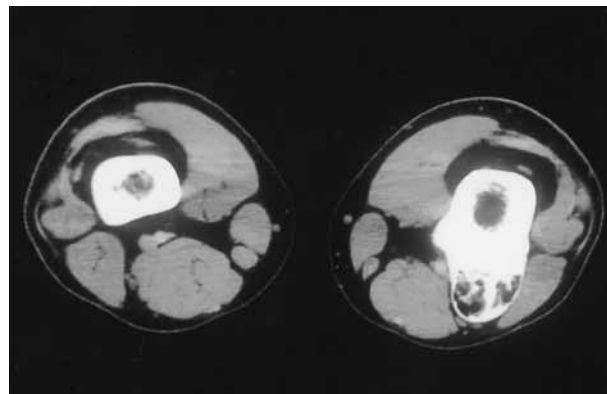


Fig. 7b. — Axial CT scan through the lesion

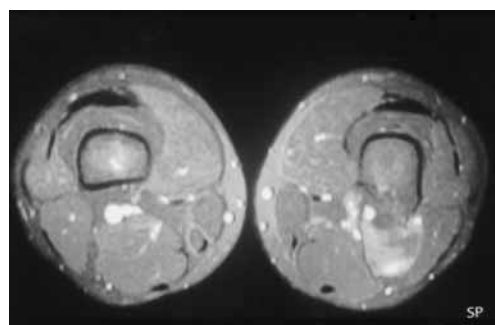


Fig. 7c. — Axial MRI showing the bony protuberance surrounded with a well-defined ovoid mass with high signal intensity.

undulation, or frank excrescences (13, 16, 24, 31, 33, 36, 48, 58, 74). Bowing deformities were confined to patients with growing bone. The cortical erosions have been attributed to long-standing pressure on the cortex caused by the soft tissue mass.

CT (fig 7b) and MRI (fig 7c) allowed improved visualisation of the relationship between the osseous excrescence and the lipomatous component, as well as the underlying bone cortex and adjacent musculature (35, 41, 48, 56). MRI was superior to CT for preoperative assessment, primarily because of its multiplanar imaging capability. On MRI, the signal intensity of the fatty component was identical to that of subcutaneous fat on T1-weighted images, while it was sometimes lower than that of fat on T2-weighted images (41, 48).

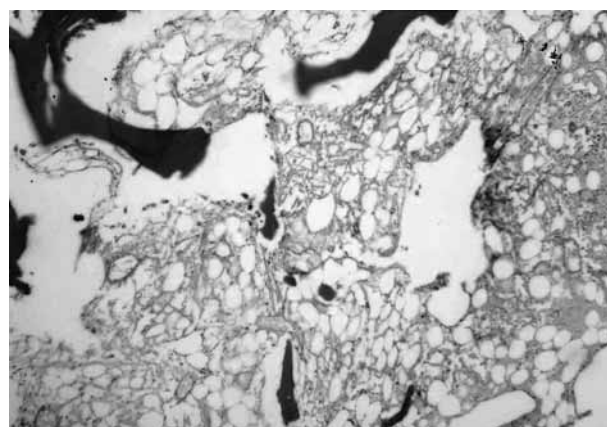


Fig. 7d. — Photomicrograph (HE $\times 100$): large mature lipocytes with scattered necrotic bony trabeculae.

Bone scintigraphy almost invariably showed increased uptake, limited to the area of bone formation.

The gross and histological findings of parosteal lipoma (fig 7d) were similar to those of soft tissue lipomas, except that the lesion had a broad attachment to the periosteum and bone (38). The lesion was often a homogeneous lobulated yellowish mass composed of mature adipocytes. It was well encapsulated, except where it adhered to the surface of the adjacent bone. Osseous and chondroid elements were frequently found within the lesions (13, 24, 38, 47); these have been attributed to metaplasia of preexisting mesenchymal cells.

Subperiosteal lipoma (n = 1)

The authors found only one case in the literature, reported by Blair *et al* (8). They described such a lipoma in a 65-year-old man who had experienced a sudden pain in his right femur. The pain recurred when weight bearing. Two radiolucent lesions were identified on the anterolateral aspect of the femoral diaphysis. The periosteum appeared to be elevated by the lesions, and to have calcified or ossified.

DISCUSSION

Central (intramedullary) osseous lipoma (IML)

This type of lipoma is often considered as one of the rarest primary bone tumours: the reported incidence is only 0.1-2.5% (11, 65). This may partly be due to the fact that it is often asymptomatic and missed. In the current review study, IML represents 84% of all the osseous lipomas.

The sex predilection in IML is controversial. Some authors have reported that there is no sex predilection, while others have reported a preponderance of males (26, 27, 45). In the current review of the literature, males (59%) were more common than females (41%).

Some authors have reported that about half of the patients with an IML are asymptomatic, and that the tumour is found incidentally (26, 42, 65, 71). This is in accordance with the current review study: only 60% were symptomatic (10, 42, 45, 68).

The localisation of the lesion is controversial. Some authors report that the most frequent site is the femur (45, 48); others claim that the most commonly affected bone is the calcaneus (10), which was also true in the current review study (fig 1). IML may occur in the axial or appendicular skeleton. In the current review study (fig 2), the vast majority of the lipomas situated in long bones were centered in the metaphyseal area, but some extended into the diaphyseal region.

On CT (fig 3b) the lipoma is frequently easily differentiated from surrounding normal fatty marrow by a peripheral ossified rim or capsule. But in other cases, this differentiation is quite difficult. The attenuation of normal marrow is often slightly greater than that of a lipoma (49). MRI facilitates the diagnosis because the lipoma has a signal intensity similar to that of subcutaneous adipose tissue on T1- and T2-weighted images. Some authors reported that short-tau inversion recovery (STIR) sequences were useful, because the extra signal intensity of the lesion is suppressed, indicating the presence of fat (7, 14, 28, 51, 54, 57, 61). Lipomas consisting solely of fat may be difficult to differentiate from surrounding normal yellow marrow.

The combination of radiological and histological (fig 3c) findings is essential to determine whether an intramedullary lipoma is actually present. According to Milgram (45) these lipomas do not remain as static masses of fat tissue, but undergo involutional changes: over time, lipomas may progress from stage I to stage II or III. However, Campbell *et al* (10) found no preponderance of stage II or III in older patients in their series or in the literature, as might be expected in a lesion that is thought to be progressive. In addition, there was a lower incidence of bone expansion or remodeling in the stage III lesions. If the natural history would involve progression, then one would expect the bony expansion to persist or even to increase.

The differential diagnosis is extensive and should include benign and malignant tumours (chondrosarcoma and liposarcoma), metabolic (localised osteoporosis, hyperlipoproteinemia), infectious (chronic tuberculosis), and collagen (pseudocyst of rheumatoid arthritis) disorders (42). The radiological differential diagnosis is also

extensive and includes such entities as simple bone cyst, posttraumatic cyst, giant-cell tumour of bone, desmoplastic fibroma, chondromyxoid fibroma, bone infarction, osteoblastoma and fungal infections of long bones, since the radiographic features of fungal infection are similar to those of IML (7, 10, 12, 23, 37, 44, 62, 67). Sometimes, IML may present with other local orthopaedic disorders. Two of the authors' patients were so characterised. Their complaints persisted, despite surgical treatment of intraosseous lipomas in the proximal and distal humerus. A thorough investigation led to the diagnosis of impingement syndrome and tennis elbow. These patients' complaints disappeared following specific treatment for these disorders. This means that the clinician should keep this possibility in mind, given that up to 28% of these lipomas are asymptomatic.

The need for surgical treatment is controversial. The gross surgical specimen consists of a lobulated mass of adipose tissue containing spicules of bone. A capsule may occasionally encompass all or part of the tumour mass. Some authors feel that in asymptomatic cases with no sign of an impending fracture, nonoperative treatment with clinical and radiographic follow-up is a wise approach (32, 34, 40, 44). Some authors have stated that this lesion belongs to the "leave me alone" group of bony lesions and that any invasive treatment is unnecessary (37). In symptomatic tumours and in cases with impending fracture, persistent pain, the need for a histological diagnosis, or the need to decrease the (very limited) risk of malignant transformation, operative intervention is the recommended treatment (10, 26, 32, 44, 45, 48, 55). Curettage with or without bone grafting is the treatment of choice. Recurrences are rare (62). Phenolisation as a local adjuvant therapy has not shown any benefit (48). Some authors have reported cases of presumed malignant transformation (46). Thus, the possibility of a secondary malignancy arising in this lesion must be kept in mind.

The aetiology of this lesion, whether it is a neoplasm or a reactive change, is unknown. Although there are many theories (trauma, bone infarction, hyperlipoproteinemia, and conglomeration of fatty marrow), none adequately explains the genesis of

this tumour (4, 17, 21, 23). Most authors believe that IML truly is a benign fatty tumour by nature (9, 44, 45, 65).

Intracortical lipomas

Intracortical lipomas originate within the bony cortex. These tumours are rare osseous lipomas (18, 72). The histological and radiological features are similar to those of intramedullary lipoma, but the intracortical location differs from that of the other osseous lipomas.

Parosteal lipomas

Parosteal lipomas, benign adipose tissue tumours situated directly on the bone cortex, are unusual neoplasms that appear to emerge from multidirectional mesenchymal modulation within the periosteum.

Although some authors have reported that parosteal lipomas are slightly more frequent in females, most authors have described a male preponderance (24, 38, 43). In our study, both genders were represented almost equally (24 females and 23 males).

The aetiology of parosteal lipoma is unknown. Theories concerning the origin of the lipomatous component include a neural origin, the extension of an existing lipoma into deeper tissues and, most commonly, the periosteum. Theories on the osteochondral elements include various reactive periosteal responses to the metaplasia of fibro-fatty mesenchymal elements (13, 47, 48, 50, 53). Recent cytogenetic analysis has identified a 3:12 translocation in parosteal lipomas, similar to that evident in soft tissue lipomas, a finding that suggests a common pathogenesis (52).

The differential diagnosis of these bony outgrowths includes osteochondroma, parosteal osteosarcoma, Nora's lesion, liposarcoma, chondrosarcoma, and periosteal ganglion (66). Especially, parosteal lipomas localised in the distal portion of the femur may be confused with parosteal osteosarcoma of this region. Also Nora's lesion, a rare lesion of the long bones, may originate in this region. However, parosteal osteosarcomas and Nora's lesions lack a lipomatous cap, are denser

radiologically, and are often metaphyseal with a pasted-on appearance. A lipomatous cap is the most important finding differentiating parosteal lipoma. In addition, marrow continuity with the adjacent long bone is absent. CT-scans can help to exclude a malignant process. In particular, liposarcomas may have a component of mature fat, but unlike lipomas they are poorly defined, heterogeneous, and contain confluent soft-tissue densities (30). The MRI findings of parosteal lipoma are characteristic and provide clues to the diagnosis.

Miller *et al* (47) proposed the following classification system based on the distinct morphologic variation seen in these tumours. Type I : lesion without ossification, lucent on radiographs. Type II : bony stalk with a lucent lipomatous cap, from a simple projection to the more complex antler-type growth, mimicking a pedunculated exostosis. Type III : a densely ossified broad-based osteochondromatous element beneath a thin lipomatous cap, simulating a sessile exostosis. Type IV : patches of chondroid and bone scattered throughout the lipoma mass.

The treatment of parosteal lipoma is complete surgical resection of the mass with extirpation of the bony excrescence and any periosteal attachments that exhibit associated hyperostosis. Early surgical exploration and excision of deep-seated lipomas in the proximal forearm is recommended to avoid permanent damage to the posterior interosseous or superficial radial nerve (5, 39, 43). No malignant potential has been determined. Local recurrence is unusual, but has been reported.

Subperiosteal lipoma

This tumour is the rarest osseous lipoma. To our best knowledge, only one case has been reported (8).

CONCLUSION

There are several important points that remain to be clarified concerning osseous lipomas, the most important of which is involution. If present, does involution occur in certain bones or throughout the body ? If some of these lesions go on to involution, is it possible to detect these lesions beforehand ? In

which bones and at which stage are symptoms more frequent ? The answers to these questions will also guide therapy. It has been reported that there is no need to treat a patient because he has a Milgram stage III intramedullary lipoma. Most patients will heal with symptomatic treatment alone. Sufficient knowledge can be obtained from long follow-up studies. However, obtaining this information is difficult, due to the relatively rare occurrence of this tumour.

REFERENCES

1. **Amrami KK, Sundaram M.** Radiologic case study. Benign intraosseous lipoma *Orthopedics* 2002 ; 25 : 1431-1432.
2. **Asirvatham R, Linjawi T.** Ossifying parosteal lipoma with exuberant cortical reaction. A case report. *Int Orthop* 1994 ; 18 : 55-56.
3. **Aydingoz U, Tutar E, Gedikoglu G, Senaran H.** Parosteal ossifying lipoma. *Eur Radiol* 2000 ; 10 : 1205-1206.
4. **Barker GR, Sloan P.** Intraosseous lipoma : Clinical features of a mandibular case with possible etiology. *Br J Oral Maxillofac Surg* 1986 ; 24 : 459-463.
5. **Berry JB, Moiel RH.** Parosteal lipoma producing paralysis of the deep radial nerve. *South Med J* 1973 ; 66 : 1298-1300.
6. **Bieber EJ, Moore JR, Weiland MD.** Lipomas compressing the radial nerve at the elbow. *J Hand Surg* 1986 ; 11-A : 533-535.
7. **Blacksin MF, Ende N, Benevenia J.** Magnetic resonance imaging of intraosseous lipomas : a radiologic-pathologic correlation. *Skeletal Radiol* 1995 ; 24 : 37-41.
8. **Blair TR, Resnick D.** Subperiosteal lipoma : A case report. *Clin Imaging* 2000 ; 24 : 381-383.
9. **Buckley SL, Burkus JK.** Intraosseous lipoma of the ilium. A case report. *Clin Orthop* 1988 ; 228 : 297-301.
10. **Campbell RS, Grainger AJ, Mangham DC et al.** Intraosseous lipoma : report of 35 new cases and a review of the literature. *Skeletal Radiol* 2003 ; 2 : 209-222.
11. **Chow LT, Lee KC.** Intraosseous lipoma. A clinicopathologic study of nine cases. *Am J Surg Pathol* 1992 ; 61 : 401-410.
12. **Chung CB, Murphy M, Cho G.** Osseous lesions the pelvis and long tubular bones containing both fat and fluid-like signal intensity : an analysis of 28 patients. *Eur J Radiol* 2005 ; 53 : 103-109.
13. **Coons DA, Sweet DE, Pitcher JD et al.** Fibular mass in a 28-year-old man. *Clin Orthop* 2000 ; 373 : 311-319.
14. **Coquerelle P, Cotten A, Flipo RM et al.** Intraosseous lipoma : role and limitations of modern imaging techniques. *Rev Rhum Engl Ed* 1995 ; 62 : 147-150.

15. Cravens G, Kline DG. Posterior interosseous nerve palsies. *Neurosurgery* 1990 ; 27 : 397-402.
16. Demos TC, Bruno E, Armin A, Dobozi W. Parosteal lipoma with enlarging osteochondroma. *Am J Roentgenol* 1984 ; 143 : 385-386.
17. Dohler R, Poser HL, Harms D, Wiedemann HR. Systemic lipomatosis of bone. A case report : *J Bone Joint Surg* 1982 ; 64-B : 84-87.
18. Downey EF, Brower AC, Holt RB. Case report 243 : cortical ossifying of femur. *Skeletal Radiol* 1983 ; 10 : 189-191.
19. Fernandez-Sueiro JL, Pinto JA, Blanco FJ *et al.* Multiple parosteal lipoma associated to polyarthritis. *J Bone Spine* 2006 ; 73 : 202-204.
20. Fitzgerald A, Anderson W, Hooper G. Posterior interosseous nerve palsy due to parosteal lipoma. *J Hand Surg* 2002 ; 27-B : 535-537.
21. Freiberg RA, Air GW, Glueck CJ *et al.* Multiple intraosseous lipomas with type-IV hyperlipoproteinemia. A case report. *J Bone Joint Surg* 1974 ; 56-A : 1729-1732.
22. Gelberman RH, Eaton R, Urbaniak JR. Peripheral nerve compression. *Instr Course Lect* 1994 ; 43 : 31-53.
23. Goldman AB, Marcove RC, Huvos AG, Smith J. Case report 280 : Intraosseous lipoma of the tibia. *Skeletal Radiol* 1984 ; 12 : 209-212.
24. Goldman AB, DiCarlo EF, Marcove RC. Case report 774. Coincidental parosteal lipoma with osseous excrescence and intramuscular lipoma. *Skeletal Radiol* 1993 ; 22 : 138-145.
25. Goldenhar AS, Maloney JP, Helff JR. Negative bone scan in the diagnosis of calcaneal intraosseous lipoma. *J Am Podiatr Med Assoc* 1993 ; 83 : 600-602.
26. Goto T, Kojima T, Iijima T *et al.* Intraosseous lipoma : a clinical study of 12 patients. *J Orthop Sci* 2002 ; 7 : 274-280.
27. Hart JAL. Intraosseous lipoma. *J Bone Joint Surg* 1973 ; 55-B : 624-632.
28. Hatori M, Hosaka M, Ehara S, Kokubun S. Imaging features of intraosseous lipomas of the calcaneus. *Arch Orthop Trauma Surg* 2001 ; 121 : 429-432.
29. Hernandez RJ. Visualization of small sequestra by computerized tomography. Report of 6 cases. *Pediatr Radiol* 1985 ; 15 : 238-241.
30. Imbriaco M, Ignarra R, De Rosa N *et al.* Parosteal lipoma of the rib. CT findings and pathologic correlation. *Clin Imaging* 2003 ; 27 : 435-437.
31. Jacobs P. Parosteal lipoma with hyperostosis. *Clin Radiol* 1972 ; 23 : 196-198.
32. Jebson PJ, Schock EJ, Biermann JS. Intraosseous lipoma of the proximal radius with extraosseous extension and a secondary posterior interosseous nerve palsy. *Am J Orthop* 2002 ; 31 : 413-416.
33. Jones JG, Habermann ET, Dorfman HD. Case report 553. Parosteal ossifying lipoma of femur. *Skeletal Radiol* 1989 ; 18 : 537-540.
34. Kamekura S, Nakamura K, Oda H *et al.* Involuting intraosseous lipoma of the sacrum showing high signal intensity on T1 weighted MRI. *J Orthop Sci* 2001 ; 6 : 183-186.
35. Kawashima A, Magid D, Fishman EK *et al.* Parosteal ossifying lipoma : CT and MR findings. *Comput Assist Tomogr* 1993 ; 17 : 147-150.
36. Kim JY, Yung SL, Park YH *et al.* Parosteal lipoma with hyperostosis. *Eur Radiol* 1999 ; 9 : 1810-1812.
37. Kozłowski K, Welshman R. What is it? Intraosseous lipoma in 13-year-old boy. *Br J Radiol* 1991 ; 64 : 855-856.
38. Krajewska I, Vernon RR, Sorby-adams G. Parosteal (periosteal) lipoma. *Pathology* 1988 ; 20 : 179-183.
39. Kurland KZ, Kennard JW. Parosteal lipoma arising from the proximal radius : a case report. *Clin Orthop* 1965 ; 41 : 140-144.
40. Lagier R. Fibular lipoma with areas of bone infarct calcification. *Eur J Radiol* 1985 ; 5 : 226-227.
41. Laorr A, Greenspan A. Parosteal lipoma with hyperostosis : report of two pathologically proven cases evaluated by magnetic resonance imaging. *Can Assoc Radiol J* 1993 ; 44 : 285-290.
42. Leeson MC, Kay D, Smith BS. Intraosseous lipoma. *Clin Orthop* 1983 ; 181 : 186-190.
43. Lidor C, Lotem M, Hallel T. Parosteal lipoma of the proximal radius : a report of five cases. *J Hand Surg* 1992 ; 17-A : 1095-1097.
44. Milgram JW. Intraosseous lipoma : radiologic and pathologic manifestations. *Radiology* 1988 ; 167 : 155-160.
45. Milgram JW. Intraosseous lipomas. A clinicopathologic study of 66 cases. *Clin Orthop* 1988 ; 231 : 277-302.
46. Milgram JW. Malignant transformation in bone lipomas. *Skeletal Radiol* 1990 ; 19 : 347-352.
47. Miller MD, Ragsdale BD, Sweet DE. Parosteal lipomas : a new perspective. *Pathology* 1992 ; 24 : 132-139.
48. Murphey MD, Johnson DL, Bhatia PS *et al.* Parosteal lipoma : MR imaging characteristics. *Am J Roentgenol* 1994 ; 162 : 105-110.
49. Murphy MD, Carroll JF, Fleming DJ *et al.* Benign musculoskeletal lipomatous lesions. *Radiographics* 2004 ; 24 : 1433-1466.
50. Noble JS, Leeson MC. Intraosseous lipoma of the humerus. *Orthopedics* 1992 ; 15 : 51-54.
51. Ozdemir H, Bozgeyik Z, Kocakoc E, Kalender O. MRI findings of intraosseous lipoma : case report. *Magn Reson Imaging* 2004 ; 22 : 281-284.
52. Petit MM, Swarts S, Bridge JA, Van de Ven WJ. Expression of reciprocal fusion transcripts of the HMGIC and LPP genes in parosteal lipoma. *Cancer Genet Cytogenet* 1998 ; 106 : 18-28.
53. Plaut GS, Salm R, Truscott DE. Three cases of ossifying lipoma. *J Pathol Bacteriol* 1971 ; 78 : 292-295.
54. Propeck T, Bullard MA, Lin J *et al.* Radiologic-pathologic correlation of intraosseous lipoma. *Am J Roentgenol* 2000 ; 175 : 673-678.

- 55. Radl R, Leithner A, Machacek F et al.** Intraosseous lipoma : retrospective analysis of 29 patients. *Int Orthop* 2004 ; 28 : 374-378.
- 56. Ramos A, Castello J, Sartoris DJ et al.** Osseous lipoma : CT appearance. *Radiology* 1985 ; 157 : 615-619.
- 57. Richardson AA, Erdmann BB, Beier-Hanratty S et al.** Magnetic resonance imagery of a calcaneal lipoma. *J Am Podiatr Med Assoc* 1995 ; 85 : 493-496.
- 58. Rodriguez-Peralto JL, Lopez-Barea F, Gonzalez-Lopez J, Lamas-Lorenzo M.** Case report 821 : Parosteal ossifying lipoma of femur. *Skeletal Radiol* 1994 ; 23 : 67-69.
- 59. Ruiz-Hernandez G, Minguez-Rey MF, Molla-Landete MA et al.** Positive bone scan in intraosseous lipoma of the tibia : role and review of diagnostic imaging methods. *Nuklearmedizin* 2000 ; 39 : N48-N49.
- 60. Schweitzer G.** Parosteal lipoma of the radius : a case report. *S Afr Med J* 1970 ; 44 : 648-649.
- 61. Stacy GS, Heck RK, Peabody TD, Dixon LB.** Neoplastic and tumourlike lesions detected on MR imaging of the knee in patients with suspected internal derangement : Part I, intraosseous entities. *Am J Roentgenol* 2002 ; 178 : 589-594.
- 62. Stukenborg-Colsman C, Wülker N, Wirth CJ.** Cystic bone lesions of the calcaneus and the talus : report of five cases. *Foot Ankle Surg* 1999 ; 5 : 33-38.
- 63. Szendroi M, Karlinger K, Gonda A.** Intraosseous lipomatosis. A case report. *J Bone Joint Surg* 1991 ; 73-B : 109-112.
- 64. Tejero A, Arenas AJ, Sola R.** Bilateral intraosseous lipoma of the calcaneus. A case report. *Acta Orthop Belg* 1999 ; 65 : 525-527.
- 65. Unni K.** Lipoma and liposarcoma. In : Unni K (ed). *Dahlin's bone tumours. General aspects and data on 11087 cases*, 5th ed, Lipponcott-Raven, Philadelphia, 1996, pp 349-353.
- 66. Valls R, Melloni P, Darnell A et al.** Diagnostic imaging of tibial periosteal ganglion. *Eur Radiol* 1997 ; 7 : 70-72.
- 67. Wada R, Lambert RGW.** Deposition of intraosseous fat in a degenerating simple bone cyst. *Skeletal Radiol* 2005 ; 34 : 415-418.
- 68. Weinfeld GD, Yu GV, Good JJ.** Intraosseous lipoma of the calcaneus : a review and report of four cases. *J Foot Ankle Surg* 2002 ; 41 : 398-411.
- 69. Williams CE, Close PJ, Meaney J et al.** Intraosseous lipomas. *Clin Radiol* 1993 ; 47 : 348-350.
- 70. Woertler K.** Benign bone tumours and tumour-like lesions : value of cross-sectional imaging. *Eur Radiol* 2003 ; 13 : 1820-1835.
- 71. Yamamoto T, Akisue T, Marui T et al.** Intraosseous lipoma of the humeral head : MR appearance. *Clin Imaging* 2001 ; 25 : 428-431.
- 72. Yamamoto T, Marui T, Akisue T et al.** Intracortical lipoma of the femur. *Am J Surg Pathol* 2002 ; 26 : 804-808.
- 73. Yildiz HY, Altinok D, Saglik Y.** Bilateral calcaneal intraosseous lipoma : a case report. *Foot Ankle Int* 2002 ; 23 : 60-63.
- 74. Yu JS, Weis L, Becker W.** MR imaging of a parosteal lipoma. *Clin Imaging* 2000 ; 24 : 15-18.