



## Periprosthetic fracture of the tibial plateau after unicompartmental knee arthroplasty

Pieter VAN LOON, Bart DE MUNNYNCK, Johan BELLEMANS

*From the University Hospital Pellenberg, Pellenberg, Belgium*

The authors report three cases of unicompartmental knee arthroplasty (UKA), complicated with perioperative periprosthetic fracture of the tibial plateau. The surgical technique was held responsible in all cases. The initial treatment was different in every case ; all patients ultimately underwent revision total knee arthroplasty with a good functional outcome.

The authors emphasise the importance of careful preparation of the tibial plateau during UKA, adequate sizing of the tibial component and caution when using a hammer during implantation of the tibial component. When a tibial plateau fracture occurs, the treatment of choice should be immediate revision total knee arthroplasty.

**Keywords** : unicompartmental knee arthroplasty ; fracture ; tibial plateau.

### INTRODUCTION

Unicompartmental knee arthroplasty (UKA) remains a technically demanding operation with immediate repercussions if not performed correctly (5).

Fortunately, periprosthetic fractures of the tibial plateau after UKA are not frequent (1).

In 13 years of clinical data we found 2 cases among a database including 136 patients. A third case was presented to us from another hospital. An extensive review of the literature revealed 8 similar fractures. There is no consistency in treatment of

these fractures. In this article we point out the main pathogenic factors and the possible benefit of immediate revision total knee arthroplasty.

### CASE REPORTS

#### Case 1

A 62-year-old female with a history of chronic knee pain and progressive deterioration of the function of her right knee presented to our department. Radiologic imaging showed narrowing of the medial joint space as part of a degenerative arthritis affecting the medial knee compartment. A unicompartmental knee arthroplasty (Accuris, Smith & Nephew, USA) was performed and the patient was free of pain with a good function of the right knee (fig 1a). Six days after operation, she experienced a sudden right knee pain after the third

---

■ Pieter Van Loon, MD, Orthopaedic Co-assistant.

■ Johan Bellemans, MD, PhD, Orthopaedic Surgeon.

*Department of Orthopaedic Surgery, University Hospital Pellenberg, Catholic University of Leuven, Pellenberg, Belgium.*

■ Bart De Munnynck, MD, Orthopaedic Surgeon.

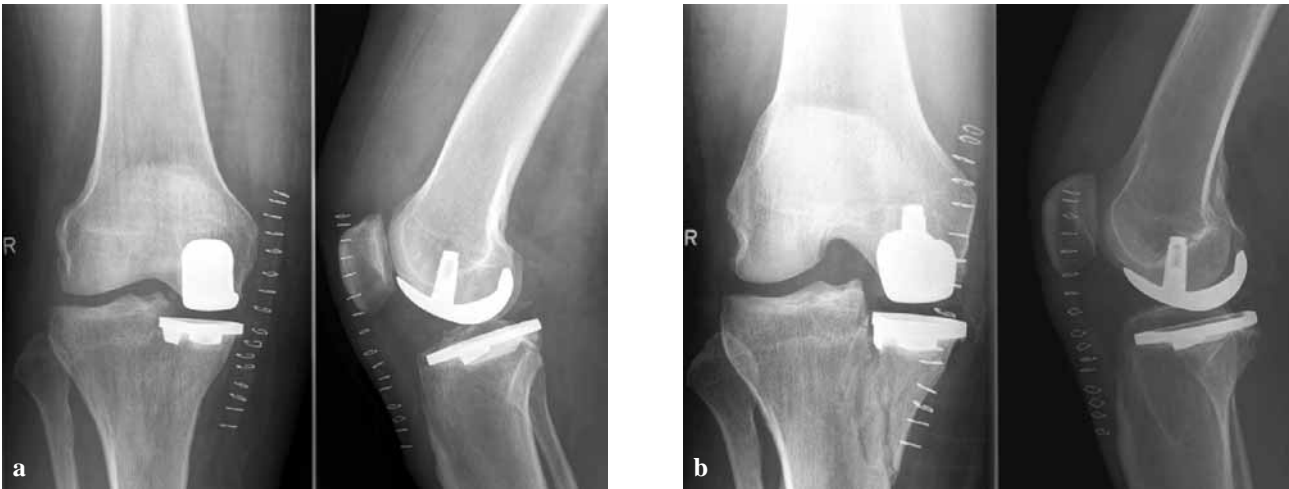*Imeldaziekenhuis, Imeldalaan 9, Bonheiden.*

Correspondence : Pieter Van Loon, Department of Orthopaedic Surgery, UZ Pellenberg, Weligerveld 1, B-3212 Lubbeek, Belgium.

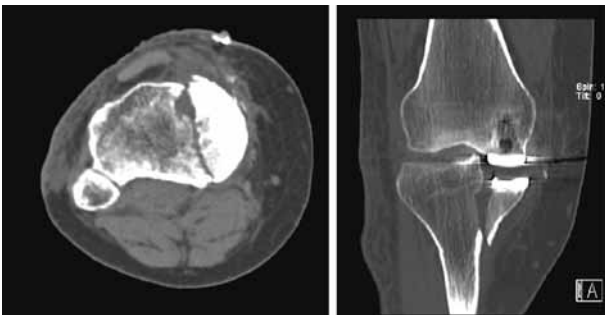
E-mail : pieter.vanloon@student.kuleuven.be.

© 2006, Acta Orthopædica Belgica.

---

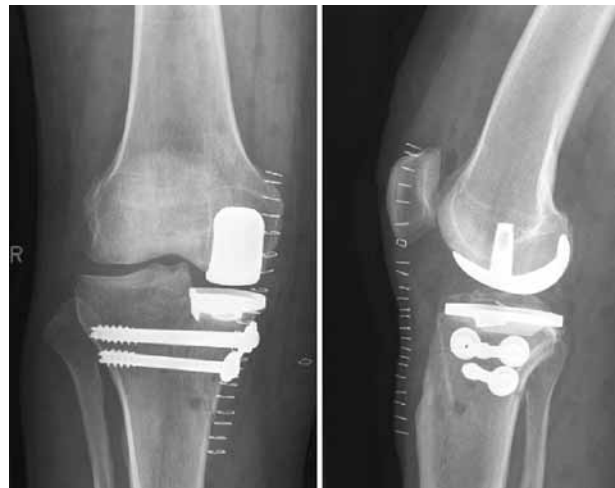

**Fig. 1.** — **a)** above : radiographs 1 day PO shows good alignment of the prosthesis ; **b)** below : Radiographs 6 days PO shows a displaced periprosthetic fracture of the tibial plateau (Case 1).



**Fig. 2.** — CT 8 days PO shows a vertical fracture starting lateral from the tibial component with caudal displacement of the medial tibiofemoral compartment (Case 1).

physiotherapy session. Radiological imaging showed a periprosthetic tibial plateau fracture (fig 1b, fig 2). Close examination of the initial post-operative radiological image revealed subtle vertical radiolucent fissures through the medial tibial plateau and a relatively peripheral positioning of the tibial implant. Three days later, the patient underwent open reduction and internal fixation of the tibial plateau fracture (fig 3). Nonetheless, pain and reduced mobility persisted for 6 months and radiological imaging showed an abnormal caudal position of the tibial implant and a medial subluxation of the knee. Six weeks later, revision TKA was performed using a medial augmentation spacer (fig 4).

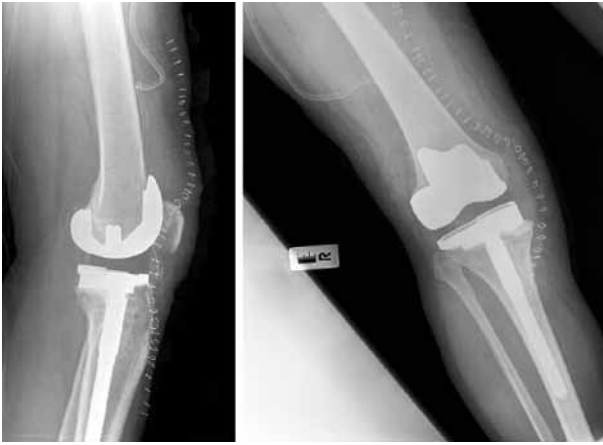

**Fig. 3.** — Radiographs after osteosynthesis of the tibial plateau fracture shows good realignment of the tibial plateau fracture (Case 1).

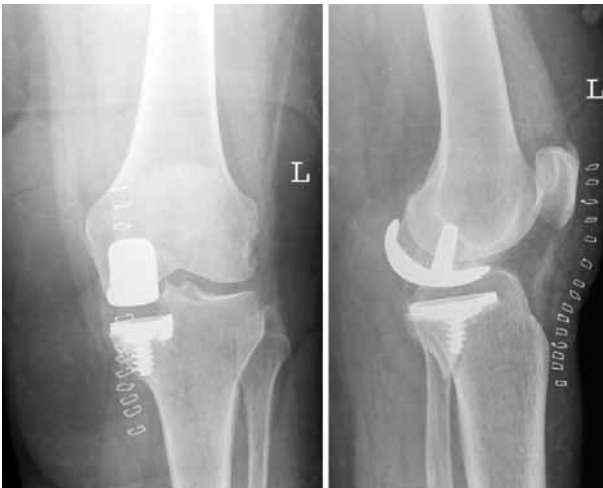Three months later, the patient had good functional outcome with minor pain.

## Case 2

A 57-year-old lady presented to our department with longstanding, progressive pain and deterioration of the function of her left knee, as part of a degenerative arthritis affecting the medial knee

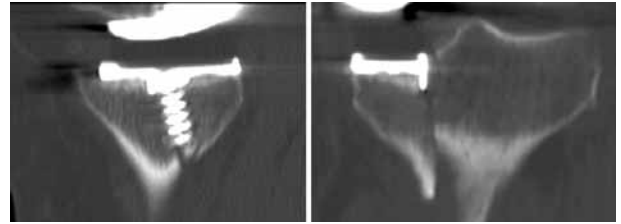


**Fig. 4.** — Radiographs after revision total knee arthroplasty show good alignment of the prosthetic components (Case 1).



**Fig. 5.** — Radiographs immediately PO show a minimally displaced oblique posteromedial periprosthetic fracture (Case 2).

compartment. Radiological imaging showed moderate narrowing of the medial tibiofemoral joint space and osteochondral damage of the left femoral condyle. After three years of conservative treatment the patient underwent a unicompartmental knee arthroplasty in our department. During implantation of the tibial component, a fissure occurred in the proximal tibia. Postoperative radiographs (fig 5) and CT (fig 6) showed a periprosthetic tibial plateau fracture. The patient was not allowed to bear full weight on the operated knee for



**Fig. 6.** — CT one-day PO shows an oblique fracture with cortical interruption of the posteromedial tibial metaphysis and slight displacement of the medial tibial plateau (Case 2).

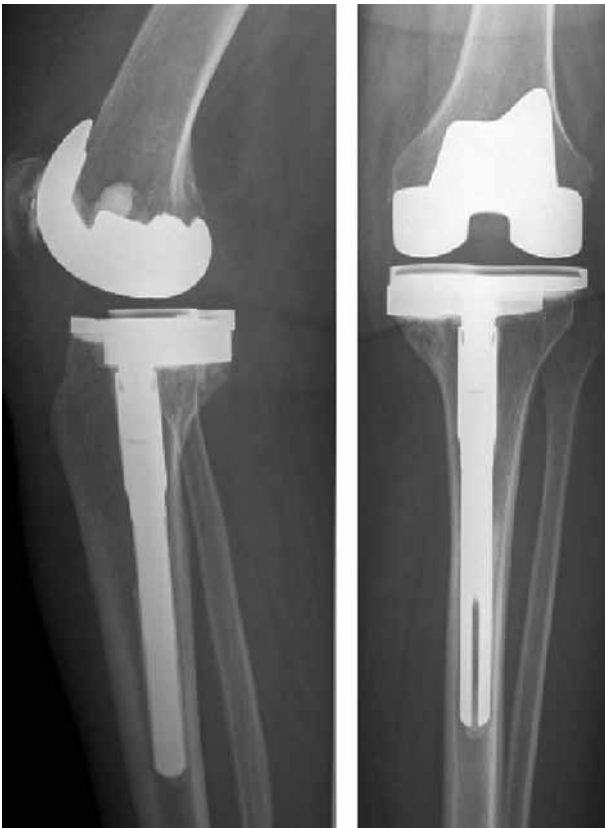a period of 6 weeks. Additionally a brace was recommended.

Over the next 12 months serious pain and reduced mobility persisted. Radiological imaging showed no signs of loosening or infection.

Fifteen months after the index operation, a revision total knee arthroplasty (Profix Oxinium PS, Smith & Nephew, USA) with use of a medial augmentation spacer was performed. Postoperative radiographs showed good position and normal alignment of the prosthesis (fig 7). Four months after operation, the patient had an adequate functional outcome with minor episodes of nocturnal pain. Flexion exceeded 90°, a mild extension deficit of 3° persisted.

### Case 3

A 45-year-old lady presented to our department with persisting pain at the medial aspect of the right knee following local trauma. Radiological imaging showed medial joint space narrowing, some osteophyte formation and bone loss in the medial tibiofemoral compartment. Avascular necrosis was excluded. Sixteen months later no improvement was noted following conservative treatment and hyaluronic acid infiltration. A unicompartmental knee arthroplasty (Profix, Smith & Nephew, USA) was performed. Intraoperatively, conversion to total knee arthroplasty was required due to collapse of the medial tibial plateau. An additional stabilisation with a cancellous screw was made to prevent subsequent collapse (fig 8). Postoperatively, the patient was not allowed to bear full weight on the



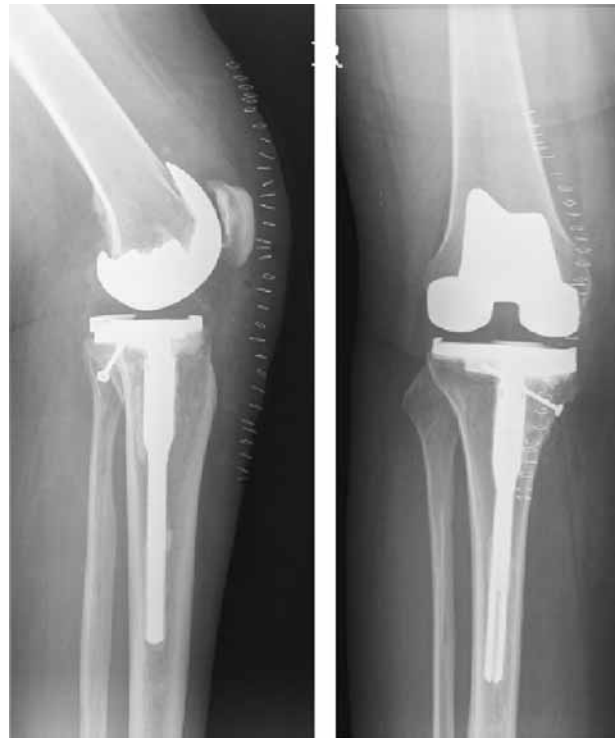**Fig. 7.** — Radiographs after revision TKA show good position and alignment of the prosthesis. No signs of loosening (Case 2).

operated knee for a period of 6 weeks. At present the patient is 2 years from surgery and is still complaining of left knee pain. Infection was excluded and given the specific features of her pain, she was referred to the pain clinic.

### DISCUSSION

A review of the literature revealed 8 cases of intraoperative tibial plateau fracture after unicompartmental knee arthroplasty (2, 4, 6, 7).

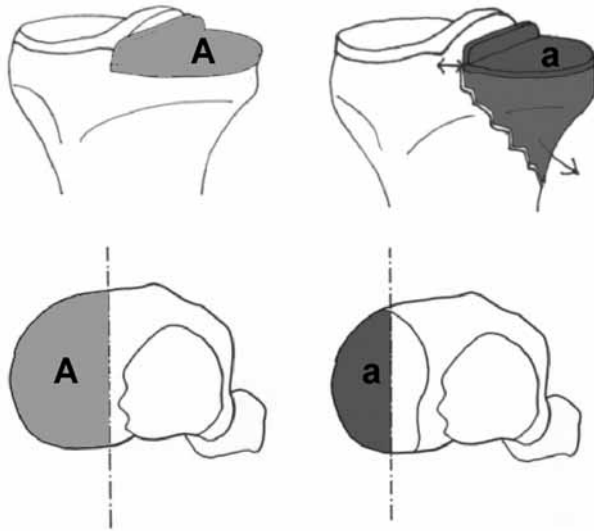
In 2000 Lindstrand *et al* (2) reported one tibial plateau fracture in a multicenter clinical trial, emphasising the demanding character of the UKA-procedure and the risk of early failure. They described the case of a 71-year-old obese woman who underwent unicompartmental knee arthroplasty (Duracon, Stryker, USA). A fracture of the



**Fig. 8.** — Radiographs immediately PO show conversion total knee arthroplasty and additional screw stabilisation with good position of prosthetic implants (Case 3).

medial tibial plateau occurred postoperatively. Radiographs indicated that the drill hole for the tibial peg was more distal than usual, close to or through the cortical bone. There was an 8-mm posterior overhang of the femoral component in the sagittal plane, resulting in a high force in weight-bearing flexion. The tibial component was placed about 10 mm peripheral to the medial spine. Revision arthroplasty was performed 9 months after the index operation.

In 2003 Sloper *et al* (6) reported a case of tibial plateau fracture during impaction of the tibial component of a unicompartmental knee prosthesis (Oxford, Biomet, USA). This fracture occurred following a small breach in the posterior tibial cortex during preparation of the tibial plateau. The tibial component and cement were removed. The fracture was then reduced and fixed using a buttress plate



**Fig. 9.** — Undersizing as well as peripheral positioning of the tibial component reduces the area (A) on which the load will act. This results in higher stresses on a smaller and eccentric region of the tibial plateau, predisposing to tibial plateau fracture.

and screws, which resulted in a stable fixation. The intended implant was cemented in place and the operation proceeded uneventfully. Post-operatively, the patient was allowed non weight-bearing mobilisation for 6 weeks, at which point the fracture had healed both clinically and radiologically. At 9 month follow-up the patient was free of pain with good functional outcome.

In 2003 Scott *et al* (5) reported 4 cases of medial tibial plateau fracture after UKA through guide-pin holes in the proximal tibia. The tibial resection guide was initially fixed with 2 pins and subsequently repositioned distally, creating 4 holes in the proximal tibia perpendicular to the long axis of the bone. According to the authors, the compressive strength of the proximal tibia was reduced because of excessive drilling which resulted in fracture through these holes between 3 and 18 weeks after operation. In at least one case, the medial tibial cortex was violated by one pin. All cases required revision total knee arthroplasty after respectively 3, 6 and 8 months. Three patients had adequate functional outcome ; one patient required a second revision procedure because of progressive subsidence and loosening of the tibial component.

In 2003 Yang *et al* (7) reported 2 cases of medial tibial plateau fracture after unicompartmental knee arthroplasty (Oxford, Biomet, USA) with minimally invasive instrumentation. In the first patient, fracture of the medial tibial plateau with collapse of the tibial component occurred after 5 months. Revision total knee arthroplasty was performed, and the patient experienced an uneventful recovery period with good functional outcome. In the second patient a minimally displaced medial tibial plateau fracture occurred after 3 months. The patient refused surgical intervention and avoided weight bearing for 6 weeks. Minimal depression of the tibial plateau was described but the patient recovered without further complications and obtained adequate functional outcome. The authors believe that these cases represent fatigue fractures through a misplaced fixation pin close to the medial cortex, creating a stress riser. This was an unfortunate technical error with the new instrumentation and it could be avoided.

In all these cases the surgical technique was the main pathogenic factor.

We would like to emphasise the importance of careful tibial plateau preparation. When preparing the space for the tibial keel, the surgeon must be cautious not to breach the posterior cortex using the tibial gouge. Other interruptions of the proximal tibial cortical ring structure (e.g. fixation pins) also reduce the compressive strength of the tibial plateau, predisposing to fractures through these interruptions (3).

When using a hammer for fixation of the tibial component this should be done with the utmost care to avoid splitting of the tibial plateau.

Finally we would like to highlight the importance of adequate sizing of the tibial component. Oversizing induces large forces being exerted on the non-supported portion of the tibial tray in weight-bearing flexion, which result in stress fractures. Undersizing or peripheral positioning of the tibial component results in inadequate load transmission between the tibial component and the proximal tibial plateau. The stress will be concentrated on a small and eccentric region of the tibial plateau leading to tibial plateau stress fractures (fig 9).

When a tibial plateau fracture occurs, conservative treatment will not prevent progressive collapse of the medial compartment with distalisation of the tibial component. Since open reduction and internal fixation cannot prevent this evolution, we believe immediate revision to total knee arthroplasty should be the treatment of choice.

#### REFERENCES

1. **Berger RA, Nedeff DD, Barden RM et al.** Unicompartamental knee arthroplasty : Clinical Experience at 6- to 10-year follow up. *Clin Orthop* 1999 ; 367 : 50-60.
2. **Lindstrand A, Stenstrom A, Ryd L, Toksvig-Larsen S.** The introduction period of unicompartamental knee arthroplasty is critical. *J Arthroplasty* 2000 ; 15 : 608-616.
3. **Rockwood CA, Green DP, Bucholz RW.** *Fractures in Adults*. Third edition. Lippincott Williams & Wilkins, Baltimore.
4. **Scott AB, Carrington R, Zayontz S et al.** Tibial plateau stress fracture. A complication of unicompartamental knee arthroplasty using 4 guide pinholes. *J Arthroplasty* 2003 ; 18 : 809-812.
5. **Scott RD.** Unicondylar arthroplasty : redefining itself. *Orthopedics* 2003 ; 26 : 951-952.
6. **Sloper PJH, Hing CB, Donell ST.** Intra-operative tibial plateau fracture during unicompartamental knee replacement : a case report. *The Knee* 2003 ; 10 : 367-369.
7. **Yang KY, Yeo SJ, Lo NN.** Stress fracture of the medial tibia plateau after minimally invasive unicompartamental knee arthroplasty. *J Arthroplasty* 2003 ; 18 ; 809-812.