



Percutaneous pinning for fractures of the distal radius

Marco ROSATI, Sara BERTAGNINI, Giuseppe DIGRANDI, Carmelo SALA

From the University of Pisa, Italy

The results of treatment of wrist fractures with percutaneous pin fixation in 106 patients are reported. Functional and radiological evaluation was made for all patients. All fractures healed ; loss of reduction occurred in only two cases. The best results were obtained in metaphyseal fractures of the radius, while good results were obtained in intra-articular fractures ; the worst results were noted in cases with an associated fracture of the ulnar styloid, in elderly patients, or in cases with associated fractures in other parts of the skeleton. When the volar tilt has been restored to more than 10 degrees higher than normal, loss of wrist motion may occur. No vascular, nervous or tendinous lesion was noted. A nerve entrapment syndrome at the wrist occurred in a fairly high percentage of cases (14.1%).

Keywords : distal radius ; fracture ; pinning ; results.

We use various techniques for wrist fractures, including closed reduction and cast immobilisation, internal fixation, external fixation and percutaneous pin fixation : the choice depends on several factors including fracture type, bone stock, associated lesions, age of the patient and surgeon's experience.

As already stated by other authors (4, 10, 20, 23), we believe percutaneous fixation of wrist fractures to be a fundamental method of treatment. The aim of this study was to assess the limits and potentials of such a procedure, through evaluation of our cases. The questions are : is it possible to achieve good results by closed reduction and percutaneous fixation ? In which cases is it be advisable to use other procedures ? Is percutaneous pin fixation sufficiently stable ? What complications can arise with this technique ?

INTRODUCTION

The treatment of wrist fractures is a debated topic. Literature on the subject fails to classify them in a logical manner. Objective evaluation of wrist fracture treatment may highlight poor results in 30% of cases, but the percentage swings within a wide range in reported series. Altissimi *et al* (1) demonstrated that 32% of 297 patients with wrist fractures showed unsatisfactory clinical results. Knirk and Jupiter (14) could demonstrate arthritis in 65% of young adults in a long-term radiological follow-up, and clinical symptoms in 93% of cases.

■ Marco Rosati, MD, Assistant Professor.

■ Sara Bertagnini, MD, Resident.

■ Giuseppe Digrandi, MD, Resident.

2nd Orthopaedic Department University of Pisa, Pisa, Italy.

■ Carmelo Sala, MD, Assistant.

3rd Anaesthesiology Department University of Pisa, Pisa, Italy.

Correspondence : Marco Rosati, Orthopaedic Department University of Pisa, Via Risorgimento 36, 56100 Pisa, Italy.

E-mail : rosati61@virgilio.it.

© 2006, Acta Orthopædica Belgica.

MATERIALS AND METHODS

When treating wrist fractures we may choose one of several techniques suggested in Fernandez's algorithm (8). The stability of the reduction is the central element in orthopaedic treatment, and according to Lafontaine *et al* (15), signs of possible instability after wrist fracture reduction are : 20° dorsal angulation, 5-mm shortening of the radius, comminution, intra-articular fracture line, combined fracture of the ulna, age over 60 years .

If a surgical procedure has been chosen, percutaneous fixation is preferred for fractures which can be reduced by closed manipulation ; otherwise ORIF or external fixation is appropriate.

Several percutaneous techniques have been suggested over the years, but we believe the choice of a technique should be guided by the following criteria :

1. achieving fracture stability,
2. minimising Kirschner wire injuries to nerves, vessels and tendons, pin migration and rupture, pressure lesions by Kirschner wires and cast,
3. avoiding any damage to the articular surface of the radius.

The Crenshaw technique (6), carefully reviewed by Mah and Atkinson (16), satisfies all these criteria. It is based on stabilisation of wrist fractures by two parallel K-wires, inserted from the apex of the styloid process of the radius, towards the medial cortex of the radius proximal to the fracture.

The technique is usually applied under brachial plexus block, and reduction of the fracture is then attempted by manual traction, aiming to restore the normal radial and volar tilt of the distal radial epiphysis.

Fingertrap traction is not used ; the patient's forearm is maintained parallel to the floor, manipulation of the fracture is then performed, with flexion of the elbow at 90 degrees.

The quality of the reduction is then checked with fluoroscopy in A-P and lateral projections, by rotating the C- arm around the wrist while the patient's hand is held steadily.

Osteosynthesis is then performed with two 1.2 or 1.5 mm diameter K-wires.

The K-wires should be introduced at the styloid process of the radius, holding the drill parallel to the ground, while the K-wire is held at 45° angle to the longitudinal axis of the radius. When the angle between the K-wires and the axis of the radius at the styloid process is less than 45°, piercing the medial cortex of the radius

above the fracture often becomes impossible, as the K-wire slides into the medullary cavity, which will result in decreased stability.

Metaphyseal fractures of the radius are more stable when two parallel K-wires connect four opposite points on the radius cortex ; in fractures with a punch-fragment, a K-wire is inserted transversely, after reduction of the fracture, as described by Fernandez and Geissler (fig 1) (7). Reduction of the punch fragment is often very difficult (3, 12, 17, 18, 21, 22, 25). An attempt to reduce it can be made with a percutaneous K-wire used as a lever, pushing the fragment upwards. Very rarely a dorsal access between the 4th and 5th extensor compartments is required. When a satisfactory reduction of the fragment is not achieved in this way, open reduction and plate fixation is necessary.

At the end of surgery the K-wires are bent and cut away from the skin, so as to avoid pressure lesions, and for the same reason a cast is made with slight ulnar deviation of the wrist. In patients below 60 years of age who do not have comminuted fractures, a below-elbow cast may be sufficient if the bones are considered sufficiently strong by the surgeon at the time of introduction of the K-wires.

If the above requirements are not fulfilled, the cast should also immobilise the elbow.

A total of 160 wrist fractures were treated with this method in the Orthopaedic Department of Pisa University Hospital from 1994 to 2003. We were able to review 106 wrist fractures out of the total number of 160 (35 males and 71 females). The average age of the patients at the time of injury was 51.7 years (range : 7 to 81) and the average follow-up period was 56.7 months (range : 12 to 108 months). The rest of the patients had died, had moved or were living far away from our hospital. Sixty-four of the 106 wrist fractures were caused by accidental falls, 27 by road traffic accidents and 15 were sports injuries. The wrist fracture was open in 4 cases : in 6 cases, it was associated with a transtrochanteric fracture of the femur, in 2 cases with a forearm fracture, and in 2 cases with a carpal scaphoid fracture. Six cases were multiple injuries, and one case was associated with a fracture of the scapula. The fracture was bilateral in two cases, but only one side was taken into account, while the contralateral fracture was treated by percutaneous internal fixation combined with external fixation.

The fractures were classified according to the Frykman classification (9). Eleven were classified as Frykman type 1, 15 as type 2, 16 as type 3, 17 as type 4, 10 as type 5, 10 as type 6, 13 as type 7, and 14 as type 8.

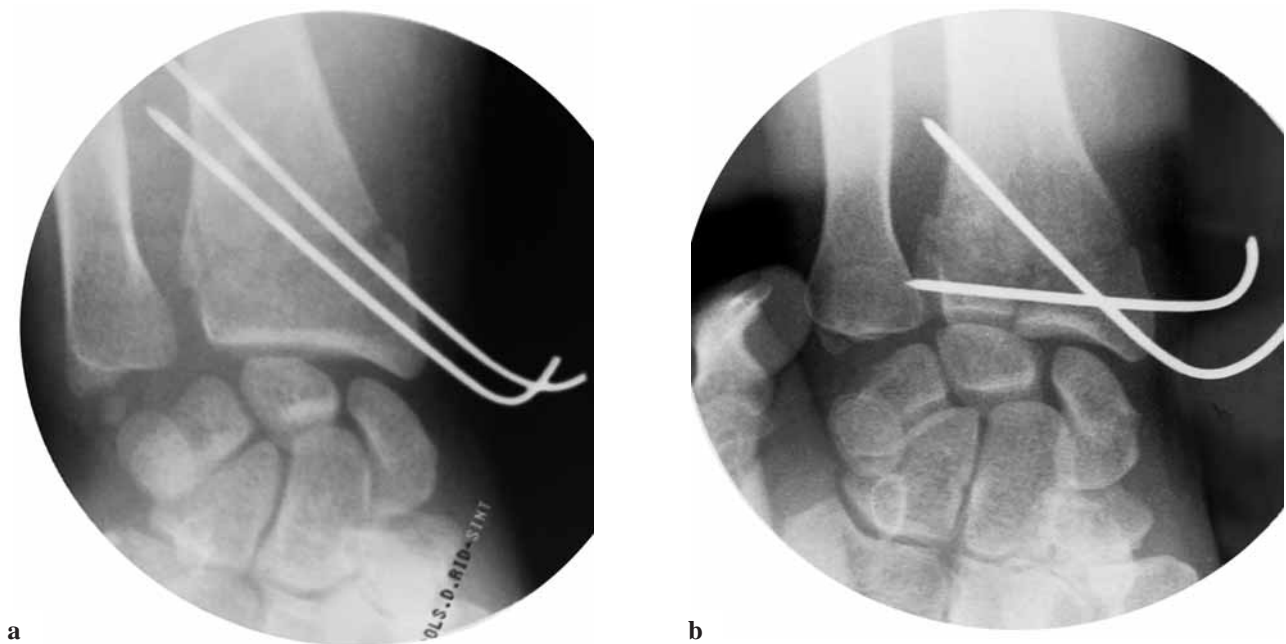


Fig. 1. — **a)** Osteosynthesis according to Crenshaw/Mah, with two Kirschner wires piercing the styloid process of the radius and, proximally, the metaphyseal cortex at the ulnar side of the radius ; **b)** Percutaneous pinning according to Fernandez with a second transversal Kirschner wire stabilising a die punch fragment.

Clinical results were evaluated in the follow-up period according to Cooney's modification of the Green and O'Brien scheme (5, 11) (table I).

Possible complications were looked for, such as entrapment neuropathies, vascular or nerve injuries due to the use of the K-wires, pain and/or swelling of the distal radioulnar joint or other symptoms suggesting a lesion of the triangular fibrous cartilage, functional impairment of the shoulder and elbow.

A static and dynamic radiological evaluation was carried out for every patient, including measurement of radial tilt, volar tilt, ulnar variance and radial translation (fig 2), before surgery, during the post-operative radiological check, after K-wire removal, and during follow-up.

Static predictive signs of fracture instability were searched for in every patient by means of a radiological check (scapholunate instability, lunotriquetral instability, DISI and VISI). In every patient a dynamic evaluation was performed using the image intensifier : test of radial deviation, ulnar deviation, closing the fist under strength, and ulnar translocation of the carpus.

RESULTS

According to Cooney's modification of Green and O'Brien's score for clinical outcome we had 57 excellent results (53.7%), 28 good results (26.5%), 12 fair results (11.3%) and 9 poor results (8.5%).

Results obtained with different types of fractures are reported in table II.

Type 1 and type 2 fractures scored highest in Cooney's modification of Green and O'Brien's scheme (fig 3), with only one poor result out of 26 patients (19 excellent results and 6 good results).

This score decreased in type 3 and 4 fractures (5 fair results out of 33), and further decreased in type 5 and 6 fractures (3 fair or poor results out of 20 fractures), reaching the worst score in type 7 and type 8 fractures (4 fair or poor results out of 27 fractures). It is interesting that for type 3 and 4 or type 7 and 8 (with similar numbers of cases), the

Table I. — Clinical scoring system of Green and O'Brien modified by Cooney

	Score (points)	Findings
Pain	25	none
	20	mild, occasional
	15	moderate, tolerable
	0	severe or intolerable
Functional status	25	returned to regular employment
	20	restricted employment
	15	able to work but unemployed
	0	unable to work because of pain
Range of motion	25	full
	15	75-99% of normal
	10	50-74% of normal
	5	25-49% of normal
	0	less than 25% of normal
	or evaluating dorsiflexion-palmar flexion arc of injured hand	
	25	120° or more
	15	91-119°
	10	61-90°
	5	31-60°
	0	30° or less
Grip strength	25	normal
	15	75-99% of normal
	10	50-74% of normal
	5	25-49% of normal
	0	0-24% of normal
Final result	Excellent	90-100
	Good	80-89
	Fair	65-79
	Poor	< 65

percentage of fair and poor results increases when fracture of the ulnar styloid is present.

Within the fractures with poor and fair results (21 cases out of 106), 8 fractures were Frykman type 8, and 5 were Frykman type 4. On the other hand, no Frykman type 1 fractures were observed within these two groups.

An analysis of these 21 poor and fair results shows that 10 were open fractures or were associated with other bone fractures, which interfered with rehabilitation after removal of the cast.

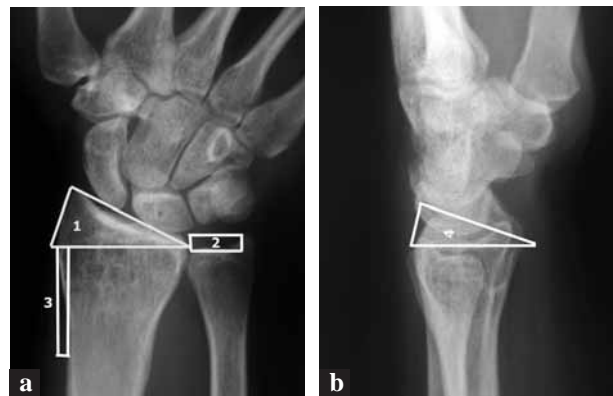

Fig. 2a, b. — Radiological indices assessed for this study
 1. Radial tilt
 2. Ulnar variance
 3. Radial translation
 4. Volar tilt

Table II. — Results obtained in the different groups of fractures according to Frykman's classification

Type	Number of cases	Excellent	Good	Fair	Poor
1.	11	9 (81.8%)	2 (18.2%)	/	/
2.	15	10 (66.6%)	4 (26.6%)	/	1 (6.8%)
3.	16	8 (50%)	7 (43.7%)	1 (6.3%)	/
4.	17	5 (29.4%)	7 (41.2%)	4 (23.5%)	1 (5.9%)
5.	10	4 (40%)	4 (40%)	1 (10%)	1 (10%)
6.	10	6 (60%)	1 (10%)	2 (20%)	1 (10%)
7.	13	10 (76.9%)	2 (15.4%)	/	1 (7.7%)
8.	14	5 (35.7%)	1 (7.1%)	4 (28.6%)	4 (28.6%)

Among these fractures, five were considered as poor results despite an acceptable final evaluation score : in three cases because of their low evaluation score, and in the other two because secondary fracture reduction was necessary.

Age also appeared as an important factor for prognosis : young patients in fact showed good and excellent results even for intrarticular fractures (fig 4) ; the best results were obtained in Frykman type 1 fractures and in all cases without involvement of the ulna.

The best results were achieved in younger patients, as suggested by the fact that clinical results were similar in all age groups below 30 years and progressively worsened between 30 and 50 years of age (table III).

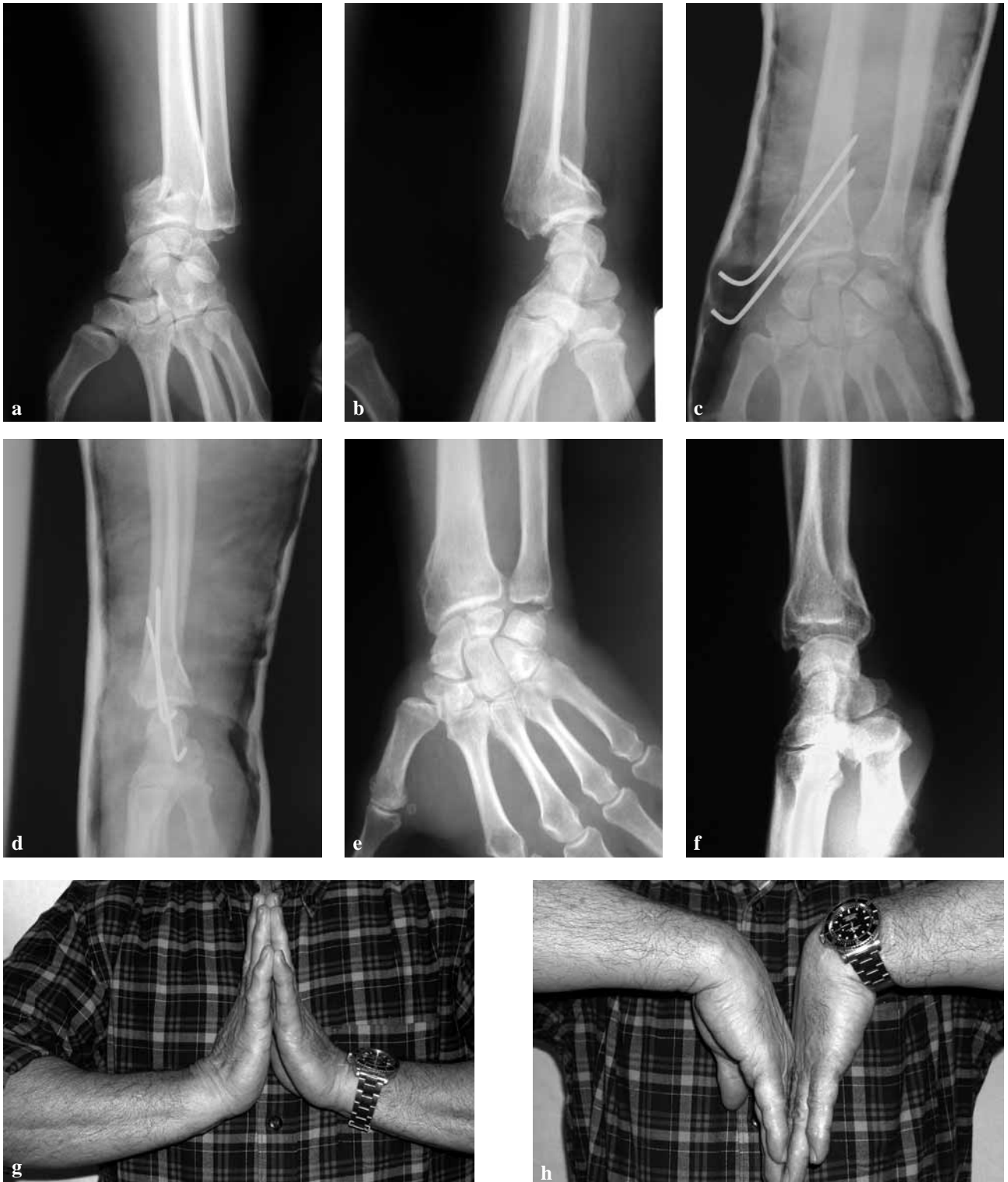

Fig. 3. — TS, 57-year-old white male : **a, b**) type 2 wrist fracture according to Frykman ; **c, d**) percutaneous pinning according to Crenshaw/Mah was performed, healing was achieved 5 weeks later ; **e, f**) Radiograph 1 year later, with adequate restoration of all radiologic indices ; **g, h**) excellent functional result.

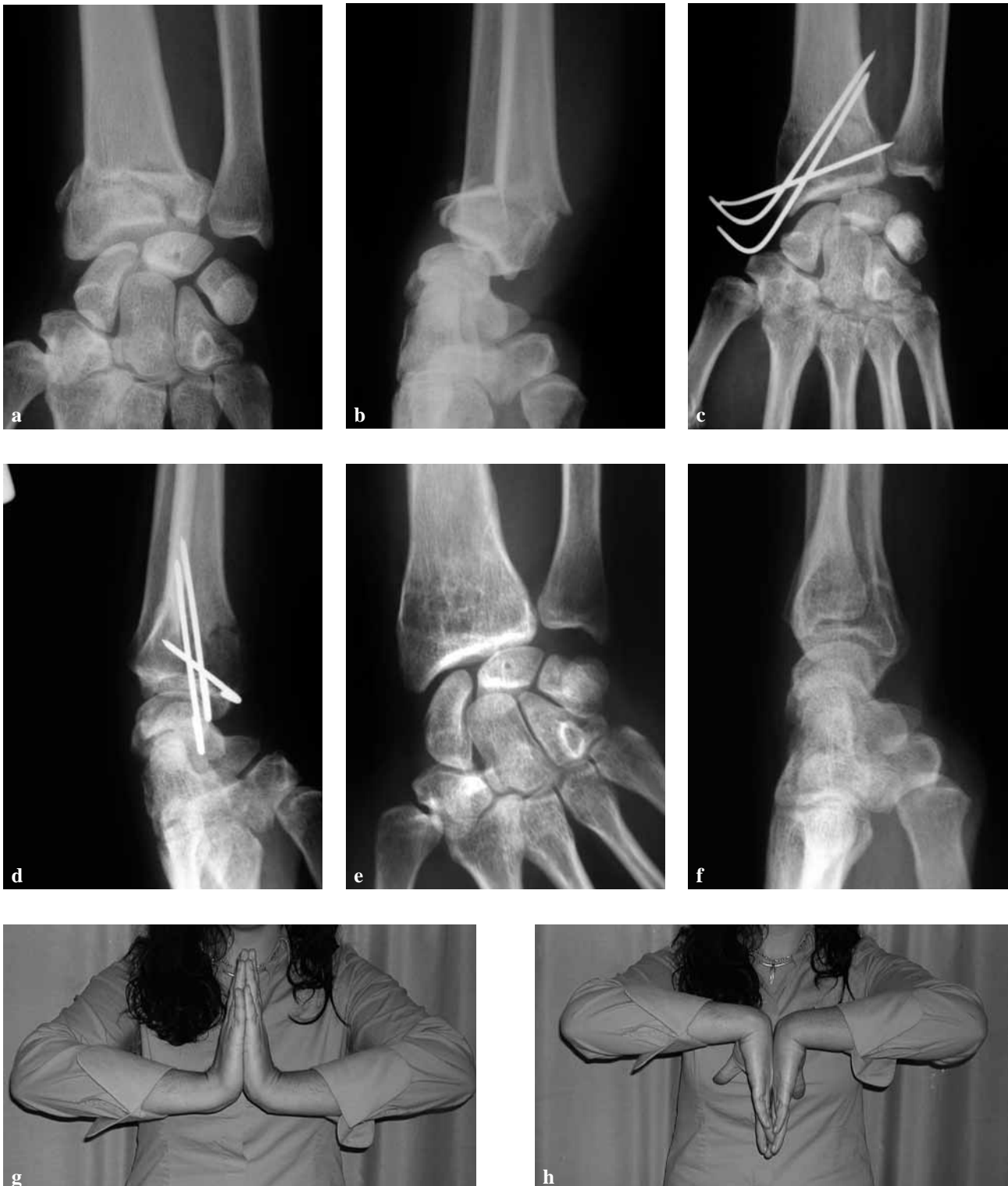

Fig. 4. — DGS, 28-year-old white female : **a, b)** Frykman's type 3 fracture at the wrist ; **c, d)** intraoperative radiographs ; **e, f)** radiograph one year later ; **g, h)** excellent functional result.

Table III. — Results versus age of patients

Age	Number of cases	Excellent	Good	Fair	Poor
7-30 yrs	22	21 (95.5%)	1 (4.5%)	/	/
31-50 yrs	17	10 (58.8%)	6 (35.3%)	1 (5.9%)	/
51-60 yrs	24	10 (41.7%)	9 (37.5%)	3 (12.5%)	2 (8.3%)
61-70 yrs	23	8 (34.8%)	8 (34.8%)	4 (17.4%)	3 (13%)
> 70 yrs	20	8 (40%)	4 (20%)	4 (20%)	4 (20%)

Radiological healing of the fractures was noted after an average of 40.9 days (range ; 30 to 70 days) ; the average time was shorter in type 2 fractures (average of 37.6 days), and longer in comminuted type 7 and type 8 fractures (45 and 46.5 days).

K-wires remained well fixed until fracture healing in 71.6% of cases, radiological indices at final follow-up did not exhibit any change beyond 5° when the follow-up films were compared with the postoperative films after removal of the cast. A 5° difference may be due to different x-ray projections. The remaining 28.4% of the fractures showed a loss of reduction between 5 and 10 degrees for volar tilt, despite a satisfactory clinical result. Unacceptable loss of reduction occurred in only 1.8% of cases, making further surgery necessary. Migration of the K-wires was not noted, nor was there any fragmentation of the bone during K-wire insertion. There were no deep infections, and only two cases with superficial infection which resolved after removal of the K-wires and antibiotic therapy (Cephalosporin p.o for a few days).

Good radial tilt, radial translation and ulnar variance were achieved in all cases, even for Frykman type 7 and 8 fractures. However, the volar tilt was not always restored (the best results were obtained in type 1 and 3 fractures, and the worst results in type 6 and 8).

Wrist instability was observed in 12 cases (11.3%), mainly scapholunate, and was only visible upon dynamic testing.

VISI was observed in two cases and DISI in one case.

Pain at the distal radioulnar joint or symptoms due to injuries of the triangular fibrocartilage complex were evident in 6 cases (5.6%), in patients

with combined fractures of the radius and ulna (23.5% of Frykman type 4 fractures).

In 15 cases (14.1%) a median nerve or an ulnar nerve compression syndrome at the wrist developed, especially in type 8 and type 4 fractures (33.3% of the total number of type 8 fractures and 29.4% of type 4 fractures). Thirteen cases out of 15 were females over 50 years of age, while only two cases were males between 30 and 40. Irritation of the 2nd sensitive branch of the radial nerve was only seen in one case and promptly resolved after removal of the cast after 3 weeks.

Pain or functional limitation of the elbow was not observed, 6 cases showed symptoms of subacromial impingement which could not simply be explained by immobilisation due to the cast.

Reflex sympathetic dystrophy developed in 4 cases : two of them were patients who underwent two consecutive reductions and pinnings, and were subsequently treated with prolonged immobilisation.

DISCUSSION

The best results were obtained in this series in Frykman type 1 fractures of the radius metaphysis, particularly with no involvement of the ulna.

Good results were usually obtained in younger patients, while clinical results progressively worsened with increasing age over 50 years.

Prognostic evaluation based solely on anatomopathologic grounds appears difficult, as results also depend on other important factors such as age, metabolic bone condition, association with other injuries locally or in other parts of the body, timing of surgery, quality of rehabilitation and patient's efforts towards rehabilitation, and the occurrence of unpredictable complications such as reflex

sympathetic dystrophy and subsequent joint stiffness. It also appears that a greater number of fragments or a larger involvement of the articular surface make prognosis worse, as pointed out by Trumble *et al* (26).

Restoration of radial tilt, ulnar variance and radial translation are usually easy to achieve, while major difficulties are encountered in restoration of the volar tilt. Bartosh and Saldana (2) demonstrated that during normal reduction, the radiocarpal palmar ligaments (thicker and stronger than the dorsal ligaments), are stretched during traction, whereas tension is lost during flexion. At the same time it is worth remembering that a 0° volar tilt does not impair the range of motion of the wrist and hand, because it is compensated for by the midcarpal joint.

On the contrary, if the volar tilt is more than 10° above normal, biomechanical changes follow, which affect strength and mobility of the joint.

All this is fully confirmed by our study, from which it appears that a 0° volar tilt does not cause any problem.

On the other hand, 12 out of 23 patients with a final volar tilt increased more than 10° showed fair or poor results.

Reduction of the punch fragment is often difficult, with a 50% success rate or more when a dorsal miniopen approach is performed, as suggested by Fernandez and Jupiter (8). A punch fragment should always be stabilised by a transverse Kirschner wire. If stabilisation of the fragment is not fully achieved by this method, open reduction should be performed.

Fracture fixation was stable in the majority of our cases; secondary displacement occurred in only two cases. A good bone stability was achieved with two 1.5 mm Kirschner wires, as also noted by other authors (19). A good quality bone is necessary if the elbow is to be left free, otherwise the K-wires cannot oppose the traction by the brachioradialis muscle and subsequent displacement may occur. In our experience, patients never developed stiffness of the elbow after being immobilised in an above-elbow cast.

Stiffness of the shoulder noted in some patients was probably due to preexisting subacromial

impingement. Loss of reduction, as mentioned above, occurred in two patients: an elderly female with advanced osteoporosis who was treated with a below-elbow cast after osteosynthesis, and a 50-year-old male with progressive displacement of the fracture after removal of the Kirschner wires, 40 days after surgery.

As previously noted by other authors, we observed an increasing number of poor results and wrist instabilities when fracture of the ulnar bone was also present. Symptoms from fibrous triangular cartilage tears are more often observed in Frykman type 4 lesions (23.5% of the cases), while this was not seen in Frykman type 1, 3, 5, and 7 lesions. Only two out of 7 patients with pain at the distal radioulnar joint wished to undergo further surgery. The 12 patients with wrist instability after fracture did not have any functional impairment. Nine of them had dynamic instability: none of these patients felt the need for a new operation to deal with this problem, in contrast with current literature. We believe that percutaneous K-wire fixation does not cause iatrogenic nerve or tendon lesions, contrary to what is reported by some authors. The reported incidence of nerve injuries ranges from 0.2% to 79% (13, 27) in literature, but in our study no such lesions were observed, probably due to the site of introduction of the Kirschner wires at the radial styloid process, avoiding the nerves and the radial artery (24).

REFERENCES

1. **Altissimi M, Antenucci R, Fiacca C, Mancini GB.** Long-term results of conservative treatment of fractures of the distal radius. *Clin Orthop* 1986; 206: 202-210.
2. **Bartosh RA, Saldana MJ.** Intra-articular fractures of the distal radius. A cadaveric study to determine if ligamentotaxis restores palmar tilt. *J Hand Surg* 1990; 15-A: 18-22.
3. **Bickerstaff DR, Bell MJ.** Carpal malalignment in Colles' fractures. *J Hand Surg* 1989; 14-B: 155-160.
4. **Clancey GJ.** Percutaneous Kirschner-wire fixation of Colles' fractures. *J Bone Joint Surg* 1984; 66-A: 1088-1114.
5. **Cooney WP III, Dobyms JH, Linscheid RL.** Complications of Colles' fractures. *J Bone Joint Surg* 1980; 62-A: 613-619.
6. **Crenshaw AH Jr.** Fractures of the shoulder, girdle, arm and forearm. In Crenshaw AH (Ed): *Campbell's Operative Orthopaedics*. 4th ed. Mosby, St. Louis. 1982.

7. **Fernandez DL, Geissler WB.** Treatment of displaced articular fractures of the radius. *J Hand Surg* 1991 ; 16-A : 375-384.
8. **Fernandez DL, Jupiter JB.** *Fractures of the Distal Radius. A Practical Approach to Management.* Springer-Verlag, New York, 1996.
9. **Frykman G.** Fracture of the distal radius including sequelae-shoulder-hand syndrome, disturbance of the distal radio-ulnar joint and impairment of nerve function. A clinical and experimental study. *Acta Orthop Scand* 1967 ; *Suppl* 108.
10. **Greatting MD, Wood MB.** Percutaneous pinning of fractures of the distal end of the radius. In : Saffar P and Cooney W.III. *Fractures of the Distal Radius.* Martin Dunitz, London, pp 50-55.
11. **Green DP, O'Brien ET.** Open reduction of carpal dislocation. Indications and operative techniques. *J Hand Surg* 1978 ; 3 : 250-265.
12. **Habernek H, Weinstabl R, Fialka C, Schmid L.** Unstable distal radius fractures treated by modified Kirschner wire pinning : anatomic considerations, technique and results. *J Trauma* 1994 ; 36 : 83-88.
13. **Hochwald NL, Levine R, Tornetta P III.** The risks of Kirschner wire placement in the distal radius : a comparison of techniques. *J Hand Surg* 1997 ; 22-A : 580-584.
14. **Knirk JL, Jupiter JB.** Intra-articular fractures of the distal end of the radius in young adults. *J Bone Joint Surg* 1986 ; 68-A : 647-659.
15. **Lafontaine M, Hardy D, Delincé PH.** Stability assessment of distal radius fractures. *Injury* 1989 ; 20 : 208-210.
16. **Mah ET, Atkinson RN.** Percutaneous Kirschner wire stabilisation following closed reduction of Colles' fractures. *J Hand Surg* 1992 ; 17-B : 55-62.
17. **Melone CP Jr.** Articular fractures of the distal radius. *Orthop Clin North Am* 1984 ; 15 : 217-236.
18. **Mortier JP, Kuhlmann JN, Richet C, Baux S.** Brochage horizontal cubito-radial dans les fractures de l'extrémité inférieure du radius comportant un fragment postéro-interne. *Rev Chir Orthop* 1986 ; 76 : 567-571.
19. **Naidu SH, Capo JT, Moulton M et al.** Percutaneous pinning of distal radius fractures : a biomechanical study. *J Hand Surg* 1997 ; 22-A : 252-257.
20. **Rayhack JM.** The history and evolution of percutaneous pinning of displaced distal radius fractures. *Orthop Clin North Am* 1993 ; 24 : 287-300.
21. **Rosati M, Cantini G, Nesti C, Lisanti M.** Crenshaw/Mah percutaneous pinning of wrist fractures : a review of 63 cases. *J Hand Surg* 2000 ; 25-B : 36-37.
22. **Seitz WH, Froimson AL, Leb R, Shapiro JD.** Augmented external fixation of unstable distal radius fractures. *J Hand Surg* 1991 ; 16-A : 1010-1016.
23. **Stein AH, Katz SF.** Stabilization of comminuted fracture of the distal inch of the radius : percutaneous pinning. *Clin Orthop* 1975 ; 108 : 174-181.
24. **Steinberg BD, Plancher KD, Idler RS.** Percutaneous Kirschner wire fixation through the snuff box : an anatomic study. *J Hand Surg* 1995 ; 20-A : 57-62.
25. **Szabo RM, Weber SC.** Comminuted intra-articular fractures of the distal radius. *Clin Orthop* 1988 ; 230 : 39-48.
26. **Trumble TE, Schmitt SR, Vedder NB.** Factors affecting functional outcome of displaced intra-articular distal radius fractures. *J Hand Surg* 1994 ; 19-A : 325-340.
27. **Weber SC, Szabo RM.** Severely comminuted distal radial fracture as an unsolved problem : complications associated with external fixation and pins and plaster techniques. *J Hand Surg* 1986 ; 11-A : 157-165.