



Osteosarcoma of the talus : A case report

Roberto SEIJAS, Joan MINGUELL, Manuel PÉREZ

From the Hospital Vall d'Hebron, Barcelona, Spain

The reported incidence of osteosarcoma of the foot is very low. Osteosarcoma of the talus is extremely rare and few cases have been reported in the literature. The clinical findings are not typical, and osteosarcoma of the talus can be easily misdiagnosed, resulting in a delay in proper treatment. We report the case of a patient with osteosarcoma of the talus, from a series of 120 osteosarcomas treated at our hospital between 1966 and 2002.

Keywords : talus ; osteosarcoma.

INTRODUCTION

The World Health Organisation classification system defines osteosarcoma as a malignant tumour characterised by bone or osteoid tissue formation by tumour cells. Osteosarcoma is the most common malignant primary bone tumour, with the exception of myeloma, and the vast majority of cases occur in the age group between 10 and 20 years.

Conventional osteosarcoma occurs most commonly in the metaphysis of long tubular bones. The knee joint (distal femur and proximal tibia) and proximal humerus are affected in 70% of the cases (6). The reported incidence of osteosarcoma of the foot is very low (10), representing only 0.17%-2.08% of all osteosarcomas (3). Osteosarcoma of the talus is extremely rare and few cases have been reported in the literature (1, 4, 9).

We report the case of a patient with osteosarcoma of the talus, from a series of 120 osteosarcomas treated at our hospital between 1966 and 2002.

CASE REPORT

A 20-year-old woman with a history of ankle sprains was seen by an orthopaedic surgeon to investigate pain and swelling of the ankle, of several weeks duration. On the basis of findings in the initial radiograph (fig 1) osteochondritis of the talus was suspected (8), and the patient was prescribed conservative treatment consisting of complete rest and non-steroid anti-inflammatory therapy (NSAID). The pain and swelling persisted. Magnetic resonance imaging (MRI) (fig 2) showed several cystic lesions and necrosis of the talus. Open biopsy was performed and the diagnosis of osteogenic sarcoma was established (fig 3). The patient was referred to our Musculoskeletal Oncology Unit where the tumour diagnosis protocol was completed and the lesion was classified

■ Roberto Seijas, MD, Orthopaedic surgeon.

■ Joan Minguell, MD, Orthopaedic surgeon.

■ Manuel Pérez, MD, Orthopaedic surgeon.

Department of Orthopaedics and Traumatology, Hospital Vall d'Hebron, Barcelona, Spain.

Correspondence : Roberto Seijas, c/ Rei Martí 50 2º 2º 08014 Barcelona, Spain.

E-mail : roberto6jas@hotmail.com.

© 2006, Acta Orthopædica Belgica.

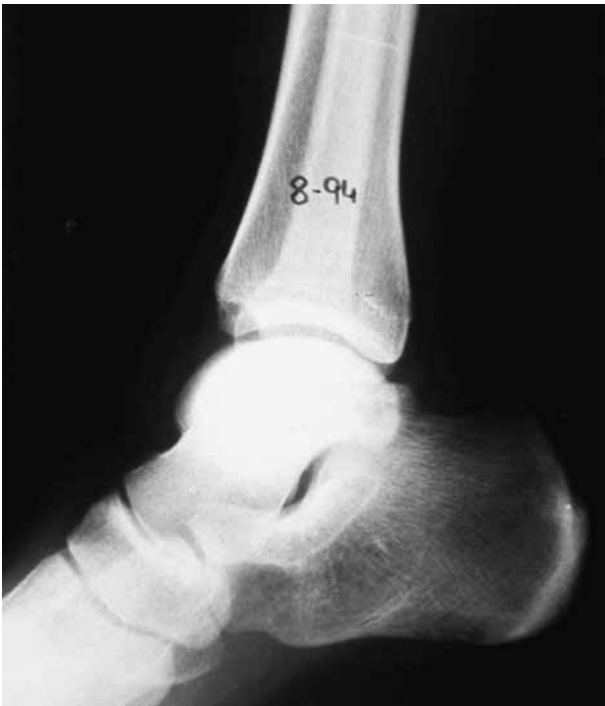

Fig. 1. — Lateral radiograph suggesting osteochondritis of the talus.

according to Enneking's staging system (7) as a stage IIB primary malignant tumour.

Neoadjuvant chemotherapy treatment with cisplatin (CDDP) in two cycles was initiated to reduce the volume of the tumour, and subsequently radical surgical amputation of the lower third of the leg was performed. The patient was then treated with adjuvant chemotherapy (CDDP) to assure complete cure of the disease. Macroscopic examination of the specimen showed extra-osseous tumour extension with soft tissue invasion (fig 4), and microscopy showed features of a mesenchymal tumour with chondroblastic and osteoblastic components, confirming the diagnosis of osteoblastic osteosarcoma.

After ten years of follow-up the patient has shown no evidence of active disease.

DISCUSSION

Although osteosarcoma is a common malignant primary bone tumour in childhood and adoles-

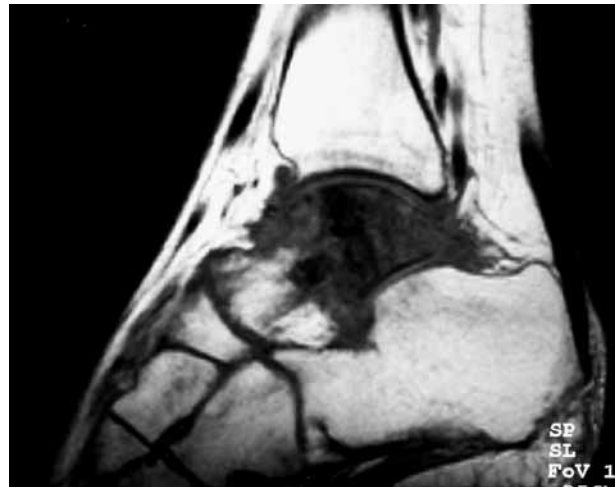


Fig. 2. — MRI showing the tumoral lesion in the talus with extraosseous invasion.

cence, it rarely affects the foot. Only 0.17%-2.08% of all osteosarcomas involve this region, with an average of 0.38% (1, 3, 6), as reported in various series (2, 10). Berlin (2) noted malignant tumours in less than 1% of the 67,000 foot lesions that he reviewed. Of all osteosarcomas treated at our hospital between 1966 and 2002 (120 cases) only one case affected the talus, an incidence similar to another series (10).

The average age of patients with osteosarcoma of the foot bones is higher than that of other locations: 33 years versus 15-20 years. One explanation for the older age at presentation offered in the literature is the tendency for osteosarcoma of the small tubular bones of the feet to arise secondary to another process (3, 5). The talus is essentially an unusual site for a primary bone tumour (3, 6). In a study by Dahlin and Unni (6), involvement of the short bones, such as the carpal and tarsal bones, represented only 1.1% (14/1274) of osteosarcomas. The calcaneus and metatarsals are the most commonly affected bones of the foot (3, 10).

The clinical findings are atypical (3, 9), and osteosarcoma of the talus can be easily misdiagnosed, resulting in a delay in proper treatment (3, 9). The common clinical signs are pain and formation of a mass (5, 8), but the relative infrequency of its occurrence often results in a delay between the onset of

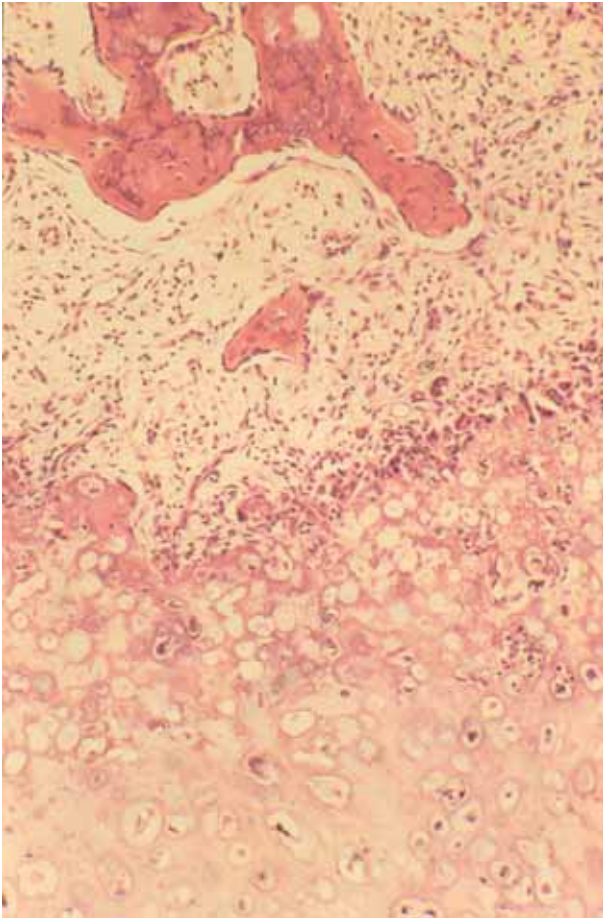


Fig. 3. — Histological study showing a large number of atypical mitotic cells producing an osteoid matrix. Pleomorphism and hyperchromia are visible.

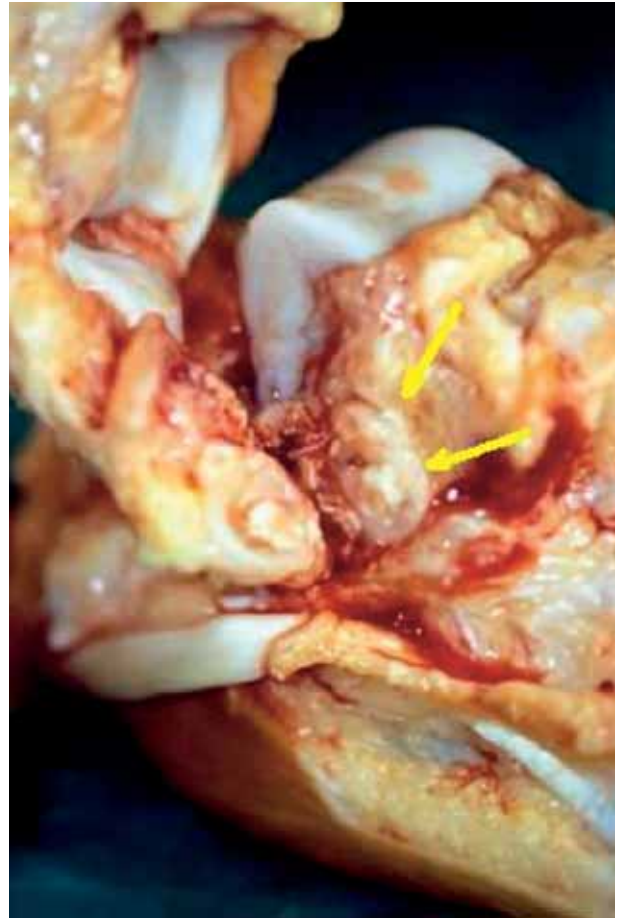

Fig. 4. — Macroscopic image showing extraosseous invasion (arrows).

symptoms and correct diagnosis. This time interval, which ranges from 6 to 48 months, with an average of 28 months (3), is longer in osteosarcoma of the talus than in conventional osteosarcoma (5), in which the diagnosis is frequently made within a few months of symptoms onset. Typical radiological signs can be found in the long bones but not in the talus (9).

The incidence of low-grade osteosarcoma is higher in the foot than elsewhere, and survival rates for osteosarcoma of the foot bones are higher than those reported for the long bones. However, the small number of cases may have influenced the percentages (3, 5).

Osteosarcoma of the foot bones is usually not amenable to limb-sparing surgery because of the poor compartmentalisation of the tumour; hence amputation is required to achieve sound oncologic margins. Enneking (7) considers the foot to be a single compartment and according to the tumour staging criteria, radical surgery with amputation is performed to cure the disease (3, 4, 5, 9).

Osteosarcoma of the foot bones is quite rare, symptoms are non-specific and the age of appearance unusually late. These factors can contribute to a delay of diagnosis. Osteosarcomas affecting the foot are generally low-grade tumours, and survival rates are higher than in classic osteosarcoma.

Nevertheless misdiagnosis and delay in the initiation of an adequate treatment may annihilate this advantage. Clinicians should be aware of this fact and include osteosarcoma in the differential diagnosis of processes involving persistent pain and particularly swelling of the foot.

REFERENCES

1. **Amini M, Colavecchi C.** An unusual case of primary osteosarcoma of the talus. *Clin Orthop* 1980 ; 150 : 217-219.
2. **Berlin SJ.** Statistical analysis of 307,601 tumors and other lesions of the foot. *J Am Podiatr Med Assoc* 1995 ; 85 : 699-703.
3. **Biscaglia R, Gasbarrini A, Böhling T et al.** Osteosarcoma of the bones of the foot. An easily misdiagnosed malignant tumor. *Mayo Clin Proc* 1998 ; 73 : 842-847.
4. **Casadei R, Ferraro A, Ferruzzi A et al.** Bone tumors of the foot : epidemiology and diagnosis. *Chi Organi Mov* 1991 ; 76 : 47-62.
5. **Choong PF, Qureshi AA, Sim FH, Unni KK.** Osteosarcoma of the foot : a review of 52 patients at the Mayo Clinic. *Acta Orthop Scand* 1999 ; 70 : 361-364.
6. **Dahlin DC, Unni KK.** *Bone Tumors* 4th ed. Charles C. Thomas, Springfield, 1986, p 269.
7. **Enneking WF.** *Musculoskeletal Tumor Surgery*. Churchill Livingstone, New York, 1983, pp 719-741.
8. **Jee WH, Choe BY, Ok IY et al.** Recurrent parosteal osteosarcoma of the talus in a 2-year-old child. *Skeletal Radiol* 1998 ; 27 : 157-160.
9. **Matsumoto K, Hukuda S, Ishizawa M et al.** Osteosarcoma of the talus. *Clin Orthop* 1993 ; 296 : 225-228.
10. **Wu KK.** Tumor review : osteogenic sarcoma of the foot. *J Foot Surg* 1987 ; 26 : 269.