



Fracture of the scapular spine in a patient with a Delta III prosthesis

Philippe DEBEER, Filip ROBYNS

From the University Hospital Pellenberg, Pellenberg, Belgium

Isolated scapular spine fractures are rare and are usually associated with other injuries.

We describe a patient with a Delta III shoulder replacement who sustained a displaced ipsilateral fracture of the scapular spine after a fall. Internal fixation of the fracture resulted in excellent pain relief and restoration of the pre-existing shoulder mobility.

Keywords : scapular spine ; fracture ; Delta prosthesis.

INTRODUCTION

Isolated scapular fractures are an unusual finding. We describe the clinical and radiological findings in an 83-year-old woman with a Delta III shoulder prosthesis who sustained a fracture of the scapular spine after a fall. Operative treatment resulted in a good functional outcome.

CASE REPORT

An 83-year-old woman had a Delta III (DePuy, Warsaw, Ind., USA) prosthetic replacement of the right shoulder in January 2004 for a symptomatic cuff tear arthropathy. After this shoulder replacement, pain was absent and the mobility was as follows : abduction 110°, flexion 120°, internal rotation till the level of L3, external rotation 10°. Nine months postoperatively she fell at home onto the right shoulder. She immediately complained of pain and severe loss of function. On examination

we noted a haematoma and local tenderness over the posterior aspect of the acromion and the scapular spine. The mobility of the shoulder was painful and severely restricted. There was no evidence for any other associated injuries. Radiographs revealed a displaced fracture of the scapular spine. All components were stable without any sign of loosening of Delta III prosthetic components (fig 1). A CT scan confirmed these findings (fig 2). Osteosynthesis of the scapular spine was performed using a 7-hole 1/3 tubular plate, contoured over the scapular spine. An excellent reduction and good internal fixation was obtained (fig 3). Post-operatively the patient was placed in a sling for four weeks and only passive range of motion exercises were allowed. After four weeks the sling was discarded and active mobilisation of the shoulder was allowed. Two months postoperatively, the patient was pain free and had regained the same active and passive mobility as before the fall.

■ Philippe Debeer, MD, PhD, Consultant Orthopaedic Surgeon and Senior Clinical Investigator of the Fund for Scientific Research.

■ Filip Robyns, MD, Registrar.

Department of Orthopaedics, University Hospital Pellenberg, Pellenberg, Belgium.

Correspondence : Philippe Debeer, Department of Orthopaedics, University Hospital Pellenberg, Weligerveld 1, B-3212 Pellenberg, Belgium.

E-mail : philippe.debeer@uz.kuleuven.ac.be.

© 2005, Acta Orthopædica Belgica.

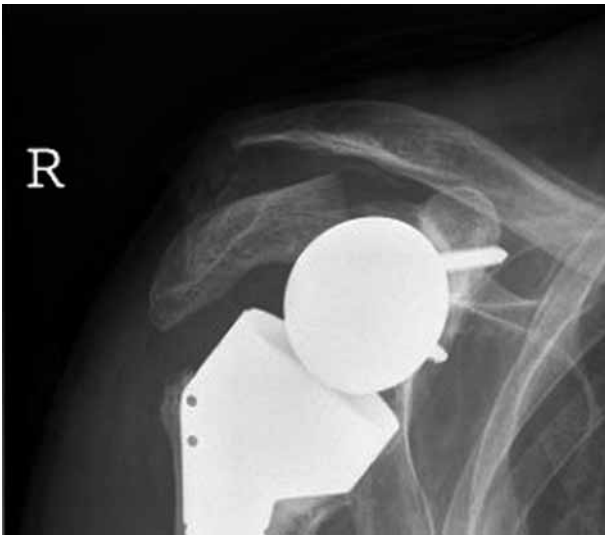

Fig. 1. — Standard radiographs of the right shoulder demonstrating the displaced scapular spine fracture. No loosening or damage to any of the Delta III components is noted.

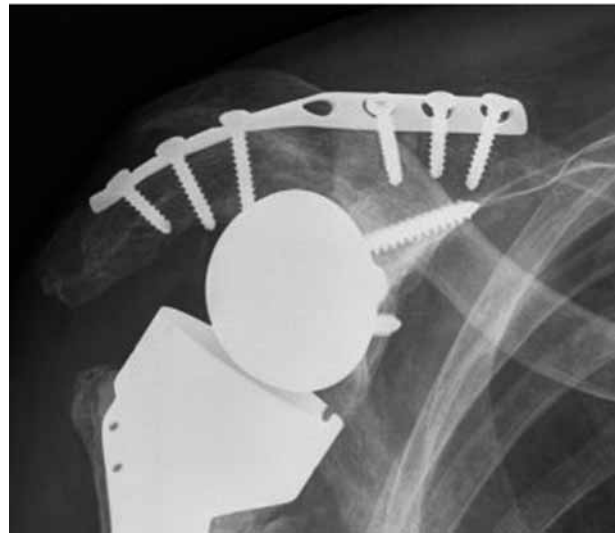


Fig. 3. — Standard radiograph of the right shoulder after internal fixation of the fracture.

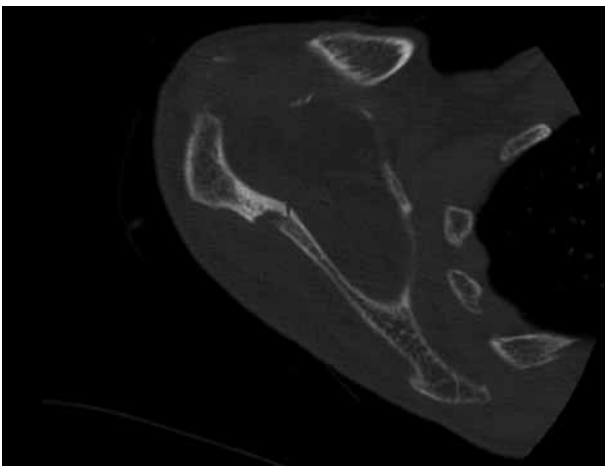
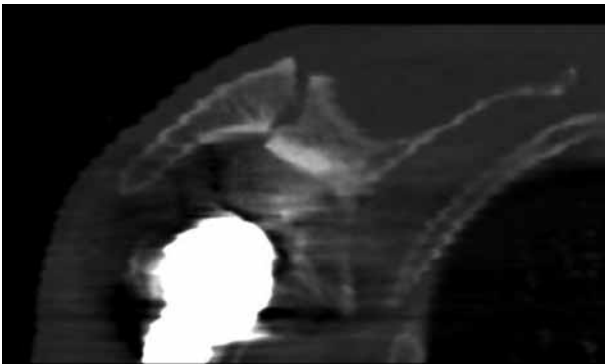


Fig. 2. — CT scan of the right shoulder

DISCUSSION

Isolated fractures of the scapular spine are rare. Usually, they are associated with other fractures of the shoulder girdle or injuries to the head, lungs, ribs, cervical spine and brachial neurovascular structures. We present a patient with a Delta III prosthesis who sustained an isolated fracture of the scapular spine after a fall. The Delta III prosthesis is used to treat patients with symptomatic cuff tear arthropathy. It medialises and lowers the center of rotation and lengthens the lever arm of the deltoid muscle. In this way the deltoid muscle becomes the main mobiliser of the shoulder, and partially compensates for the complete loss of rotator cuff function (2). Displaced fractures of the scapular spine can result in a decrease in the subacromial space, and compromise normal function of the rotator cuff (3, 4). Since our patient had lost rotator cuff function, the mere narrowing of the subacromial space in itself was not troublesome. However, the fracture in this patient resulted in a nearly complete loss of function of the deltoid muscle and therefore conservative treatment was not an option. Open reduction and internal fixation indeed resulted in optimal functioning of the Delta III prosthesis and restoration of the active shoulder mobility.

Posttraumatic fractures of the scapular spine in association with Delta III prostheses have, to our knowledge not been described before. Acromial stress fractures however have been observed and are probably due to a combination of osteoporosis and overtensioning of the deltoid muscle. These fractures are considered fatigue fractures and are mostly incidental radiological findings. No specific treatment is necessary since they are usually asymptomatic (1). In our patient the fracture involved more than just a part of the acromion and the cause was definitely traumatic.

REFERENCES

1. **Boileau P, Watkinson DJ, Hatzidakis AM, Balg F.** Grammont reverse prosthesis : design, rationale, and biomechanics. *J Shoulder Elbow Surg* 2005 ;14 (1 Suppl S) : 147S-161S.
2. **Grammont PM, Baulot E.** Delta shoulder prosthesis for rotator cuff rupture. *Orthopedics* 1993 ; 16 : 65-68.
3. **Jesse RA, Miller ME.** Scapular fractures. Analysis of 113 cases. *Clin Orthop* 1991 ; 269 : 174-180.
4. **Neviasser JD.** Injuries in and about the shoulder joint. *Instr Course Lect* 1956 ; 13 : 187.