



## Prophylactic surgical correction of Crawford's type II anterolateral bowing of the tibia using Ilizarov's method

Hani EL-MOWAFI, Mazen ABULSAAD, Wael EL-ADL

From Mansoura University, Mansoura, Egypt

The treatment of anterolateral bowing with an intact tibia is directed toward prevention of the fracture and subsequent pseudoarthrosis. Patients with anterolateral bowing of the tibia are usually treated with an ankle-foot orthosis until the deformity is improved. There is no documentation that an orthosis can prevent the fracture or correct the deformity, and if the deformity is not corrected, it will result in different mechanical problems.

In this study, 6 legs in 6 patients with anterolateral bowing of the tibia with a narrow sclerotic medullary canal (Crawford type II) were treated using Ilizarov's method. The average age was 6.8 years. All patients underwent correction of the anterolateral bowing by excision of the affected part. If the gap was less than 4 cm, acute shortening followed by bone lengthening was done. If the gap was more than 4 cm, bone transport was preferred.

The mean duration of follow-up was 3.2 years. The anterolateral bowing was corrected in all patients. Complications such as pin track infection, premature consolidation and delayed union at the docking site were encountered.

We believe that Ilizarov's method offers a more efficient solution for this type of deformity than prophylactic orthotic treatment or prophylactic bypass bone graft.

**Keywords :** tibial bowing ; Ilizarov ; distraction osteogenesis.

angulation or bowing is the most common form and is usually associated with other congenital anomalies, such as congenital pseudoarthrosis (7, 8). Children born with prominent bowing of the tibia are an obvious concern to parents and physicians. Managing these congenital angulations requires early and accurate diagnosis (1).

Crawford (2) classified anterolateral bowing into four anatomical groups : type I : Anterolateral bow with a normal medullary canal, type II : Anterolateral bow with a narrow, sclerotic medullary canal, type III : Anterior bowing with a cystic lesion, type IV : Anterolateral bowing with a fracture, cyst, or frank pseudoarthrosis.

Crawford's type I lesion has the best prognosis (the resolving form) and does not require treatment. The remaining three types demonstrate progressive worsening (the nonresolving forms) (3). Once the diagnosis of nonresolving anterolateral bowing of the tibia has been made, the first step is to prevent fracture if possible.

---

■ Hani El-Mowafi, MD, Assistant Professor of Orthopaedic Surgery.

■ Mazen Abulsaad, MD, Lecturer of Orthopaedic Surgery.

■ Wael El-Adl, MD, Lecturer of Orthopaedic Surgery.

Mansoura University Hospital, Mansoura Faculty of Medicine, Mansoura, Egypt.

Correspondence : Hani El-Mowafi, Mansoura University Hospital, 35516 Mansoura, Egypt.

E-mail : hanielmowafi@yahoo.com.

© 2005, Acta Orthopædica Belgica.

---

### INTRODUCTION

Congenital angular deformities of the tibia and fibula are uncommon. Anterior and anterolateral

Table I. — Pre-operative details of 6 patients with anterolateral bowing of the tibia

Case	Sex	Age	Side	Anterior bowing (degrees)	Lateral bowing (degrees)	Shortening (cm)	Crawford classification
1	M	3	L	40	50	3	II
2	M	15	L	20	60	10	II
3	F	4	R	30	50	3	II
4	M	6	L	40	50	4	II
5	F	8	R	30	60	6	II
6	F	6	L	30	45	4	II

Patients with anterolateral bowing of the tibia are usually treated with an ankle-foot orthosis. There are many disadvantages of this form of orthotic prophylactic treatment. The orthoses have to be worn for years until the bowing improves, and residual shortening and bone deformity are unavoidable. Furthermore, there is no documented evidence that orthoses can prevent the fracture or correct the deformity, and if the deformity is not corrected, it will result in mechanical problems (9).

In this study we evaluate the treatment of Crawford's type II anterolateral bowing with excision of the affected part and correction of the shortening with Ilizarov's method.

#### PATIENTS AND METHODS

Six legs in 6 patients (3 boys and 3 girls) with anterolateral bowing were treated in the Orthopaedic Department, Mansoura University Hospital, Mansoura, Egypt from 1997 to 2004 (table I). The average age at time of Ilizarov application was 6.8 years (range : 4 to 15 years). All patients were classified as Crawford type II. The anterolateral bowing angles were measured in both AP and lateral radiographs through drawing the intersection of the mechanical axis of the proximal fragment of the tibia and the mechanical axis of the distal fragment. The average lateral bowing was  $52.5^\circ$  (range : 45 to 60) while the anterior bowing was  $31.7^\circ$  (range : 20 to 40). Leg length discrepancy averaged 5 cm (range : 3 to 10).

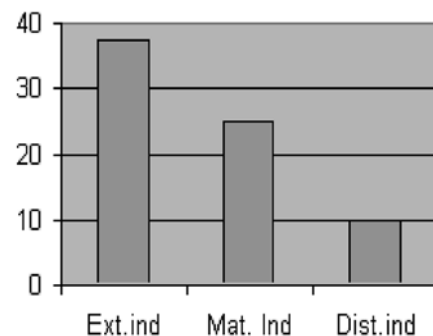
All patients underwent correction of the anterolateral bowing by excision of the affected part. If the defect after excision was less than 4 cm, acute shortening followed by bone lengthening was done (4 patients). The gap was more than 4 cm in 2 patients (6 cm and 10 cm), and bone transport was therefore preferred. Monofocal tibial osteotomy was done in all patients after excision

of the affected segment, and distraction was performed using the Ilizarov external fixator. Distraction was begun 5 days after the operation at a rate of 0.25 mm, four times daily.

The mean duration of fixator application was 6.4 months (range : 5.5 to 11.0). The ring fixator was removed after clinical and radiological union at both distraction sites and the docking site. An orthosis (polymer tibial brace) was used for all patients after removal of the apparatus.

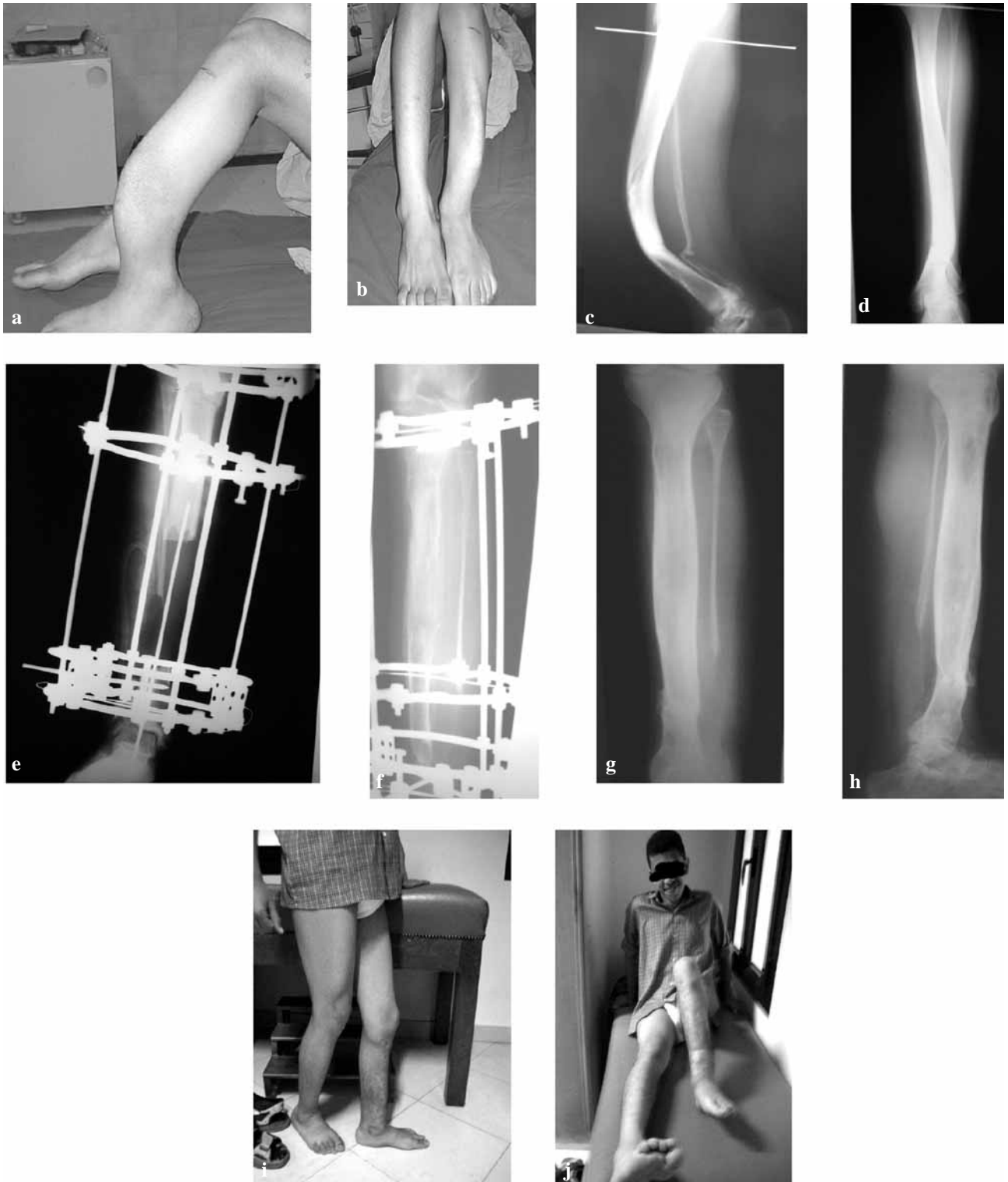Three indices were used to evaluate the results, an external fixation index, a distraction index and a maturation index.

The external fixation index was obtained by dividing the entire duration of external fixation by the length of bone regeneration, the distraction index was obtained by dividing the duration of distraction by the length of bone regeneration, and the maturation index was calculated by dividing the duration of external fixation measured from the completion of distraction to the removal of external fixation by the length of bone regeneration.



Ext. ind. = external fixation index ; Mat. ind. = maturation index ; Dist. ind. = distraction index.

Fig. 1. — The average results of different indices



**Fig. 2.** — A 15 year-old-boy with anterolateral bowing of the left tibia ; a-b) Pre-operative photograph of the patient's leg ; c-d) AP and lateral radiographs demonstrate anterolateral bowing of the left tibia, Crawford's type II lesion ; e) A complete excision of the affected bone segment was done ; f) Follow-up radiograph at final follow-up ; g-h) The deformity is corrected radiologically ; i-j) Clinically.

## RESULTS

The average follow-up period for the 6 patients was 3.2 years (range : 2 to 7). Correction of the deformity was achieved in all patients. The average external fixation index was 37.5 days/cm (range : 35 to 42). The average distraction index was 10 days/cm (range : 9 to 12). The average maturation index was 25 days/cm (range : 20 to 30) (fig 1). Leg length discrepancy was corrected in all cases to less than 0.5 cm, except in one patient, in which the discrepancy was more than 2 cm (the segmental defect was 10 cm).

At the final follow up, there was nearly a full range of knee flexion and extension. The ankle movement ranged from 15° dorsiflexion to 25° plantar flexion. The gait was normal in all patients except in one who had leg length discrepancy of 2.4 cm. No patients complained of pain when walking. Only one patient had occasional aching after strenuous activities. The other five patients had no limitation of their activities and could play sports without discomfort.

There were 3 complications : pin tract infection, premature consolidation and delayed union at the docking site. Pin tract infection in one patient was treated conservatively with antibiotics with complete resolution. Premature consolidation occurred in a patient aged 3 years as we began distraction 5 days after application of the external fixator and it was managed by a further percutaneous osteotomy, resulting in excellent bone regeneration. Delayed union at the docking site in another patient was successfully treated with an iliac crest bone graft.

## DISCUSSION

The natural history of anterolateral bowing of the tibia is extremely unfavourable (except for the resolving form), and once fracture occurs there is little tendency for the lesion to heal spontaneously (12). Sponseller (9) claimed that once the diagnosis of nonresolving anterolateral bowing of the tibia has been made, prophylactic bracing should be attempted, although there is no documented evidence that such prophylaxis can prevent frac-

ture. According to Tachdjian, protection of the unfractured bowed tibia should be continued indefinitely until fracture occurs or the patient approaches skeletal maturity (11). In this study, we observed that spontaneous correction of the deformity did not occur in patients with Crawford type II anterolateral bowing. The deformity became more severe with age, and subsequent ankle deformity with ankle pain and knee pain developed owing to the disturbance of the mechanical axis of tibia.

Prophylactic bone grafting has been used for the deformed tibia before a pathologic fracture occurs. This was thought to strengthen the deformed tibia and decrease the risk of pathologic fracture. The results of prophylactic bypass bone grafting are controversial. Lloyd-Roberts and Shaw (4) reported success in only three of their seven patients, while Tachjian (11) reported success in all five children treated. Recently, Strong and Wong-chung (10) prevented fractures in six of nine children with a pre-pseudarthrosis secondary to neurofibromatosis. Many authors, however, reported that bypass grafting has two unattractive features ; the normal leg is disturbed, and no attempt is made to correct the deformity (4, 6). In this study, excision of the affected soft tissue and bone extended well into healthy soft tissue and bone. Distraction osteogenesis using Ilizarov's method compensated for the defect, while also correcting the deformity and restoring the mechanical axis of the tibia.

In this study, the external fixation index appeared to be similar to the index reported in the literature for lengthening of healthy bone (5, 13), suggesting that after removal of the affected tissue, the remaining bone is normal.

## CONCLUSIONS

Based on our experience, we believe that the technique used offers a more efficient solution to treat Crawford type II anterolateral bowing of the tibia than prophylactic orthotic treatment or prophylactic bypass bone grafting. Few studies have been published on this subject and further research is needed.

## REFERENCES

1. **Briggs RG, Carlson WO.** Angular deformities of the tibia in children : a review of three cases. *S D J Med* 1990 ; 43 : 5-9.
2. **Crawford AH.** Neurofibromatosis in childhood. *Instr Course Lect* 1981 ; 97 : 56-60.
3. **Hofmann P, Galanski M.** Congenital bowing of the tibia in von Recklinghausen's neurofibromatosis. *ROFO Fortschr Geb Rontgenstr Nuklearmed* 1976 ; 125 : 417-421.
4. **Lloyd-Roberts GC, Shaw NE.** The prevention of pseudarthrosis in congenital kyphosis of the tibia. *J Bone Joint Surg* 1969 ; 51-B : 100-105.
5. **Monticelli G, Spinelli R.** Leg lengthening by closed metaphyseal corticotomy. *J Orthop Traumatol* 1983 ; 9 : 139-150.
6. **Morrissy RT, Riseborough EJ, Hall JE.** Congenital pseudarthrosis of the tibia. *J Bone Joint Surg* 1981 ; 63-B : 367-372.
7. **Pappas AM.** Congenital posteromedial bowing of the tibia and fibula. *J Pediatr Orthop* 1984 ; 4 : 525- 531.
8. **Rathgeb JM, Ramsey PL, Cowell HR.** Congenital kyphoscoliosis of the tibia. *Clin Orthop* 1974 ; 103 : 178-185.
9. **Sponseller PD.** Localized disorders of bone and soft tissue. In : Morrissy RT, Weinstein SL (eds). *Pediatric Orthopaedics, ed 4.* Lippincott-Raven, Philadelphia, 1996 ; p 305.
10. **Strong ML, Wong-chung J.** Prophylactic bypass grafting of the prepseudarthrosis tibia in neurofibromatosis. *J Pediatr Orthop* 1991 ; 11 : 757-764.
11. **Tachdjian MO.** The foot and leg. In : Tachdjian MO (ed). *Pediatric Orthopaedics, 2<sup>nd</sup> ed,* WB Saunders Co, Philadelphia, 1990 ; p 2810.
12. **Tuncay IC, Johnston CE II, Birch JG.** Spontaneous resolution of congenital anterolateral bowing of the tibia. *J Pediatr Orthop* 1994 ; 14 : 599-602.
13. **Yun AG, Severino R, Reinker K.** Attempted limb lengthening beyond twenty percent of the initial bone length : results and complications. *J Pediatr Orthop* 2000 ; 20 : 151-159.