



Primary hip arthroplasty through a limited posterior trochanteric osteotomy

Joaquin SANCHEZ-SOTELO, John GIPPLE, Daniel BERRY, Charles ROWLAND, Robert COFIELD

From the Mayo Clinic Rochester, Minnesota, USA

This study evaluates primary hip replacement performed using a modified posterior approach through a limited posterior trochanteric osteotomy bone block that includes the insertions of the posterior capsule and short external rotators – as this may enhance secure reattachment of the posterior soft-tissue envelope and protect against postoperative instability. Sixty-eight consecutive primary hip replacements performed through a posterior trochanteric osteotomy were prospectively followed. Two were lost to follow-up before a minimum of 2 years after the arthroplasty ; the remaining 66 hips were followed for a mean of 10 years (range : 2 to 15). The median Harris hip score improved from 43 to 84 points ($p < 0.0001$). Radiographic union of the osteotomy was confirmed in 64 hips (94%). Two episodes of early dislocation occurred 5 days and 8 months postoperatively ; both were successfully managed nonoperatively without continuing instability. There were no cases of late instability. Posterior approach to the hip joint through a posterior trochanteric osteotomy is associated with high union rates and a low rate of late instability after hip replacement.

Keywords : total hip arthroplasty ; posterior approach ; trochanterotomy.

INTRODUCTION

Most primary hip replacements are performed currently through either an anterolateral or a posterior approach (1). The main disadvantage of the anterolateral approach is the need to release and repair a portion of the hip abductor mechanism.

This has been associated with an increased risk of heterotopic bone formation, a more prolonged limp after arthroplasty, and occasionally permanent abductor dysfunction secondary to the failure of the abductors to heal to the trochanter or to injury to the superior gluteal nerve (1, 11, 14, 15). The main disadvantage of the posterior approach is the higher rate of postoperative instability identified in multiple series (5, 11). Dislocation remains a common complication after primary hip replacement. Most studies of primary total hip arthroplasty (THA) report a prevalence of 1 to 5% (12).

Although several factors may be implicated in the higher dislocation rate after a posterior approach to the hip, the lack of a competently healed posterior capsule and external rotator muscle group that would provide a barrier to posterior dislocation and a checkrein to excessive internal

■ Joaquin Sanchez-Sotelo, MD, PhD, Orthopaedic Surgeon.

■ John R. Gipple, MD, Orthopaedic Surgeon.

■ Daniel J. Berry, MD, Orthopaedic Surgeon.

■ Robert H. Cofield, MD, Orthopaedic Surgeon.

Department of Orthopedic Surgery, Mayo Clinic Rochester, Minnesota, USA.

■ wCharles M Rowland, BS, Biostatistician.

Division of Biostatistics, Mayo Clinic Rochester, Minnesota, USA.

Correspondence : Robert H. Cofield MD, Mayo Clinic, 200 First Street SW, Rochester, MN 55905, USA.

E-mail : Cofield.Robert@mayo.edu.

© 2005, Acta Orthopædica Belgica.

hip rotation is probably a major contributing issue (2, 8, 10). Secure repair of these posterior structures at the end of the procedure has been reported to decrease the rate of early instability after arthroplasty (2, 8, 10). The influence of this technical modification on late instability is unknown (3, 13).

Since 1984, all primary hip arthroplasties performed by the senior author have been approached through a posterior trochanteric osteotomy (7, 12). This approach detaches the hip external rotators and posterior capsule through trochanteric bone and may provide a more reliable method to reestablish the integrity of the posterior soft-tissue envelope and decrease the rate of instability after a posterior approach. The purpose of this study was to determine the incidence of early and late instability and the union rate of the trochanteric fragment when primary hip replacement is performed using this approach.

MATERIAL AND METHODS

Patients

From 1984 to 1990, 68 consecutive primary hip arthroplasties in 58 patients were performed at our institution by the senior author (RHC) through a posterior trochanteric osteotomy. Two patients were lost to follow-up before a minimum of 2 years after the arthroplasty. The remaining 56 patients (66 hips) were followed for a mean of 10 years (range : 2 to 15). The most recent follow-up was by examination in 33 hips, mailed questionnaire in 26 hips and telephone questionnaire in 7 hips. All patients had anteroposterior and lateral radiographs at the time of the most recent evaluation.

There were 27 men and 29 women. Their mean age at the time of the arthroplasty was 62 years (range : 30 to 85) and their mean weight was 76.5 kg (range : 41 to 115). The underlying diagnosis was osteoarthritis in 42 hips, rheumatoid arthritis in 15 hips, avascular necrosis in 7 hips, and ancient sepsis in 2 hips. Three patients had undergone one previous surgical procedure ; the two patients with ancient sepsis had required hip debridement during childhood, and one patient with osteoarthritis had had removal of a portion of the labrum and a partial synovectomy.

Cement was used for fixation of both components in 39 hips. All cemented acetabular components were metal-backed Ti-Bac cups (Zimmer, Warsaw, Indiana)

and all cemented femoral components were Harris Precoat stems (Zimmer, Warsaw, Indiana). Uncemented Harris-Galante (Zimmer, Warsaw, Indiana) acetabular and femoral components were implanted in the remaining 27 arthroplasties. So-called hybrid fixation was not used in any hip. A 28-mm femoral head was used in all cases.

Surgical Technique

The patient is positioned in the lateral decubitus position. A straight skin incision is made along a line centered over the junction of the posterior and middle thirds of the greater trochanter. The fascia lata and superficial fascia of the gluteus maximus are incised, and the gluteus maximus is split with electrocautery following the same line.

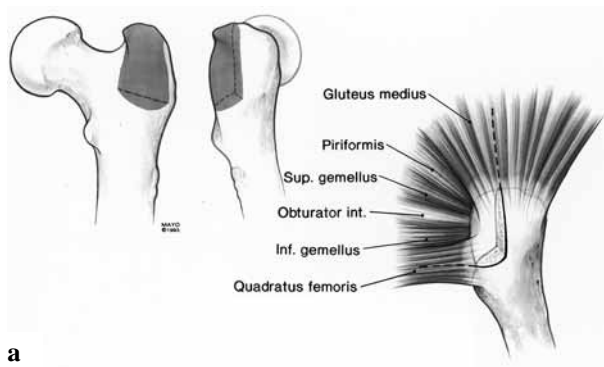
The attachment sites of the gluteus medius and short external rotators on the greater trochanter are identified (fig 1a). A vertical and a short transverse osteotomies of the posterior one centimeter of the greater trochanter are performed with an osteotome avoiding injury to the insertion of the external rotators and posterior capsule on the trochanteric fragment (fig 1b) (7, 12). The gluteus medius and superior capsule are divided proximally in line with the vertical portion of the osteotomy between 3 and 4 cm. Care should be taken not to extend this division more than 5 cm proximal to the tip of the trochanter to avoid injury to the superior gluteal neurovascular bundle (13). The superior and inferior portions of the capsule are divided as necessary, the femoral head is dislocated posteriorly and the arthroplasty is performed.

Following completion of the arthroplasty, the posterior trochanteric bone block is anatomically reduced and fixed with three #5 braided nonabsorbable Mersilene sutures (Ethicon, Somerville, NJ) placed through bone (fig 1c). The proximal split in the abductors is reinforced with multiple #2 absorbable sutures and the remaining closure is routine.

The posterior trochanteric osteotomy does not require modifications of the usual postoperative regimen after hip replacement. In the authors' practice, partial weight bearing with the help of a walker or two crutches is generally maintained for the first 6 postoperative weeks and weight bearing is then advanced as tolerated.

Evaluation

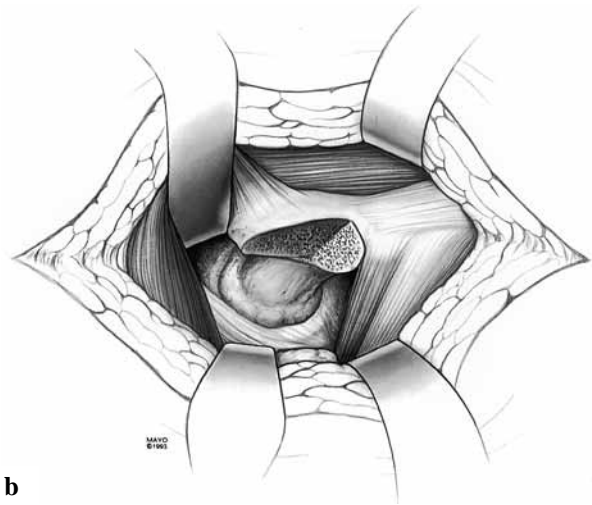
All primary hip replacements performed at our institution are followed prospectively at 1, 2, 5, 7, and 10 years and every 5 years thereafter. Patients unable to



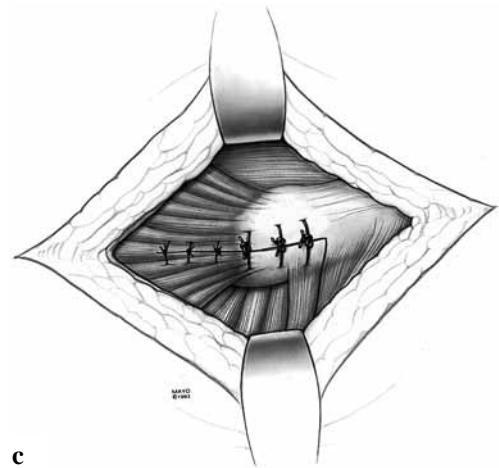
a

Fig. 1. — *a*) The positioning of the posterior trochanteric osteotomy with its relationship to the surrounding muscles. The osteotomy is typically 1 cm from medial to lateral. The inner aspect of the vertical osteotomy should exit just posterior to the femoral neck. The transverse portion of the osteotomy is angled slightly from inferolateral to superomedial to eliminate or minimise intrusion on the remaining femoral neck.

b) The trochanteric fragment along with the hip external rotators and posterior hip capsule is retracted posteriorly exposing the hip joint. The superior and inferior portions of the hip capsule are divided as necessary. Following dislocation of the hip and femoral neck osteotomy, the anterior portion of the capsule is divided at the acetabular rim if a contracture is present. *c*) After completion of the arthroplasty, the trochanteric fragment is secured with three #5 nonabsorbable sutures through bone. The proximal split in the abductor muscles is also repaired.



b



c

return for a physical examination are interviewed with a questionnaire by mail or telephone and are requested to send radiographs. This clinical information was collected by an observer independent of the surgeon. At each time point, patients are specifically asked if their replaced hip has dislocated. We retrospectively reviewed the charts and radiographs of those patients included in this study to collect pertinent clinical and radiographic information. Modified Harris hip scores (4) were derived from the clinical data. The immediate postoperative and most recent true lateral radiographs of the affected hip were analysed by a single observer (JRG) independent of the surgeon to assess the position and union of the osteotomised fragment (fig 2a to d). The differences between preoperative and postoperative clinical evaluations were performed with the Wilcoxon rank sum test. The level of significance was established at $p < 0.05$ for all comparisons.

RESULTS

Intraoperative complications were limited to three intraoperative cracks of the femoral metaphysis during the insertion of an uncemented femoral component and one small posterocentral acetabular perforation during reaming. None of these fractures were related to the posterior trochanteric osteotomy. No greater trochanteric fractures occurred.

Two patients had a single episode of early postoperative instability. A 49-year-old patient with ancient septic arthritis sustained a posterior dislocation 8 months postoperatively while jumping 4 feet from a tractor. The dislocation was treated with closed reduction and did not recur. This patient underwent revision of his acetabular component for wear and osteolysis 12 years after the

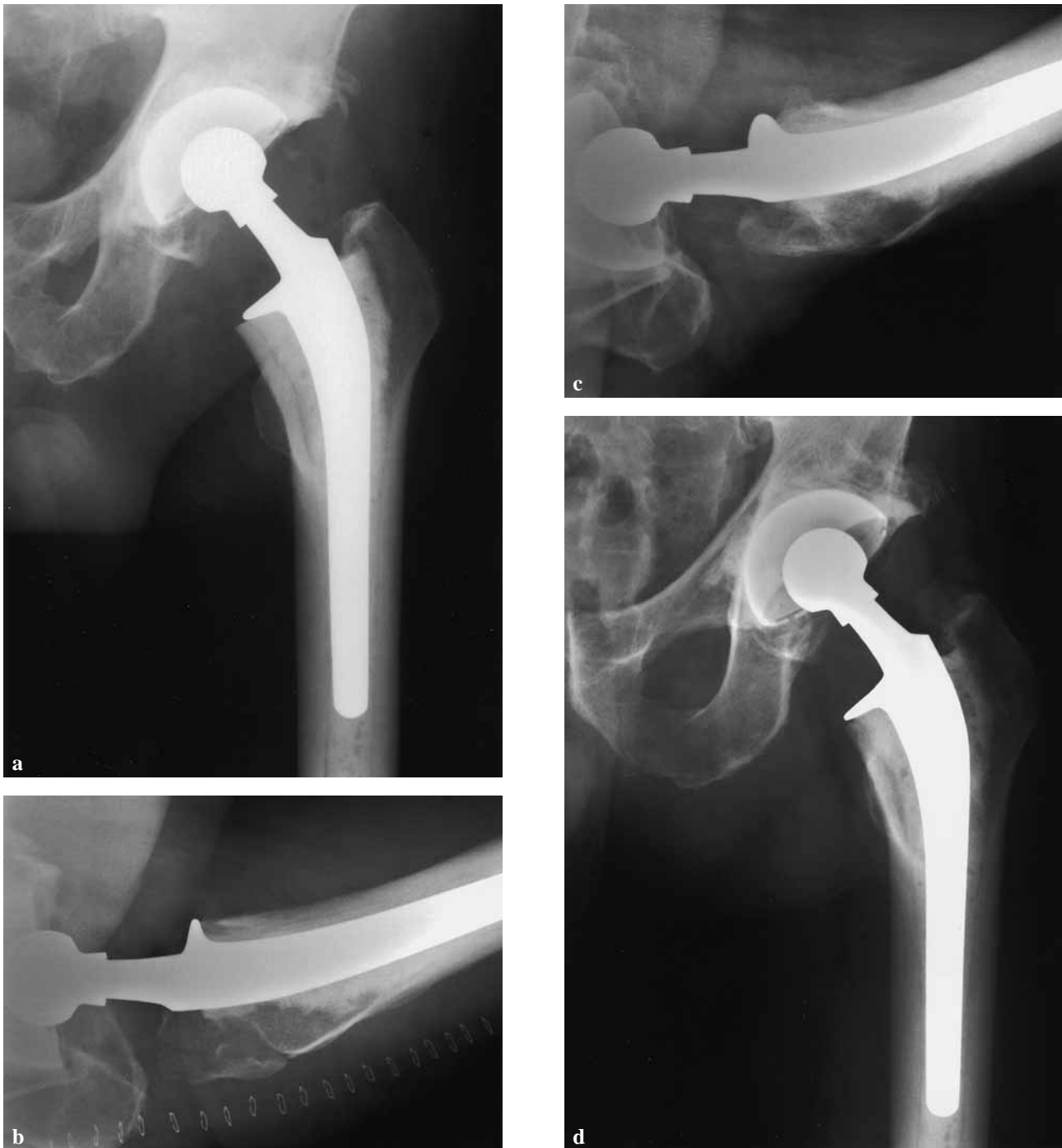

Fig. 2. — *a, b*) Anteroposterior and lateral views obtained immediately following hip arthroplasty performed through the posterior approach using a posterior trochanteric osteotomy. The osteotomy site is clearly visible on the lateral view. *c, d*) Radiographs of the same patient 2 years later showing union of the trochanteric osteotomy fragment but some degree of proximal migration (see text).

index arthroplasty. A 64-year-old patient with rheumatoid arthritis sustained a posterior dislocation on postoperative day 5 treated with closed reduction. She dislocated three more times within the first 2 months, all treated with closed reduction and eventually with a hip spica cast for 6 weeks. She had one recurrence 4 years later. There have been no further recurrences with 10 additional years of follow-up. There were no other cases of recurrent or late instability.

Two additional patients required a reoperation. One patient developed a superficial wound infection 2 weeks after surgery that resolved with surgical debridement and antibiotics. Another patient underwent revision surgery for loosening of a cemented acetabular component 11 years after the index procedure. One patient developed symptomatic deep venous thrombosis.

Hip replacement was associated with improved function. The median Harris hip score improved from 43 points (range : 16 to 70) preoperatively to 84 points (range : 40 to 97 points) at most recent follow-up ($p < 0.0001$). At most recent follow-up, 63 hips had no or mild pain, 2 had moderate, and 1 had severe pain, including 2 who underwent revision of loosened acetabular components and 1 other patient for whom the source of pain is unclear – having an excellent physical examination, functional capability and radiographs without changes except for mild polyethylene wear.

Surgery was associated with an increase in mean hip flexion, from 90° (range : 35 to 115) preoperatively to 100° (range : 75 to 130) at most recent follow-up ($p = 0.03$). Forty-eight patients had no or slight limp at most recent follow-up evaluation. Eight patients had moderate (5 hips) or severe (3 hips) limp ; in four of these eight hips the limp was attributed to dysfunction of other lower extremity joints. One of the 32 unrevised patients examined at most recent follow-up had a positive Trendelenburg sign.

The trochanteric osteotomy healed in a satisfactory position in most of the hips. Mean migration of the trochanteric fragment was 1 mm (range : 0 to 15). The fragment migrated proximally more than 10 mm in four patients. In two of them, the fragment united in the displaced position. In the other

two, it failed to unite. No specific risk factors for nonunion could be identified in these two patients. There were no other nonunions of the osteotomy. None of the patients with proximal migration greater than 10 mm or nonunion had instability or pain ; of those examined none had a limp or a Trendelenburg sign.

DISCUSSION

The ideal surgical approach for primary hip replacement continues to be debated (6, 11). Anterolateral approaches require division and detachment of variable portions of the gluteus medius and minimus. Release of the hip abductors is associated with more prolonged limp after arthroplasty and can result in permanent dysfunction of this muscle group (1, 11, 14). Posterior surgical approaches leave the abductors undisturbed but have been associated classically with a higher rate of postoperative instability (5, 11). Over the last decade, there has been a growing interest in modifying the posterior approach in order to decrease instability rates (2, 8, 10).

In the initial series of hip replacement performed through a posterior approach, the detached posterior capsule and external rotators were not repaired at the end of surgery (10). Although some authors have suggested that the higher instability rate associated with the posterior approach is related to poor positioning of the acetabular component (9), several cadaveric and clinical studies suggest that the integrity of the posterior soft-tissue structures is the critical factor for early stability after arthroplasty through a posterior approach (2, 8, 11).

Several studies have addressed the effect of repairing the posterior structures on postoperative instability. Pellici and Poss (10) reported a decrease in their dislocation rate from 4% and 6.2% to 0% and 0.8% respectively after using an enhanced posterior soft tissue repair. Similar results have been reported by Chiu *et al* (2) for primary THA and Ko *et al* (8) for hemiarthroplasty. These studies show that repair of the posterior capsule and external rotators after a posterior approach to the hip has a beneficial effect on early postoperative instability. The effect that these modifications of the posterior

approach may have on late instability is unknown (3, 13).

An alternative strategy to maximise the integrity of the posterior soft-tissue envelope after arthroplasty through a posterior approach is to detach the posterior capsule and external rotators with a segment of bone from the posterior trochanteric insertion. The senior author adopted this approach for hip replacement because bone-to-bone fixation and healing after arthroplasty may result in a more reproducible technique to reestablish the checkrein effect of the posterior capsule and external rotators.

The posterior trochanteric osteotomy was first described by Iyer in 1981 (7). In the cadaveric part of his study, Iyer found more resistance to hip dislocation with the posterior trochanteric osteotomy compared to the classic Austin-Moore approach. He also reported on 15 femoral neck fractures treated with a hemiarthroplasty through a posterior trochanteric osteotomy; there were no postoperative dislocations and the trochanteric fragment healed radiographically in the nine hips that had sufficient follow-up. Shaw reported on five primary and eight revision hip replacements performed through a posterior trochanteric osteotomy and found no complications associated with the procedure and specifically no dislocations or osteotomy nonunions (12).

The exposure provided by this approach is similar to that obtained with other posterior approaches and does not compromise the positioning and fixation of the components. The results of our study suggest that exposure of the hip joint through a posterior trochanteric osteotomy is associated with few complications and a high union rate. The rate of early postoperative instability using this approach is within the range reported in the literature (12). However, this approach seems to be associated with less recurrent and late instability after a mean follow-up of 10 years (range: 2 to 15). Although wire and screw fixation of the trochanteric osteotomy have been recommended by others (7, 12), we have found fixation with heavy nonabsorbable sutures secure enough. One disadvantage of the posterior trochanteric osteotomy is the potential for injury to the superior gluteal nerve if the gluteus medius muscle split is extended prox-

imally more than 5 cm from the tip of the trochanter. The frequency of abductor weakness and a positive Trendelenburg sign was uncommon in this patient group but may be underestimated as only 33 out of 68 hips were examined 2 years or more after the surgical procedure.

In conclusion, the posterior approach to the hip joint through a limited posterior trochanteric osteotomy provides good exposure and secure reattachment of the posterior soft-tissue envelope, is associated with a high union rate, and a low frequency of late instability. These advantages have to be balanced against little if any reduction in the rate of early instability and the uncommon osteotomy nonunion that could be associated with a degree of abductor weakness.

REFERENCES

1. **Bischoff R, Dunlap J, Carpenter L et al.** Heterotopic ossification following uncemented total hip arthroplasty. Effect of the operative approach. *J Arthroplasty* 1994; 9: 641-644.
2. **Chiu FY, Chen CM, Chung TY et al.** The effect of posterior capsulorrhaphy in primary total hip arthroplasty: a prospective randomized study. *J Arthroplasty* 2000; 15: 194-199.
3. **Coventry MB.** Late dislocations in patients with Charnley total hip arthroplasty. *J Bone Joint Surg* 1985; 67-A: 832-841.
4. **Harris WH.** Traumatic arthritis of the hip after dislocation and acetabular fractures: treatment by mold arthroplasty. An end-result study using a new method of result evaluation. *J Bone Joint Surg* 1969; 51-A: 737-755.
5. **Hedlundh U, Hybbinette CH, Fredin H.** Influence of surgical approach on dislocations after Charnley hip arthroplasty. *J Arthroplasty* 1995; 10: 609-614.
6. **Horwitz BR, Rockowitz NL, Goll SR et al.** A prospective randomized comparison of two surgical approaches to total hip arthroplasty. *Clin Orthop* 1993; 291: 154-163.
7. **Iyer KM.** A new posterior approach to the hip joint. *Injury* 1981; 13: 76-80.
8. **Ko CK, Law SW, Chiu KH.** Enhanced soft tissue repair using locking loop stitch after posterior approach for hip hemiarthroplasty. *J Arthroplasty* 2001; 16: 207-211.
9. **McCullum DE, Gray WJ.** Dislocation after total hip arthroplasty. Causes and prevention. *Clin Orthop* 1990; 261: 159-170.
10. **Pellicci PM, Bostrom M, Poss R.** Posterior approach to total hip replacement using enhanced posterior soft tissue repair. *Clin Orthop* 1998; 355: 224-228.

11. Ritter MA, Harty LD, Keating ME *et al.* A clinical comparison of the anterolateral and posterolateral approaches to the hip. *Clin Orthop* 2001 ; 385 : 95-99.
12. Sanchez-Sotelo J, Berry DJ. Epidemiology of instability after total hip replacement. *Orthop Clin North Am* 2001 ; 32 : 543-552.
13. Shaw JA. Experience with a modified posterior approach to the hip joint. A technical note. *J Arthroplasty* 1991 ; 6 : 11-18.
14. von Knoch M, Berry DJ, Harmsen WS *et al.* Late dislocation after total hip arthroplasty. *J Bone Joint Surg* 2002 ; 84-A : 1949-1953.
15. Weber M, Berry DJ. Abductor avulsion after primary total hip arthroplasty. Results of repair. *J Arthroplasty* 1997 ; 12 : 202-206.