



## Osteochondritis dissecans of the humeral head : clinical and radiological findings

Philippe DEBEER, Peter BRYs

*From the University Hospital Pellenberg, Pellenberg, Belgium*

**Osteochondritis dissecans (OCD) is a common condition in the knee, the elbow and the talus. It is rarely diagnosed in the humeral head. We report the case of a young male patient with OCD of the right humeral head and discuss the clinical and radiographic findings.**

**Keywords :** humeral head ; osteochondritis dissecans.

### INTRODUCTION

Osteochondritis dissecans (OCD) is commonly seen in the knee, the elbow and the dome of the talus. It is rarely diagnosed in the humeral head. The aetiology and the treatment of this condition remain unclear. Several factors play a role in the aetiology of OCD of the proximal humerus. Local ischaemia, constitutional predisposition, abnormal ossification and trauma have been proposed as aetiological factors. A major trauma is seldom seen, but repeated minor trauma (e.g. repetitive use of the shoulder in sporting activities) in the physically active individual can result in OCD.

Here we discuss the clinical and radiological findings in a young man with OCD of the humeral head.

### CASE REPORT

An otherwise healthy 17-year-old right-handed male presented with a one week history of right shoulder pain. During a fight one week earlier his

right arm was pulled backwards and since then he complained of pain in the right shoulder irradiating posteriorly to the right periscapular region. Prior to the injury, he had never complained of shoulder pain.

Initial physical examination of the right shoulder revealed a limited range of motion with a painful arc. Impingement tests were positive. He demonstrated no signs of instability. There was a good strength in the rotator cuff muscles. There was no swelling or tenderness but there was clear winging of the right scapula.

Standard radiographic examination showed a loss of sphericity with depression and irregular lining of the subchondral bone in a zone with a length of 16 mm in the central part of the humeral head (fig 1). Transverse CT images better demonstrated an irregular defect in the subchondral bone bordered by a thin sclerotic rim with only minimal sclerosis of the underlying trabecular bone (fig 2).

---

■ Philippe Debeer, MD, PhD, Consultant Orthopaedic Surgeon, Professor in Orthopaedics.

*Department of Orthopaedics, University Hospital Pellenberg, Weligerveld 1, B-3212 Pellenberg, Belgium.*

■ Peter Brys, MD, Consultant Radiologist.

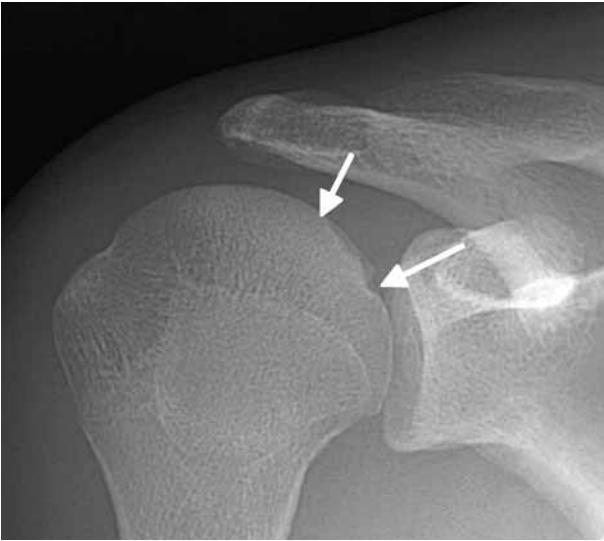
*Department of Radiology, University Hospital Pellenberg, Weligerveld 1, B-3212 Pellenberg, Belgium.*

Correspondence : Philippe Debeer, Department of Orthopaedics, University Hospital Pellenberg, Weligerveld 1, B-3212 Pellenberg, Belgium.

E-mail : philippe.debeer@uz.kuleuven.ac.be.

© 2005, Acta Orthopædica Belgica.

---

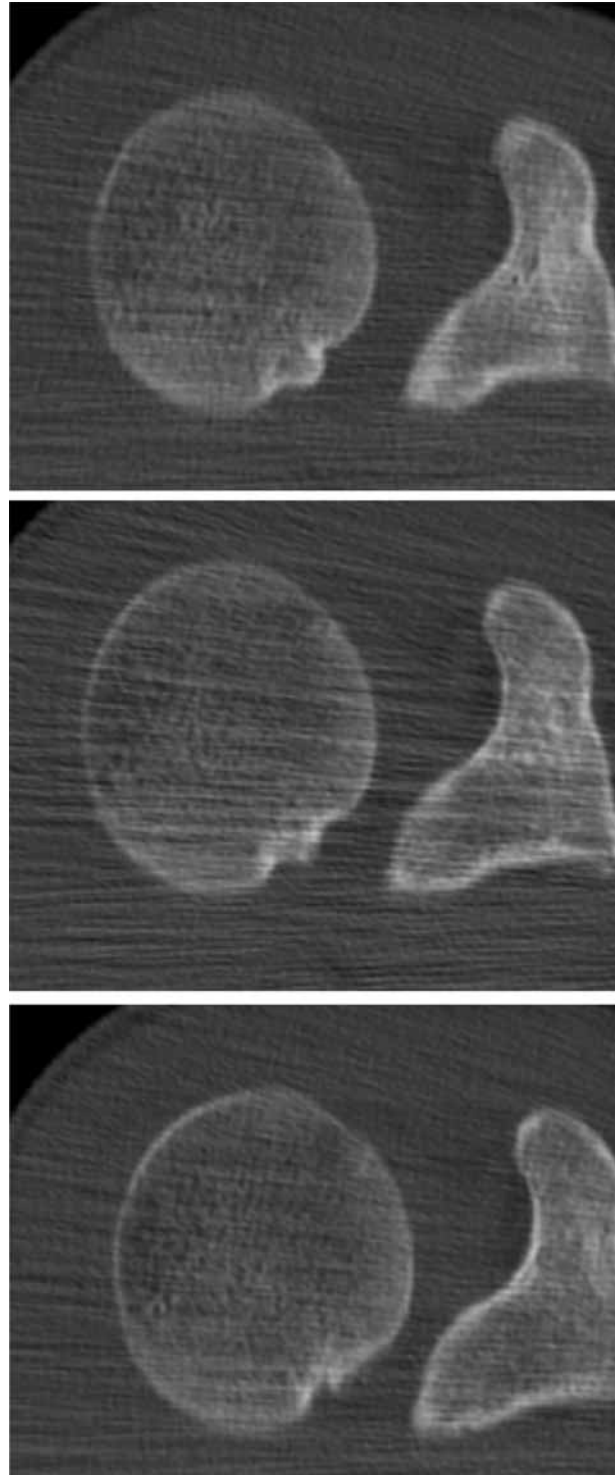


**Fig. 1.** — Standard radiograph showing focal loss of sphericity in the central part of the humeral head with depression and irregular lining of the subchondral bone in a zone with a length of 16 mm (arrows).

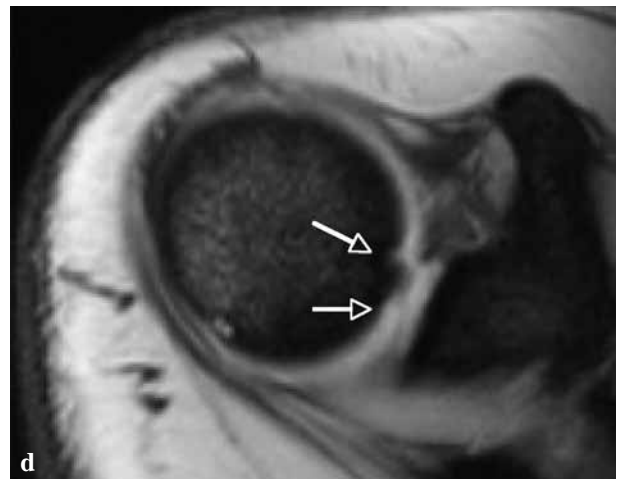
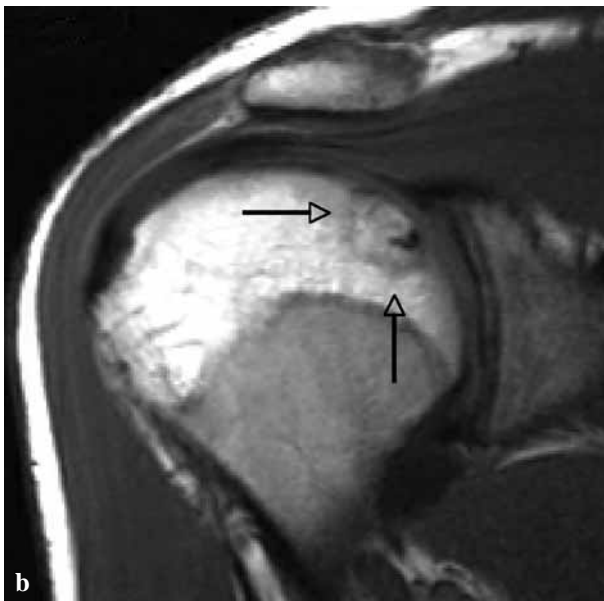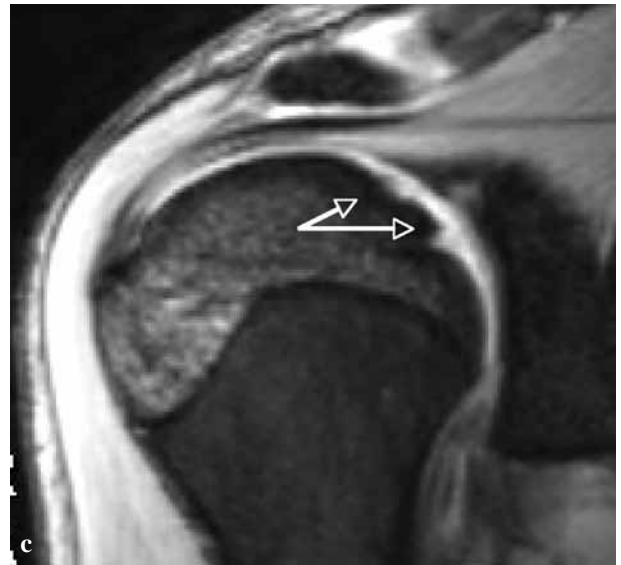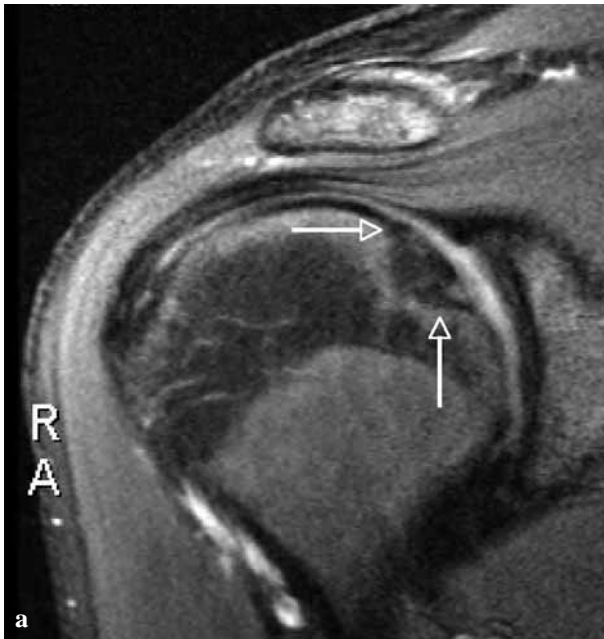
Subsequently, an MR examination was performed (fig 3). On fat-suppressed T2-weighted fast spin-echo images (fig 3a) neither bone marrow oedema nor intra-articular fluid could be demonstrated. T2- and T1-weighted images (fig 3b) showed the presence of normal fatty bone marrow underlying the lesion. On Gradient Echo (GE) sequences (figs 3c and d) there was no loss of overlying cartilage. In addition on GE-images the defect seemed to be filled in with hyaline cartilage or cartilage-like tissue.

Electromyographic (EMG) studies confirmed elongation injury of the long thoracic nerve explaining the observed scapular winging. Based on the radiologic and electromyographic findings we concluded that the OCD lesion in the humeral head was a healed lesion that was not caused by the recent trauma and therefore did not necessitate any specific surgical treatment. The elongation of the long thoracic nerve on the other hand was clearly posttraumatic and scapular stabilising exercises were started.

At 6 months follow-up, the patient had a normal range of motion and was pain-free. The scapular winging had disappeared almost entirely and the



**Fig. 2.** — Computed tomography demonstrating the irregular defect in the subchondral bone bordered by a thin sclerotic rim with only minimal sclerosis of the underlying trabecular bone.



**Fig. 3.** — MR examination

a) Oblique coronal fat-suppressed T2-weighted FSE image showing absence of bone marrow oedema and of intra-articular fluid as well as the presence of normal fatty bone marrow underlying the lesion (arrows) ; b) Oblique coronal T1-weighted image showing the presence of normal fatty bone marrow underlying the lesion (arrows) ; c-d) Oblique coronal (c) and transverse (d) Gradient Echo image showing absence of loss of overlying cartilage and suggesting filling in of the defect with hyaline cartilage or cartilage-like tissue (arrows).

patient had resumed all his physical activities. A further EMG at this time confirmed active regeneration in the long thoracic nerve.

### DISCUSSION

OCD of the humeral head is very rare. It is usually diagnosed in the elbow, the knee or the talus. We only found 11 other case reports (1, 3-7, 9-12)

describing OCD of the humeral head (table I). All these patients were male, as was our patient, except for one. The dominant side was involved in 11 cases, including ours. The diagnosis of OCD was made by standard radiographs, CT or MRI scans. As can be

Table I. — Characteristics of previously reported humeral head OCD cases compared to our case

Reference	Sex	Localisation	Sports	Trauma	Treatment
(1)	M	Superior	?	No	Immobilisation
(3)	M	Superior	Handball	No	Drilling
(3)	F	Bilateral ; superior	No	No	None
(4)	M	Posterosuperior	No	No	Removal, curettage, drilling
(5)	M	Medioinferior	Tennis	Yes	Removal, curettage
(6)	M	Anterosuperior	?	Yes	Removal, curettage, drilling
(7)	M	Posterosuperior	No	Yes	Osteochondral allograft
(9)	M	Anterosuperior	?	Yes	Removal, curettage, drilling
(10)	M	Anterosuperior	Tennis	No	Rest
(11)	M	Anterosuperior	Boxing	Yes	Rest
(12)	M	Posteromedial	?	Yes	Removal, curettage, drilling
Our case, 2005	M	Central	No	No	None

seen in table I, the antero-superior part of the humeral head seems to be the preferred localisation of OCD. In cases where an operation was performed, histological analysis confirmed the diagnosis.

The aetiology of OCD remains controversial but review of the literature indicates that a combination of trauma or repetitive microtrauma and a local disturbance of the blood supply can result in an osteochondral fracture (8). Spontaneous or traumatic dissection of this osteochondral fragment may occur and the loose body can give rise to episodes of trapping, synovitis and pain. A history of trauma or repetitive microtrauma due to sports activities was present in 8 of the 11 previously published cases. Four patients, including ours, had no apparent causative factor for OCD. Although our patient sustained a traction injury to the right shoulder, we do believe that the OCD was an incidental finding. The absence of pain prior to this traction injury and the absence of oedema in the bone confirmed the diagnosis of a healed osteochondritis dissecans lesion in the humeral head.

On plain radiographs, OCD in its evolutive stage is typically recognised as a sclerotic subchondral bone fragment separated from the underlying bone by a thin radiolucent crescentic line. On MR imaging, the osteochondritis site demonstrates low signal intensity on T1- and T2-weighted images. The presence of subchondral fluid implies fissuring of the overlying cartilage and has a high correlation

with lesion instability, especially when this fluid circles the entire fragment in its circumference (2). Healed lesions do not demonstrate a bright-signal-intensity interface between the fragment and the adjacent bone and do show the return of marrow fat signal intensity in the previously necrotic fragment. The overlying articular cartilage surface is intact without any residual contour irregularities (13). Our case meets the criteria of a healed lesion.

When confronted with a chondral (or osteochondral) lesion in the humeral head, a differential diagnosis must be made between OCD and osteonecrosis of the humeral head. Osteonecrosis of the humeral head is more common as compared to OCD. Aetiologic factors include among others alcohol abuse, steroids and sickle cell anaemia. In the case of osteonecrosis, the joint pain is usually severe. Radiologically osteonecrosis of the humeral head is characterised by a sclerotic subchondral bone segment, possibly followed in a later stage by collapse of the subchondral bone. The absence of any subchondral bone sclerosis on plain films, together with normal signal intensities in the subchondral area on MRI, allows the exclusion of an osteonecrosis in our case.

Classic treatment of OCD of the shoulder includes rest, curettage and drilling of partially detached lesions or removal of loose bodies. No operative treatment was necessary in the case reported.

## REFERENCES

1. **Anderson WJ, Guilford BW.** Osteochondritis dissecans of the humeral head : An unusual cause of shoulder pain. *Clin Orthop* 1983 ; 173 : 166-168.
2. **De Smet AA, Fisher DR, Graf BK, Lange RH.** Osteochondritis dissecans of the knee : Value of MR-imaging in determining lesion stability and the presence of articular cartilage defects. *Am J Roentgenol* 1990 ; 155 : 549-553.
3. **Ganter M, Reichelt A.** Osteochondrosis dissecans of the humeral head. *Z Orthop Ihre Grenzgeb* 1996 ; 134 : 73-75.
4. **Hamada S, Hamada M, Nishiue S, Doi T.** Osteochondritis dissecans of the humeral head. *Arthroscopy* 1992 ; 8 : 132-137.
5. **Isikawa H, Ueba Y, Yonezawa T et al.** Osteochondritis dissecans of the shoulder in a tennis player. *Am J Sports Med* 1988 ; 16 : 547-550.
6. **Itoh K, Ishii S, Usui M et al.** Osteochondritis dissecans of the humeral head. *Katakansetu* 1989 ; 13 : 68-73.
7. **Johnson DL, Warner JP.** Osteochondritis dissecans of the humeral head : Treatment with a matched osteochondral allograft. *J Shoulder Elbow Surg* 1997 ; 6 : 160-163.
8. **Miller RH.** Knee injuries. In : Canale ST (ed). *Campbell's Operative Orthopaedics*. Vol 2. 9<sup>th</sup> Ed. WB Saunders Company Ltd, 1998, pp 1266-1274.
9. **Miller LF, Hilkevitch A.** Osteochondritis dissecans of the shoulder. *Am J Roentgenol* 1950 ; 63 : 223-227.
10. **Petrini A, Grassi G, Zaccaria CP.** Osteochondrite dissecante della testa omerale. *Chir Org Mov* 1984 ; 59 : 83-85.
11. **Pydisetty RV, Prasad SS, Kaye JC.** Osteochondritis dissecans of the humeral head in an amateur boxer. *J Shoulder Elbow Surg* 2002 ; 11 : 630-632.
12. **Salmon MJ.** Ostéochondrite disséquante du coude et de l'épaule. *Bull et Mem Soc Anat de Paris* 1923 ; 93 : 608-612.
13. **Stoller DW.** *Magnetic Resonance Imaging in Orthopaedics and Sports Medicine*. Lippincott-Raven, 1997, pp 415-17.