



Non traumatic dislocation of the patella in children : The case for a dysplastic aetiology

R. W. PATON, W. Y. KIM, A. BONSHAHI

From Blackburn Royal Infirmary, Blackburn, United Kingdom

Congenital dislocation of the patella may be a phenotype, which has several genotypes, i.e. it may be congenital or acquired. This hypothesis is suggested with three illustrative case studies. Risk factors predictive of the development of irreducible dislocation of the patella in infancy are suggested. As there is a spectrum of possible aetiologies, 'late' diagnosis and a number of 'risk' factors but a common pathology, the word 'congenital' is not always appropriate. We suggest 'Developmental dysplasia and dislocation of the patella (DDDP)' is a more appropriate term for this rare condition.

Keywords : patella ; dislocation ; nontraumatic ; children

INTRODUCTION

In 1989, Klisic (8) made the observation that 'Congenital dislocation of the hip (CDH)' was a misleading term as the condition was not always congenital. He suggested the term 'Developmental dysplasia of the hip (DDH)' as the disorder was a spectrum of conditions including dislocation, subluxation and dysplasia, occurring prenatally or postnatally.

In this paper, we have reviewed three case studies, the literature and the anatomy of Congenital Dislocation of the Patella (CDP). We feel that as in DDH the term 'congenital' may be misleading and may not encompass the full spectrum of the condition. The inaccurate and misleading term of "Congenital dislocation of the patella (CDP)"

should be replaced by "Developmental dysplasia and dislocation of the patella (DDDP)".

PATIENTS AND METHODS

A retrospective review was undertaken on three cases of irreducible non traumatic dislocation of the patella presenting through the Paediatric Orthopaedic Clinic at Blackburn Royal Infirmary. All three cases had been examined at birth and patella dislocation was not noted.

Case 1

A five-year-old girl with Down's Syndrome (trisomy 21) presented with a gait disturbance and fixed flexion deformity of 20°, a valgus deformity of 15° and a fixed irreducible dislocation of the patella. Radiographic assessment confirmed a lateral dislocation of the patella (fig 1). At the age of six years, the patella was reduced surgically using a combination of a V-Y plasty

■ R. W. Paton, FRCS (Orth), Consultant orthopaedic surgeon and honorary clinical lecturer.

University of Manchester, United Kingdom.

■ W. Y. Kim MSc, FRCS (Orth), Specialist registrar, orthopaedics and trauma surgery.

■ A. Bonshahi, FRCS, Senior house officer in orthopaedics and trauma surgery.

Blackburn Royal Infirmary, Bolton Road, Blackburn, United Kingdom.

Correspondence : W. Y. Kim, 14 Croftleigh Close, Whitefield, Manchester M45 7DL, United Kingdom.

E-mail : wjykim@hotmail.com.

© 2005, Acta Orthopædica Belgica.

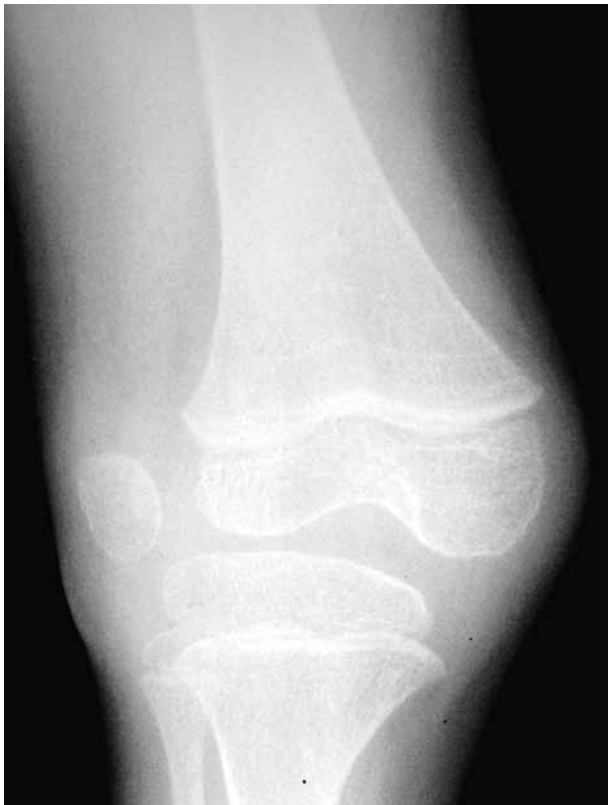

Fig. 1. — Radiograph of right knee of the patient with Down's syndrome confirming lateral dislocation of the patella.

to lengthen the quadriceps mechanism and a modified Langenskiold and Ritsila soft tissue procedure (9). The aetiology of patella dislocation in this case could have been acquired or congenital.

The Langenskiold and Ritsila procedure entails an extensive lateral release, release of the iliotibial band, release of synovial adhesions, detachment of the distal patella tendon, which is reattached more medially through synovium and capsule. The abundant medial retinaculum with part of the vastus medialis is mobilised and attached laterally as a rotation flap.

Case 2

A 4-year-old girl with Mulibrey Nanism Syndrome, who had previously been successfully surgically treated at the age of 11 months for a left congenital vertical talus, presented with an increasing fixed flexion (15°), a valgus deformity of the left knee and an irreducible dislocation of the patella. Radiographs and CT scan (fig 2) confirmed a laterally dislocated patella. At the age of

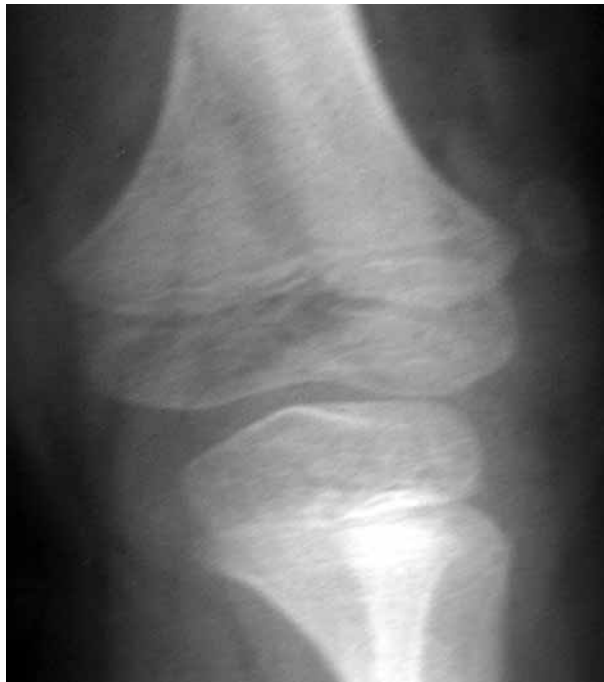

Fig. 2. — Radiograph of left knee of patient with Mulibrey Nanism syndrome with a dislocated left patella. Marked soft tissue contractures resulted in the external tibial torsion deformity seen in this true AP radiograph.

5 years, the patella was reduced surgically with the procedure described above. No V-Y plasty of the quadriceps was required. The aetiology of dislocated patella in this case was probably congenital.

This rare syndrome is an autosomal recessive condition characterised by growth failure, triangular facies and muscle hypotonia, liver and brain involvement. The child has normal intelligence. The association of this condition with irreducible dislocation of the patella has not been previously described.

Case 3

A 6-year-old boy with a severe learning difficulty, epilepsy and muscle hypotonia presented with bilateral dislocation of the patella. The left side was reducible in extension but the right patella dislocation was irreducible (fig 3). At eight years of age, he underwent bilateral proximal and distal realignment procedures: lateral release, medial plication and Goldthwaite-Roux procedures. The left side reduced fully but the right side continued to sublux at surgery. Despite the surgery, the right knee later developed an irreducible dislocation of the

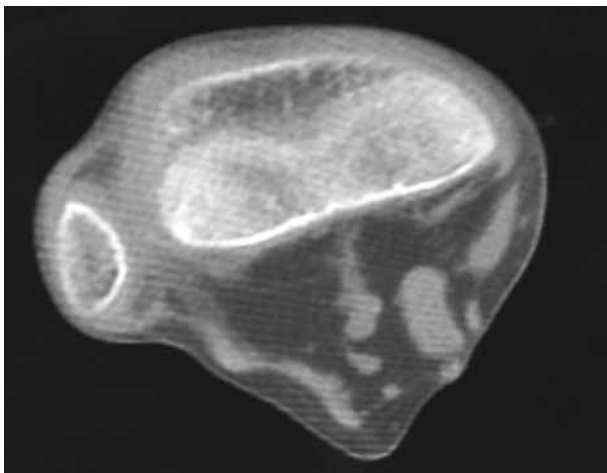


Fig. 3. — CT-scan of the right knee in the patient with severe learning difficulties confirming lateral dislocation of the patella.

patella progressing to a 30° fixed flexion and a 20° valgus deformity of the knee. At the age of 11, he underwent the modified Langenskiöld and Ritsila procedure, which successfully corrected the right irreducible patella dislocation. The aetiology of dislocation in this case was probably acquired.

DISCUSSION

Congenital dislocation of the patella (CDP) is a rare condition, the aetiology of which is not fully understood. Stanisavljevic *et al* (15) suggested that during intrauterine development, the myotome containing the quadriceps muscle failed to rotate internally. This displaces the quadriceps mechanism anterolaterally resulting in a laterally dislocated patella.

Ghanem *et al* (4) and Gao *et al* (3) described the pathologic anatomy. The patella was underdeveloped, dislocated superiorly and posteriorly with reference to the trochlea; it was fixed laterally at the level of the lateral condyle. The patella was flat and its articular cartilage was thin. The iliotibial band was thickened and tubular, the quadriceps was short and malformed, the vastus lateralis being adherent to the iliotibial band and tensor fasciae latae. The vastus medialis was thinner and stretched. The patellar tendon was inserted more laterally.

In the three case histories described, the anatomical abnormalities at clinical presentation were similar: a fixed dislocation of a hypoplastic patella, an underdeveloped trochlea, contractures of the soft tissues (quadriceps, iliotibial band), lateral attachment of the patellar tendon and stretching of the medial structures. Acquired or congenital aetiologies were possible, thus suggesting a spectrum of disease.

Several authors consider congenital and acquired irreducible dislocation of the patella as different entities (5, 13). However, Jones *et al* proposed a link between congenital, irreducible and habitual dislocation of the patella (7). Similarly, Bensahel *et al* (1) reviewed 102 unstable patellae in children and divided them according to whether there was a traumatic dislocation, recurrent dislocation or malformative instability. Radiographs and magnetic resonance imaging were performed. Two types were described: Type 1 was observed in children with joint laxity with no major radiological anomalies and Type 2 was observed in children where various degrees of femoropatellar dysplasia were demonstrated. The authors concluded that a spectrum of the patellar instability exists.

The irreducible patella in childhood may be analogous with that of 'late' dislocation of the hip as the condition may be teratogenic or acquired postnatally. The dysplasia of the patella and trochlea is similar to dysplasia of the acetabulum and femoral head in hip dysplasia. Satisfactory development of the patella and trochlea following surgical correction may be in response to a normally functioning quadriceps mechanism (6). This is also analogous with the remodelling and development of the acetabulum following successful surgery for irreducible dislocation of the hip.

The dislocated patella is rarely diagnosed at birth. Early diagnosis is difficult as radiographic analysis is unreliable because the patella does not ossify before 3-5 years of age and, if dislocated, it may ossify later. Diagnosis of the condition usually occurs in infancy with the diagnosis being made at an average of 7 years 9 months in the series of Gordon and Schoenecker (6). This could raise the suggestion that the diagnosis was 'missed' at birth with the obvious medico-legal implications such a statement raises.

Table I. — Risk factors in the development of infantile irreducible dislocation of the patella

'True' congenital	'Acquired'
Muscular contractures	Muscle hypotonia
Fixed flexion deformity	Ligamentous laxity
Fixed valgus deformity	Muscular imbalance
Hypoplastic patella	Hypoplastic patella
Hypoplastic femoral trochlea	Hypoplastic femoral trochlea
eg arthrogryposis,	eg learning difficulties
Larsen's syndrome,	Trisomy 21,
congenital syndromes	cerebral palsy

Irreducible dislocation of the patella has been reported in arthrogryposis, Larsen syndrome (10), Down's syndrome (9, 11), nail patella syndrome (12), Rubinstein-Taybi Syndrome (14) and congenital vertical talus (5).

Dislocation of the patella is a phenotype, which clearly has several genotypes: congenital and acquired. Stanisavljevic *et al* (15) defined congenital dislocation as 'a lateral dislocation present at birth, diagnosed before the age of 10 years and irreducible by closed means'. This is a rather vague definition. As most irreducible dislocations are diagnosed in infancy, it is impossible to differentiate between a congenital or acquired aetiology in the majority of cases.

The hypoplastic patella and trochlea would suggest that even in probable 'acquired' dislocations such as in cerebral palsy, severe hypotonia or learning difficulties there is a pre-existing dysplasia which puts the patella 'at risk' of dislocation (table I).

The 'true' congenital dislocations of the patella may be those with multiple congenital abnormalities of the joints such as arthrogryposis, congenital vertical talus or Larsen's syndrome (2). These conditions tend to have thickened, shortened fibrous soft tissues affecting other joints apart from the knee, present at birth. These soft tissue abnormalities may possibly be more important than the hypoplastic trochlea and patella in the aetiology of the patella dislocation in these cases.

As there is a spectrum of aetiologies, 'late' diagnosis, a number of 'risk' factors but a common

pathology namely soft tissue contractures and joint hypoplasia/ dysplasia the word congenital is probably not appropriate. We would suggest 'Developmental dysplasia and dislocation of the patella (DDDP)' is a more appropriate term for this disorder.

REFERENCES

1. **Bensahel H, Souchet P, Pennecot GF, Mazda K.** The unstable patella in children. *J Pediatr Orthop* 2000 ; 9-B : 265-270.
2. **Eilert RE.** Congenital dislocation of the patella. *Clin Orthop* 2001 ; 389 : 22-29.
3. **Gao GX, Lee EH, Bose K.** Surgical management of congenital and habitual dislocation of the patella. *J Pediatr Orthop* 1990 ; 10 : 255-260.
4. **Ghanem I, Wattincourt L, Seringe R.** Congenital dislocation of the patella. Part I : pathologic anatomy. *J Pediatr Orthop* 2000 ; 20 : 812-816.
5. **Ghanem I, Wattincourt L, Seringe R.** Congenital dislocation of the patella. Part II : orthopaedic management. *J Pediatr Orthop* 2000 ; 20 : 817-822.
6. **Gordon JE, Schoenecker PL.** Surgical treatment of congenital dislocation of the patella. *J Pediatr Orthop* 1999 ; 19 : 260-264.
7. **Jones RD, Fisher R, Curtis B.** Congenital dislocation of the patella. *Clin Orthop* 1976 ; 119 : 177-183.
8. **Kliscic PJ.** Congenital dislocation of the hip- a misleading term : Brief report. *J Bone Joint Surg* 1989 ; 71-B : 136.
9. **Langenskiold A, Ritsila V.** Congenital dislocation of the patella and its operative treatment. *J Pediatr Orthop* 1992 ; 12 : 315-323.
10. **Laville JM.** Knee deformities in Larsen's syndrome. *J Pediatr Orthop* 1994 ; 3 : 180-184.
11. **Livingstone B, Hirst P.** Orthopaedic disorders in school children with Down's syndrome with special reference to the incidence of joint laxity. *Clin Orthop* 1986 ; 207 : 74-76.
12. **Marumo K, Fujii K, Tanaka et al.** Surgical management of congenital permanent dislocation in nail patella syndrome by Stanisavljevic procedure. *J Orthop Sci* 1999 ; 4 : 446-449.
13. **McCall RE, Lessenberry HB.** Bilateral congenital dislocation of the patella. *J Pediatr Orthop* 1987 ; 7 : 100-102.
14. **Mehlman Ct, Rubinstein JH, Roy DR.** Instability of the patellofemoral joint in Rubinstein-Taybi syndrome. *Pediatr Orthop* 1998 ; 18 : 508-511.
15. **Stanisavljevic S, Zemenick G, Miller D.** Congenital, irreducible permanent lateral dislocation of the patella. *Clin Orthop* 1976 ; 116 : 190-199.